

MYCOTIC ANEURYSM OF THE SUPRARENAL AORTA, CELIAC TRUNK AND SUPERIOR MESENTERIC ARTERY. CASE STUDY

Sultanaliyev T.A.¹, Konyssov M.N.², Suleimenov S.S.¹, Madeshov E.K.², Sagandykov I.N.¹, Konyssova S.A.², Sukhareva T.V.³, Morozov K.M.⁴, Larin S.V.⁵, Kolesnik D.I.⁶, Sharifova B.K.²

¹National scientific oncology center, Astana, Kazakhstan.,

²Atyrau regional cardiology center, Atyrau, Kazakhstan,

³Korolev city hospital, Korolev, Moscow region, Russian Federation,

⁴MMC-clinic Moscow, Russian Federation,

⁵Pirogov Russian National research medical university, Moscow, Russian Federation,

⁶Central clinical hospital of the Federal customs service, Moscow, Russian Federation

Abstract

The article presents a rather rare clinical observation and literature review of surgical interference for mycotic (infectious) aneurysm of the suprarenal aorta with damage to paired and unpaired branches (celiac trunk, superior mesenteric and renal arteries). The authors note the features of the clinical course of aortic lesions (chronic ischemia of the digestive system, cardiorenal hypertension), the mechanisms of the disease development, and indicate the need for open repair of the thoracoabdominal aorta.

Қолқаның супраренальды бөлігінің, целиак діңінің және жоғарғы шажырқай артериясының микотикалық аневризмасы. Клиникалық бақылау

Султаналиев Т.А.¹, Коньсов М.Н.², Сулейменов С.С.¹, Мадешов Е.К.², Сагандықов И.Н.¹, Коньсова С.А.², Сухарева Т.В.³, Морозов К.М.⁴, Ларин С.В.⁵, Колесник Д.И.⁶, Шарифова Б.К.²

¹Ұлттық ғылыми онкология орталығы, Астана қ., Қазақстан,

²Атырау облыстық кардиологиялық орталығы, Атырау қ., Қазақстан,

³Королев қалалық ауруханасы, Королев қ., Мәскеу облысы, Ресей Федерациясы,

⁴ММС-клиникасы, Мәскеу қ., Ресей Федерациясы,

⁵Н.И. Пирогов атындағы Ресей Ұлттық ғылыми медициналық университеті, Мәскеу қ., Ресей Федерациясы,

⁶Федералдық кеден қызметінің орталық клиникалық госпиталі, Мәскеу қ., Ресей Федерациясы

Тұжырым

Мақалада сирек кездесетін клиникалық бақылау, жұптасқан және жұпталмаған бұтақтардың (целиакия діңі, жоғарғы шажырқай және бүйрек артериялары) қатысуымен қолқаның супраренальды бөлігінің микотикалық (инфекциялық) аневризмасына хирургиялық араласудың әдеби шолуы келтірілген. Авторлар аорта зақымдануының клиникалық ағымының

<https://doi.org/10.35805/BSK202311002>

Sultanaliyev T.A.

orcid.org/ 0000-0003-1732-9489

Konyssov M.N.

orcid.org/0000-0002-7848-4231

Suleimenov S.S.

orcid.org/ 0000-0002-4103-4130

Madeshov E.K.

orcid.org/ 0009-0003-4733-3929

Sagandykov I.N.

orcid.org/ 0000-0002-9597-198X

Konyssova S.A.

orcid.org/ 0009-0003-9077-2425

Sukhareva T.V.

orcid.org/0000-0002-0073-160X

Morozov K.M.

orcid.org/0000-0002-4167-5261

Larin S.V.

orcid.org/ 0009-0003-0454-2528

Kolesnik D.I.

orcid.org/ 0000-0001-9531-3410

Sharifova B.K.

orcid.org/ 0009-0002-6505-6972

Author for correspondence:

Konyssov M.N. – Dr. Med.

Sc., director, Atyrau Regional

Cardiology Center,

Atyrau, Kazakhstan,

e-mail: mconus@mail.ru

Conflict of interest:

The authors declare that they have no conflicts of interest

Keywords:

mycotic aneurysm,

visceral branches

Хат алысатын автор:

Коньсов М.Н. – м.ғ.д.,

директор, Атырау облыстық

кардиологиялық орталық,

Атырау қ., Қазақстан,

e-mail: mconus@mail.ru

Мүдделер қақтығысы:

Авторлар мүдделер

қақтығысының жоқтығын

мәлімдейді

Түйінді сөздер:

микотикалық аневризма,

висцеральды тармақтар

ерекшеліктерін (ас қорыту жүйесінің созылмалы ишемиясы, вазоренальды гипертензия), аурудың даму механизмдерін атап өтеді және қолқаның торакоабдоминальды бөлігін ашық қалпына келтіру қажеттілігін көрсетеді.

Микотическая аневризма супраренального отдела аорты, чревного ствола и верхней брыжеечной артерии. Клиническое наблюдение

Автор для корреспонденции:
Коньсов М.Н. – д.м.н., директор,
Атырауский областной
кардиологический центр, г.
Атырау, Казахстан,
e-mail: mconus@mail.ru

Султаналиев Т.А.¹, Коньсов М.Н.², Сулейменов С.С.¹, Мадешов Е.К.²,
Сагандыков И.Н.¹, Коньсова С.А.², Сухарева Т.В.³, Морозов К.М.⁴,
Ларин С.В.⁵, Колесник Д.И.⁶, Шарифова Б.К.²

Конфликт интересов:
Авторы заявляют об отсутствии
конфликта интересов

Ключевые слова:
микотическая аневризма,
висцеральные ветви

¹Национальный научный онкологический центр, г. Астана, Казахстан,
²Атырауский областной кардиологический центр,
г. Атырау, Казахстан,
³Королевская городская больница, г. Королев, Московская область,
Российская Федерация,
⁴ММС-клиник г. Москва, Российская Федерация,
⁵Российский Национальный исследовательский медицинский
университет им. Н.И. Пирогова, г. Москва, Российская Федерация,
⁶Центральный клинический госпиталь Федеральной таможенной
службы, г. Москва Российская Федерация

Аннотация

В статье представлено достаточно редкое клиническое наблюдение и литературный обзор оперативного вмешательства по поводу микотической (инфекционной) аневризмы супраренальной части аорты с поражением парных и непарных ветвей (чревный ствол, верхняя брыжеечная и почечная артерии). Авторы отмечают особенности клинического течения поражения аорты (хроническая ишемия органов пищеварения, вазоренальная гипертензия), механизмы развития заболевания и указывают на необходимость открытой реконструкции торакоабдоминальной части аорты.

Relevance

Numerous publications and whole chapters in monographs are devoted to aortic aneurysms and main arteries. Aneurysms are often referred to as "time bombs" because the patient is constantly under the threat of rupture and development of complications, up to a fatal outcome. The frequency of aneurysms of different localization is different. So, at present, the frequency of abdominal aortic aneurysms (AAA) in the Russian Federation is 10-40 cases per 100,000 population, in the USA - 36.2. It has been noted that over the past 20 years, the prevalence of AAA has decreased [1, 2]. According to pathoanatomical data, aneurysms are detected in 0.16–1% of all autopsies, i.e., the disease was not recognized in-life [3]. The true prevalence of aneurysms of the splanchnic arteries remains unclear due to the asymptomatic course. It is generally accepted that it does not exceed 0.1–2% [4, 5]. Most often, among the aneurysms of this localization, there are aneurysms of the

splenic artery - 60-70%, less often of the hepatic artery - about 20%. Aneurysms of the celiac trunk (CT) and mesenteric arteries (MA) total about 10%. According to various data, the prevalence of aneurysms of the superior mesenteric artery (SMA) is 3.2-8% in the structure of aneurysms of the splanchnic arteries [6, 7]. The incidence of SMA aneurysms is no more than one in 12,000-19,000 autopsies.

The increase in the detection rate of SMA aneurysms in recent years is due to the widespread use of instrumental examination techniques in patients with nonspecific abdominal complaints: ultrasound (US) diagnostic methods, computed tomography, magnetic resonance imaging (MRI) [8]. Also, the growth in the number of aneurysms is facilitated by the development of methods for invasive diagnostics and treatment, which leads to the development of iatrogenic pseudoaneurysms [9, 10]. A somewhat independent group consists of aneurysms of the extracranial branches of

the aortic arch, which are less common than aneurysms of other localizations. More often, aneurysms of such localization have a traumatic etiology, while the frequency of true aneurysms of the arteria carotis, according to various sources, ranges from 0.4 to 4% of all aneurysms of peripheral arteries, surgeries for which in practice are performed only in 0.1-2% of cases [11, 12]. We have encountered a dissecting aneurysm of the common carotid artery (CCA) with the transition of the dissection to the internal carotid artery with its subsequent thrombosis [13]. The most common are atherosclerotic aneurysms, while mycotic aneurysms are a fairly rare lesion of the aorta and main arteries. According to statistics in Europe, the total number of mycotic aneurysms is 0.65% to 2%. It is believed that the first description of a septic aneurysm belongs to Osler W., who in 1885 presented a clinical observation of a 30-year-old patient with malignant endocarditis who died from rupture of the aortic arch. Autopsy revealed 4 "mushroom-shaped protrusions" on the aortic arch, which the author called "mycotic aneurysms" [14].

The term "mycotic aneurysm", introduced by Osler W, is still used today. It should be noted that the author had in mind only a morphological feature - a "mushroom-like" type of aneurysm, but not an etiological factor. In fact, 93% of these aneurysms have a sac-like structure on imaging [14]. The actual mycotic lesion as an infectious agent that causes destruction of the vascular wall is very rarely described in the literature. The most common pathological microorganisms are Salmonella (predominant in Asia) and Staphylococcus aureus (predominant in European and North American patient populations), which account for about 40% of lesions [15]. According to Hsu R.B. et al. (2005), systemic Salmonella infection causes damage to the vascular wall in 16.2–19.8% of patients [16].

The pathogenesis of arterial infectious lesions obviously suggests the presence of a primary intimal lesion. Therefore, atherosclerosis is the most important predictor of mycotic aneurysms. It is possible that such difficult-to-diagnose lesions as a penetrating aortic ulcer and intramural hematoma may also become the focus of a primary infectious lesion. Cases of secondary infection of pre-existing aneurysms have been described. Fourneau L., et al. (1996) of 176 patients with a clinically unsuspected infected abdominal aortic aneurysm, 14.2% were cultured from the aneurysm wall. However, the authors did not note any influence on the frequency of prosthesis infection in the long-term period [17].

The increase in the number of patients with mycotic aneurysms in the second half of the 20th century is explained by the increase in the number

of people infected with immunodeficiency (primarily HIV-infected and intravenous drug users). Bacterial endocarditis as a risk factor at the end of the 20th century was detected in 17% of patients [18]. Localization of aortic lesions: ascending aorta and arch – 6%, thoracic aorta – 42%, visceral aorta – 13%, infrarenal – 32% [19].

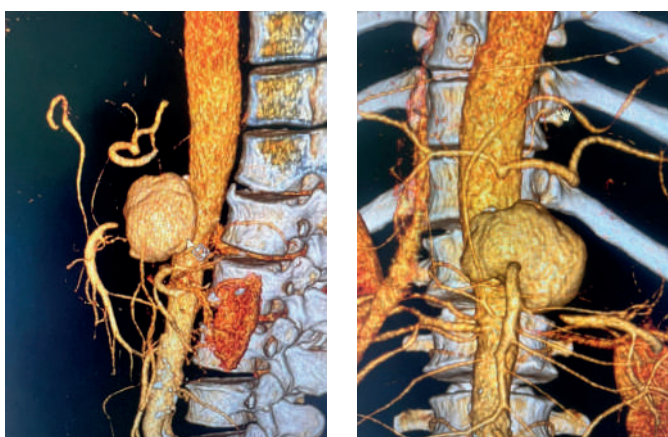
There is currently no international consensus on the optimum treatment of mycotic (infected) aneurysms. The Russian national guidelines only state the need for surgical treatment and recommend tactics similar to the treatment of aortoenteric fistulas. We have also observed this complication recently. At the same time, the prospect of endovascular treatment is evaluated with caution. The North American guidelines (2018), as well as the recommendations of the European Society of Cardiology for the treatment of aortic diseases (2014) and the Russian guidelines for the diagnosis and treatment of aortic diseases (2017), "bypass" these types of aneurysms [20, 21, 22].

We came across an interesting case that fully confirms the above assumption, a combination of atherosclerotic lesions of the aorta with the formation of a combined atherosclerotic and mycotic aortic aneurysm, TC and SMA. We devoted our publication to the analysis of this observation.

Patient G., aged 52 (Medical history sheet No. 4161). Was admitted to the Department of Vascular Surgery of the Atyrau Regional Cardiology Center of the Health Department of the Atyrau Region in a planned manner on December 19, 2022.

Complaints at admission to pain in the left side of the abdomen, stool retention and poor passage of flatus, periodic chills, weakness. According to the patient, he fell ill acutely about 18 days ago, when pains suddenly appeared in the left side of the abdomen and there was a general weakness. He associates his disease with a sudden increase in blood pressure to 230/120 mm Hg (obvious vasorenal genesis of hypertension). There were no injuries. In blood tests, there was an increase in the level of procalcitonin, leukocytosis and an increase in C-reactive protein (CRP). CT scan of the abdominal organs with contrast (before admission to our clinic) dated November 28, 2022: Conclusion: CT signs of a penetrating ulcer of the anterior wall of the suprarenal abdominal aorta with the formation of a saccular aneurysm, with moderate para-aortic infiltration, and edema of the aortic walls. Occlusion at the mouth of the celiac trunk and superior mesenteric artery. Hepatomegaly. Diffuse changes in the liver parenchyma, chronic calculous cholecystitis, chronic pancreatitis. Adenoma of the left adrenal gland. Figure 1 a, b.

Figure 1.
a, b. MSCT 3D reconstruction
(volumetric rendering mode,
arterial phase)



He was referred to our hospital after consulting a vascular surgeon with a diagnosis of atherosclerosis. Aneurysm of the supraceliac abdominal aorta with a penetrating ulcer of the anterior wall without rupture and dissection, subacute course. Syndrome of chronic ischemia of the digestive system (CIDS). Occlusion at the mouth of the celiac trunk and superior mesenteric artery.

Epidemiological anamnesis: denies infectious hepatitis, sexually transmitted diseases, malaria, typhoid and tuberculosis. Over the past six months, the blood was not transfused, has not been under the treatment with the dentist, injections were not made. Bad habits: denies. Allergies to drugs and food are not noted. On regular medical check-up with a cardiologist with a diagnosis of arterial hypertension of the III-degree, risk 4. Surgery: appendectomy in 1986.

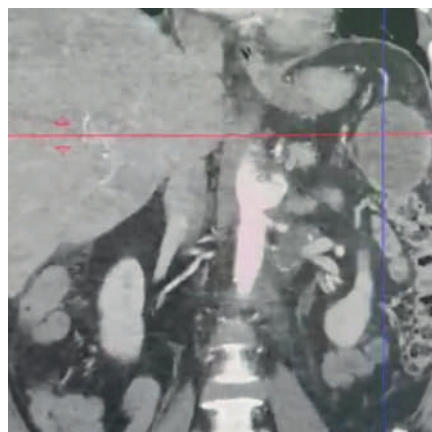
Objective data at admission: overall health status of medium severity, due to the underlying disease. Normosthenic body build, supernutrition. Vesicular breathing in the lungs, there were no crackles. Respiration rate - 17 in min. Heart tones are muffled, rhythmic. Arterial pressure - 190/120 mm Hg, pulse 112 per minute, rhythmic. The moist tongue. The abdomen is symmetrical, not swollen. On palpation, the abdomen is soft and painless. There are no peritoneal signs. The liver at the edge of the costal arch, painless. The spleen is not non-palpable. Intestinal peristalsis is auscultated. The kidney punch is negative on both sides. The unimpeded urination, painless. The gases are released. According to

the words, the stool was formed after taking laxatives.

Status localis: Symptoms of Homans, Moses is negative. The pulsation of the arteries in the upper and lower extremities is determined throughout. There are no noise symptoms on auscultation over the main arteries.

CT scan of the chest dated 12.11.2022: CT signs of chronic bronchitis. Pulmonary fibrosis of S5, S6, S8, S9 and S10 segments of the right lung and S5 and S8 segments of the left lung. Fibrogastroduodenoscopy dated 22.11.2022: Conclusion: Erosive antral gastritis. Video colonoscopy dated 18.18.2022: Conclusion: Mixed hemorrhoids. CT scan of the abdominal cavity organs dated 12.11.2022: In addition to the above data. Hyperplasia of both adrenal glands. Formation of (cyst?) and a single parapelvic cyst of the left kidney. Moderate calicopyeloectasia of both kidneys. Circular thickening of the walls of the sigmoid and rectum. Dolichosigmoid. Atherosclerosis of the abdominal aorta and iliac arteries. Hernia of the anterior abdominal wall. MRI of the abdominal cavity organs and retroperitoneal space with contrast, dated November 29, 2022: Conclusion: MRI shows signs of a penetrating ulcer of the anterior wall of the supraceliac abdominal aorta with the formation of a saccular aneurysm, with moderate para-aortic infiltration, and edema of the aortic walls. Occlusion at the mouth of the celiac trunk and superior mesenteric artery. Hepatomegaly. Diffuse changes in the liver parenchyma, chronic calculous cholecystitis, chronic pancreatitis. Adenoma of the left adrenal gland. Figure 2, 3, 4.

Figure 2.
Frontal view



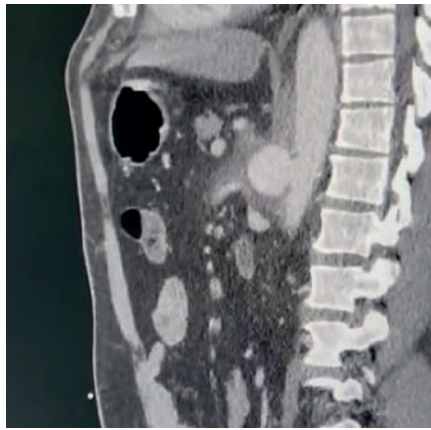
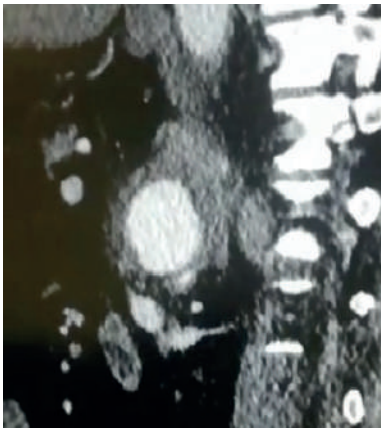

Figure 3,4.
Lateral view

In the lateral view, especially when magnified, it is clear that the aorta and the aneurysm itself are, as it were, wrapped in a "cloak" of altered tissues. Apparently, these are the consequences of an infected hematoma formed as a result of a defect in the aortic wall.

Aortography dated 02.12.2022: Conclusion: In the suprarenal abdominal aorta, a saccular aneurysm measuring 40 mm x 35 mm with smooth round edges is contrasted. Figure 5.

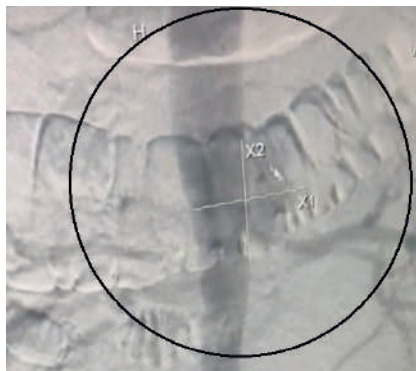

Figure 5.
Radiopaque aortography

With hypertension, it is seen that all lumbar arteries are contrasted, i.e. there are no thrombotic overlays, which is typical for atherosclerotic aortic aneurysms.

EchoCG dated 29.11.2022: Conclusion: EF-54%. The study was conducted against the background of tachycardia, slight dilatation of the LA. Relative mitral insufficiency 0-1 degree. Concentric (moderate) hypertrophy of the left ventricle. Systolic function of the left ventricle is satisfactory. Diastolic dysfunction of the left ventricle type 1. Ultrasonography of the BCT dated 01.12.2022: Conclusion: Atherosclerosis of the BCA.

Stenosis in CMPR of both CCA is 35-40%. Small diameter of the vertebral artery on the left. Non-rectilinear course of the vertebral arteries in the CV. Ultrasonography of the kidneys dated 01.12.2022: Conclusion: The abdominal aorta and renal arteries are patent. Hemodynamic abnormalities were not revealed.

Ultrasound of the aorta, renal and visceral arteries dated December 1, 2022: Conclusion: Atherosclerosis. Saccular aneurysm of the suprarenal abdominal aorta (d-45 mm, length 5 cm). Figure 6 a, b, c, d

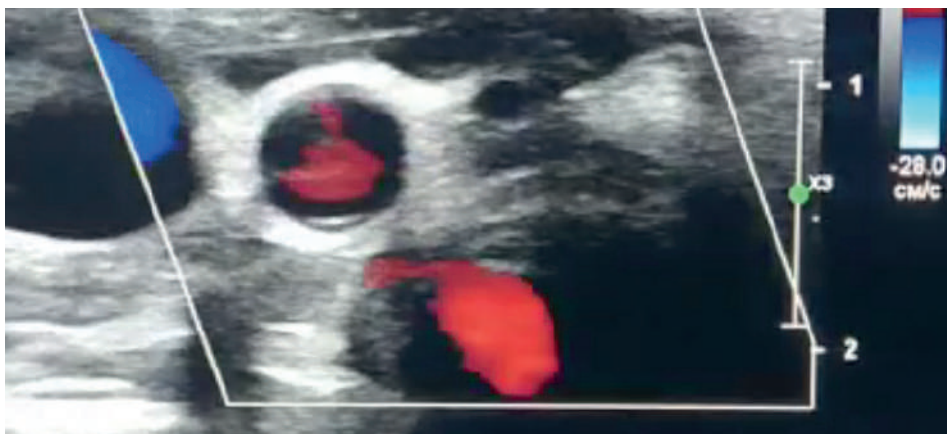


Figure 6. a

Figure 6. b

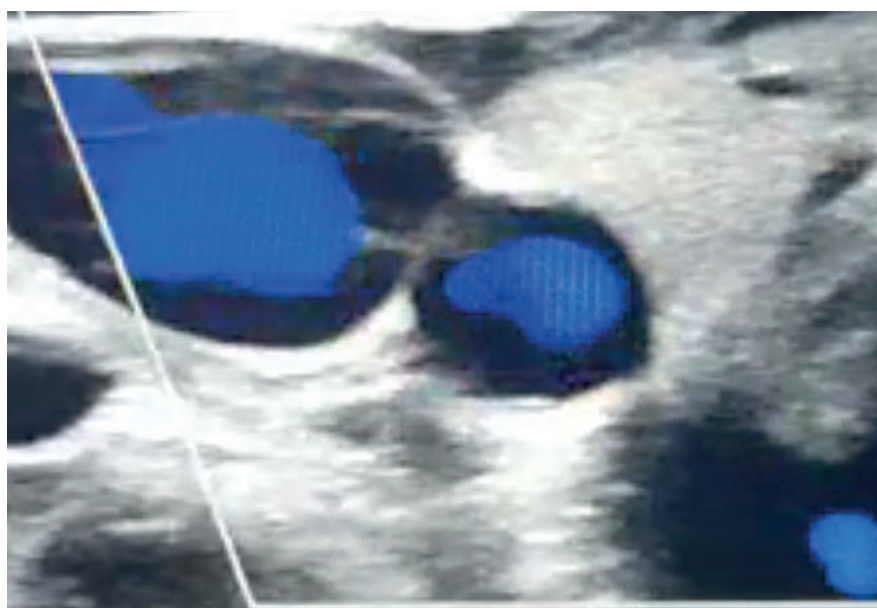


Figure 6. c

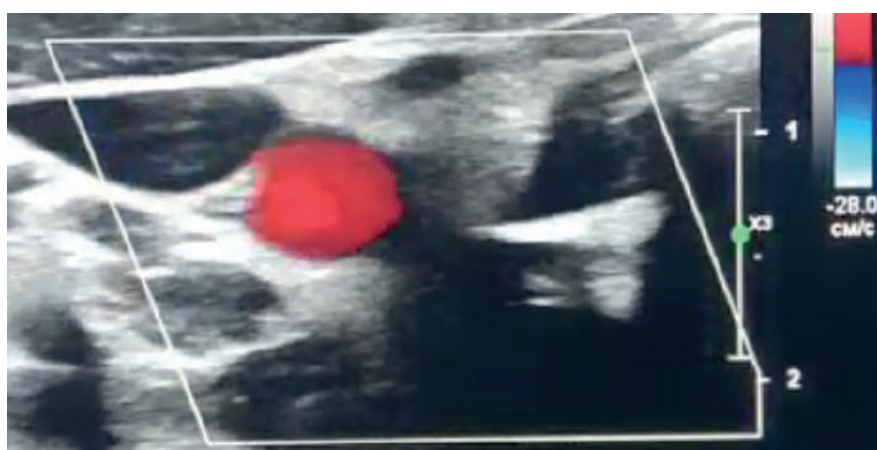
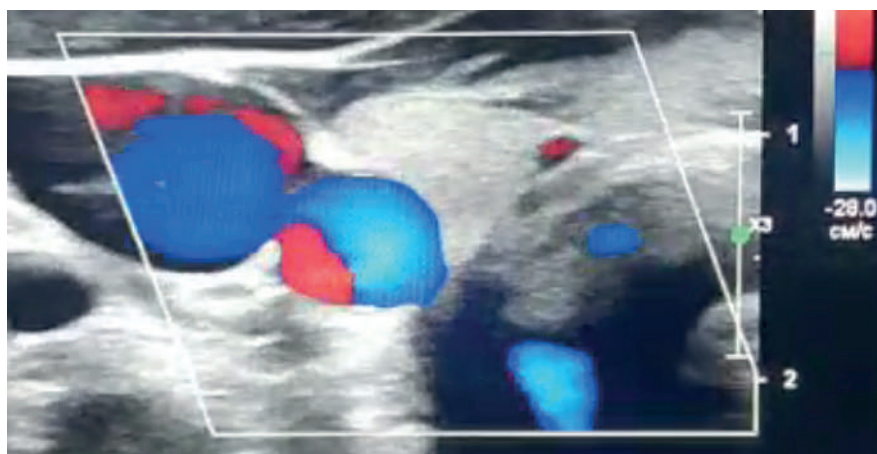


Figure 6. d



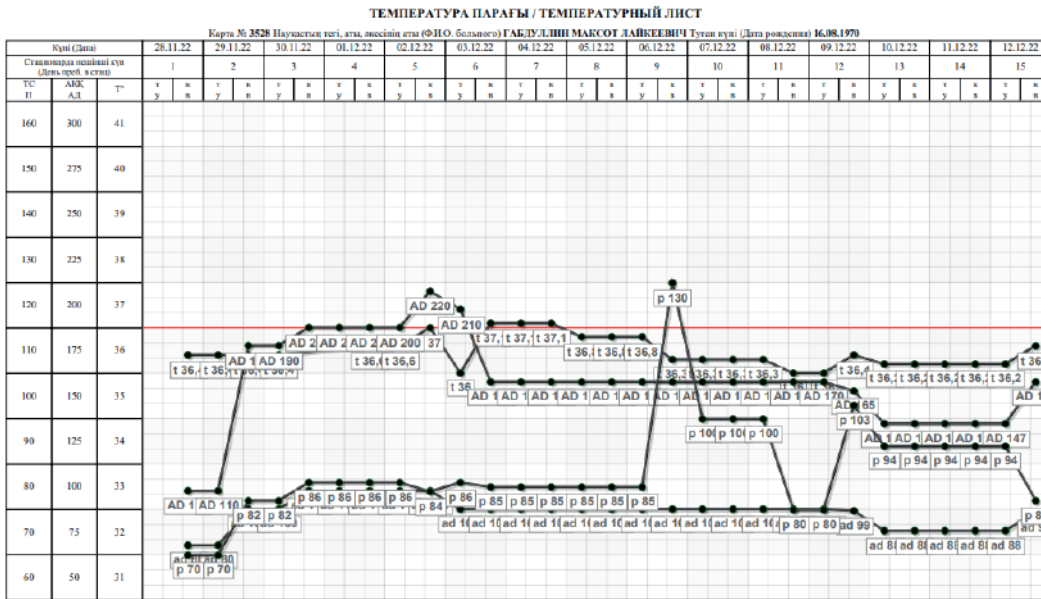
A series of sonograms shows that initially there is no defect in the aortic wall (Figure 6 a), and in Figure 6 b, the minimum blood flow appears only in systole. When the aortic wall is stretched, the shunt increases.

In order to prepare for the surgery, all

consultations of specialists were carried out: a cardiologist, an endocrinologist

Unlike other authors [23], we did not observe any clinically significant temperature fluctuations during the entire period of observation of the patient. What is shown in Figure 7.

Figure 7. Medical card

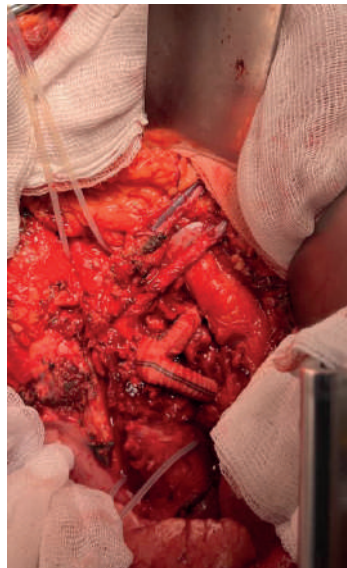


After additional examination and preparation on 20.12.21, the surgery was performed - Left-sided thoracophrenolombotomy, subdiaphragmatic splanchnicoganglionectomy. Resection of an aneurysm of the celiac trunk and superior mesenteric artery with bifurcation alloprosthesis of the celiac trunk and superior mesenteric artery (Prosthesis Polymaille C 16x8x8 mm). Decompression of the left renal artery. Drainage of the pleural cavity and retroperitoneal space.

Surgical report: Under general endotracheal anesthesia after treatment of the surgical area with a solution of betadine, a layer-by-layer incision along the 9th intercostal space on the left with dissection of the costal arch and pararectally to the navel, thoracophrenolombotomy was performed. The diaphragm is crossed at the base with the intersection of the medial crura. The abdominal muscles were crossed pararectally with the release of the retroperitoneal space with the separation of the peritoneum and the left kidney medially. The aorta was mobilized in the descending section, the abdominal aorta to the bifurcation. Subphrenic splanchnicoganglionectomy. During the revision, there is a saccular aneurysm of the celiac trunk and superior mesenteric artery along the anterior surface of the suprarenal section with a diameter of up to 5.0 cm, pulsating. Non-productive hemostasis. There is no fluid in the pleural cavity on the left. The lungs are pale pink. The thoracic aorta was isolated above the diaphragm and aneurysm with dissection of the para-aortic tissue, d-22 mm, taken on a holder. The abdominal aorta was mobilized below the aneurysm between the outlets of the superior mesenteric artery and the renal arteries, d-18 cm, taken on a holder. The lumbar branches were taken on capron - 3.0. In view of the periproces and a pronounced adhesive process, the aneurysmal sac was mobilized along all walls with technical difficulties. The celiac trunk and bifurcations were mobilized, the superior mesenteric artery within healthy tissues, d-8 mm. The left renal artery and vein are mobilized to

the opening, not dilated d- 8 mm, compressed at the opening by an aneurysmal sac (LVA decompression). The aorta above and below the aneurysm was taken with aortic clamps. Opened aneurysm. The lumen of the aneurysm is free. The revision revealed an aneurysm of the celiac trunk and superior mesenteric artery. There was a resection of the aneurysmal sac at the neck. It was decided to perform alloprosthetics of the celiac trunk and superior mesenteric artery with Polymaille alloprosthesis (16x8x8 cm). There was an imposition of the anastomosis between the aorta and the prosthesis type end of the prosthesis on the side of the aorta continuous suture Prolene 3.0. Embolism prevention. Gradually removed the clamp from the aorta. The seam line is hermetic. Aortic clamping time is 30 min. A clamp is placed on the prosthesis. Intraoperatively, autohemotransfusion using the Sorin Xtra apparatus was used, 350 ml of blood poured into the wound was transfused. Vascular clamps were placed on the celiac trunk. An arteriotomy 1.5 cm long was made, a thrombus in the lumen, 1.0 cm in size, was removed. A good counterpulsation was obtained. The anastomosis of the upper branch of the prosthesis with the celiac trunk was made end-to-side with a continuous suture with Prolene 6.0. Embolism prevention. Clamps were removed. The anastomosis line is hermetic. Vascular clamps on the superior mesenteric artery were imposed. An arteriotomy 1.5 cm long was made, the bright lumen. A good counterpulsation was obtained. An anastomosis was made between the lower branch of the prosthesis with the superior mesenteric artery end-to-side with a continuous suture with Prolene 6.0. Embolism prevention. Clamps were removed. The anastomosis line is hermetic. Hemostasis. Non-productive. The separation of drainage into the pleural cavity and retroperitoneal space. The diaphragm is sutured with a continuous stitch with Mercil No.1. The ribs and costal arch are connected X-shaped with nylon 5.0. Layered wound closure. Type of surgery in Figure 8.

Figure 8.
Aortogastric and superior mesenteric prosthetics.
General view of the completed reconstruction



Histological examination of biopsy material of the 2nd category of complexity (No. 15768-70), the number of pieces is 3, stained with hematoxylin-eosin. The sectioned slide is represented by the growth of connective tissue with hemorrhages and full-blooded vessels. Pathological and histological conclusion: In the preparation, the material is represented by the growth of fibrous tissue among adipose tissue and inflammatory infiltration and purulent- fibrinous pellicle, the vessels are dilated in the lumen of the stasis of erythrocytes.

The bacteriologic examination: the growth of pathogenic flora was not detected. Sensitivity to antibiotics dated 22.12.2022: Staphylococcus saprophyticus - 105 (Azithromycin /S/, Cefotaxime /R/, Cefazolin /R/, Levofloxacin /S/, Cefaclor /R/, Ciprofloxacin /S/).

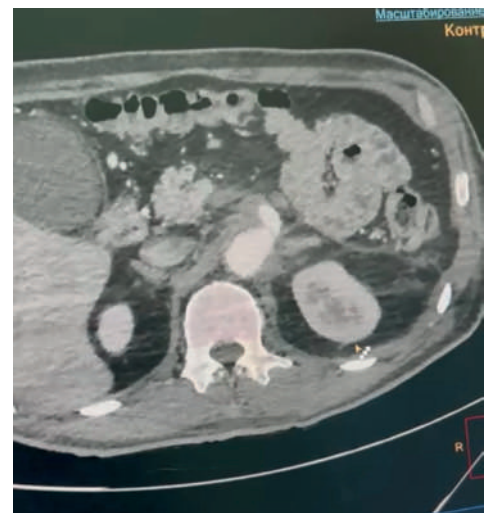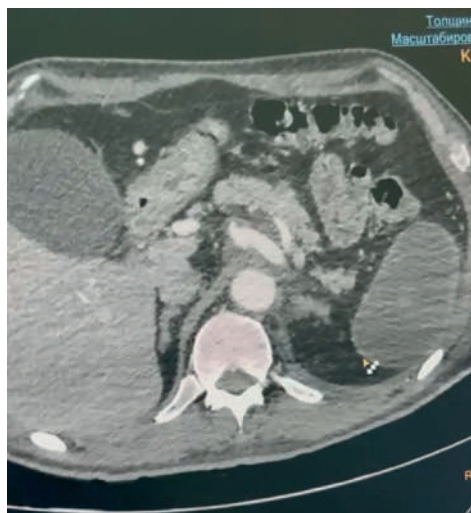
In the post-surgical period, the phenomena of acute renal failure in the stage of polyuria were observed, treatment was carried out by a nephrologist. There is no edema. Natural urination, the volume of excreted urine is 5800.0 ml. Creatinine is 484 $\mu\text{mol/l}$. Urea is 20.5 $\mu\text{mol/l}$. Potassium is 3.5 $\mu\text{mol/l}$. Diagnosis: OPP in the polyuric

stage. After the treatment, the effect of the treatment was noted and the patient was discharged (06.01.23). At discharge, the general condition is satisfactory. Medical and labor recommendations and observation and treatment by a vascular surgeon, a cardiologist and an endocrinologist, a control CT scan after 3 months were given. Antibacterial therapy for a period of 1 year.

Diagnosis at discharge: Polyvascular disease. Aneurysm of the celiac trunk, superior mesenteric artery. Occlusion at the opening of the celiac trunk. Critical stenosis of the superior mesenteric artery. Extravasal compression of the left renal artery. Syndrome of chronic ischemia артериальная гипертензия III др, риск 4of the digestive system. Cardiorenal hypertension. BCA atherosclerosis. Stenosis in CMPR of both CCA is 35-40%. Chronic cerebrovascular insufficiency I deg. Background: Arterial hypertension III deg, risk 4. Concomitant: Diabetes mellitus type 2, newly diagnosed. Erosive antral gastritis. Umbilical hernia. Combined hemorrhoid. Anemia of mild severity.

The control study 3 months after the surgery is shown in Figure 9 (a, b).

Figure 9 (a, b).
Control CT angiography 3 months after surgery



In this case, the classical onset of the disease was observed. Diagnosis is based on the clinical picture (pain, fever, sepsis), laboratory tests (inflammatory markers) and characteristic morphological features (saccular, sometimes multi-chamber protrusion of the arterial wall, perivascular edema, hematoma and/or fibrous tissue). The presence of gas in the perivascular area and the rapid growth of the aneurysm are pathognomonic symptoms [23, 24].

It can be assumed that an infectious agent joined the site of the greatest atherosclerotic lesion, which caused a penetrating ulcer of the anterior wall of the suprarenal abdominal aorta with the formation of a saccular aneurysm, which is confirmed by the opinion of other authors [17].

The tactics we chose was based on the analysis of literature data. So, in the work of Maksimov A.V. et al. 2 cases were analyzed, in the first case direct intervention

was performed, in the second case endovascular intervention was performed. In the second case after 3 months there was a manifestation of a local infectious process with the development of a fatal complication - aortoduodenal fistula and the patient died [23].

Conclusion

An analysis of the results of examinations suggests that the evolution of this aneurysm occurred as follows: initially, the infection joined the aortic wall (this corresponds to the period of the onset of the disease: pain, fever, increased procalcitonin), after the formation of a defect in the aortic wall, a slight blood supply began under the adventitia and para-aortic fiber with infection in this area. The expansion of the aortic wall defect zone led to the formation of a false aneurysm, and after the active infectious process subsided, an aneurysmal sac lined with thrombotic masses was formed.

References

1. Sampson A, Norman PE, Fowkes GR, Aboyans V, Song Y, Harrell Jr FE, et al. Estimation of global and regional incidence and prevalence of abdominal aortic aneurysms 1990 to 2010. *Glob Heart* 2014;9:159-70.
2. Svensjo S, Bjorck M, Gurtelschmid M, Djavani Gidlund K, Hellberg A, Wanhainen A. Low prevalence of abdominal aortic aneurysm among 65-year-old Swedish men indicates a change in the epidemiology of the disease. *Circulation* 2011;124:1118-23.
3. Клинические рекомендации. Аневризмы брюшной аорты. Москва, 2022. [Klinicheskie rekomendacii. Anevrizmy bryushnoj aorty. Moskva, 2022.] <https://www.angiolsurgery.org/library/recommendations/2022/aneurysm/recommendation.pdf>
4. Pulli R, Dorigo W, Troisi N, Pratesi G. Surgical Treatment Of Visceral Artery Aneurysms: A 25-Year Experience. *Journal Vascular Surgery*. 2008;48 (2): 334-342.
5. Barrionuevo P, Malas M, Nejim B, Haddad A. A systematic review and meta-analysis of the management of visceral artery aneurysms. *Journal of Vascular Surgery*. 2020; 70 (5): 40-45.
6. Stanley J, Wakefield T, Graham L, Whitehouse W. Clinical importance and management of splanchnic artery aneurysms. *Journal of Vascular Surgery*. 1986; 3 (5): 836-840.
7. Cronenwett J.L., Johnston K.W. Rutherford's Vascular Surgery 2-Vol. Sept, 8th Edition
8. Ferrero E, Viazzo A, Ferri M., et al, Management and urgent rep of ruptured visceral artery aneurysms. *Annals of Vascular Surgery*. 20125 (7): 981-987.
9. Etezadi V, Gandhi R, Benenati J., et al. Endovascular treatment of visceral and renal artery aneurysms. *J Vasc Interv Radiol*. 2011 Sep;22(9):1246-53. doi: 10.1016/j.jvir.2011.05.012. Epub 2011 Jul 13.
10. Ibrahim F, Dunn J., Rundback J. Visceral artery aneurysms: diagnosis, surveillance, and treatment. *Current Treatment Options in Cardiovascular Medicine*. 2011; 20 (12):97.
11. El-Sabrou R, Cooley DA. Extracranial carotid artery aneurysms: Texas Heart Institute experience. *J Vasc Surg*. 2000; 31(4):702-712.
12. Goldstone J. Aneurysms of the extracranial carotid artery. *Vascular surgery*. Ed. Rutherford R.B. 6th ed. Philadelphia: Elsevier Saunders. 2005; 2052-2064.
13. Огнестрельное ранение в шею с тромбозом общей сонной артерии в отсроченном периоде. (Разбор клинического наблюдения). Коссович Л.Ю., Кириллова И.В., Шпилянский Э.М., Коньсов М.Н., Иванов Д.В., Сухарева Т.В., Морозов К.М. *Вестник хирургии Казахстана* 2021 (3):10-16. [Ognestrel'noe ranenie v sheyu s trombozom obshchej sonnoj arterii v otsrochennom periode. (Razbor klinicheskogo nablyudeniya). Kossovich L.Yu., Kirillova I.V., Shpiljanskiy E.M., Konysov M.N., Ivanov D.V., Suhareva T.V., Morozov K.M. *Vestnik Khirurgii Kazahstana* 2021 (3):10-16.]
14. Osler W. The Gulstonian Lectures, on Malignant Endocarditis. *British Medical Journal*. 1885; 1: 467-470.
15. Chu C., Wong M.Y., Chiu C.H., et al. Salmonella-Infected Aortic Aneurysm: Investigating Pathogenesis Using Salmonella Serotypes. *Polish Journal of Microbiology*. 2019; 68 (4): 439-447.
16. Hsu R.B., Lin F.-Y. Risk factors for bacteraemia and endovascular infection due to non-typhoid salmonella: a reappraisal. *QJM*. 2005; 98 (11): 821-827.
17. Fournieu L., Nevelsteen A., Lacroix H., Suy R. Microbiological monitoring of aortic aneurysm sac contents during abdominal aneurysmectomy results in 176 patients and review of the literature. *Acta Chirurgica Belgica*. 1996; 96 (3): 119-122.
18. Kesiena O., Da Silva R.C., Kumar N. Contained rupture of a small mycotic abdominal aneurysm in a patient with infective endocarditis. *Cureus*. 2021; 13 (10): 18963.
19. Macedo T.A., Stanson A.W., Oderich G.S., et al. Infected aortic aneurysms: imaging findings. *Radiology*. 2004; 231 (1): 250-257.
20. Chaikof E.L., Dalman R.L., Eskandari M.K., et al. The Society for Vascular Surgery practice guidelines on the care of patients with an abdominal aortic aneurysm. *Journal of Vascular Surgery*. 2018; 67 (1): 1-77. doi.org/10.1016/j.jvs.2017.10.044.
21. Erbel R., Aboyans V., Boileau C., et al. ESC Committee for Practice Guidelines. 2014 ESC Guidelines on the diagnosis and treatment of aortic diseases: Document covering acute and chronic aortic diseases of the thoracic and abdominal aorta of the adult. The Task Force for the Diagnosis and Treatment of Aortic Diseases of the European Society of Cardiology, (ESC). *European Heart Journal*. 2014; 35 (41): 2873-2926. doi.org/10.1093/eurheartj/ehu281.
22. Каммьекое пехоменжанны на ауроноуке м меаенно За Госенантти аопрет (2017). Капауоноруа 1 сепасуно-сосујиерас. *Хурьприя* 2018; 1: 5-70.
23. Максимов А.В., Тергулов А.Ю., Плотников М.В., Постников А.В. Микотические аневризмы брюшной аорты. *Ангиология и сосудистая хирургия. Журнал им. А.В. Покровского*. 2022. Том 28 (3); С. 44-55. [Maksimov A.V., Teregulov A.YU., Plotnikov M.V., Postnikov A.V. Mikoticheskie anevrizmy bryushnoj aorty. *Angiologiya i sosudistaya hirurgiya. Zhurnal im. A.V. Pokrovskogo*. 2022. Tom 28 (3); S. 44-55.]
24. Национальные рекомендации по ведению пациентов с аневризмами брюшной аорты. 2013; 72. Москва. [Nacional'nye rekomendacii po vedeniyu pacientov s anevrizmami bryushnoj aorty. 2013; 72. Moskva.] https://www.angiolsurgery.org/recommendations/2013/recommendations_AAA.pdf