

DAMAGE TO THE BILE DUCTS AFTER LAPAROSCOPIC CHOLECYSTECTOMY. REVIEW

Doskhanov M.O.¹, Baimakhanov B.B.¹, Chormanov A.T.¹,
Baimakhanov Zh.B.¹, Kaniev Sh.A.¹, Skakbayev A.C.¹,
Izmet Zh.I.², Sharmetova K.K.², Ussen L.S.², Madekhanova D.E.²

¹JSC «A.N. Syzganov National Scientific Center for Surgery», Almaty, Kazakhstan

²NC JSC «S.D. Asfendiyarov National Medical University», Almaty, Kazakhstan

MPHTI 76.29.39
https://doi.org/10.35805/BSK2021III017

Doskhanov M.O.
orcid.org/0000-0002-8578-8567

Baimakhanov B.B.
orcid.org/0000-0002-9839-6853

Chormanov A.T.
orcid.org/0000-0003-3513-1935

Baimakhanov Zh.B.
orcid.org/0000-0003-1887-7866

Kaniev Sh.A.
orcid.org/0000-0002-1288-0987

Skakbayev A.C.
orcid.org/0000-0003-0372-068X

Izmet Zh.I.
orcid.org/0000-0002-3132-3924

Ussen L.S.
orcid.org/0000-0002-5113-7926

Madekhanova D.E.
orcid.org/0000-0002-4328-861X

Corresponding author:
Izmet Zh. I. – 7th year intern
physician, NC JSC “S.D. Asfendiyarov
National Medical University”, Almaty,
Kazakhstan
E-mail: jansila_96@mail.ru

Conflict of interest
The authors declare that they have no
conflicts of interest

Abstract

This article provides a review of the literature on bile duct injuries after laparoscopic cholecystectomy. Laparoscopy is considered the gold standard in the treatment of gallstone disease. This technique has a number of positive advantages: minimally invasiveness, quick rehabilitation, a shorter hospital stay, a good cosmetic effect, and a low lethal outcome. Along with these advantages, the number of complications also increased: damage to the bile ducts, hepatic vessels, bile leakage, formation of strictures, defects in drainage of the biliary tract and improper treatment of the cystic duct, insufficient drainage of the abdominal cavity.

Today, many aspects of surgical treatment and prevention of bile duct injuries remain controversial and are still considered relevant. The main reasons for this complication are: lack of experience of the surgeon, inattention, ignorance of the main options and possible anomalies of important anatomical structures in the area of the hepatic hilum and hepato-duodenal ligament, technical errors.

Keywords

iatrogenic trauma to the bile ducts,
damage to the bile ducts, laparo-
scopic cholecystectomy

Өт жолдарының лапароскопиялық холицистэктомиядан кейінгі зақымдалуы.
Әдебиет шолуы

Досханов М.О.¹, Баймаханов Б.Б.¹, Чорманов А.Т.¹, Баймаханов Ж.Б.¹,
Қаниев Ш.А.¹, Сқақбаев А.С.¹, Исмет Ж.И.², Шарметова К.К.²,
Үсен Л.С.², Мадеханова Д.Е.²

¹«А.Н. Сызғанов атындағы Ұлттық ғылыми хирургия орталығы» АҚ, Алматы қ., Қазақстан

²«С.Ж. Асфендияров атындағы Ұлттық медицина университеті» Ке АҚ, Алматы қ., Қазақстан

Аңдатпа

Осы мақалада өт жолдарының лапароскопиялық холицистэктомиядан кейінгі зақымдалуы туралы әдебиетке шолу ұсынылған. Лапароскопия өт жолдарында тас байланатын ауру түрлерін емдеудегі ең негізгі стандарт болып табылады. Бұл әдістің бірқатар артықшылықтары бар: инвазивтіліктің аз мөлшерде болуы, тез қалпына келуі, ауруханада аз ғана уақыт жату, косметикалық әсері жақсы, өлім жағдайының өте аз кездесуі. Осы артықшылықтармен қатар асқынулардың саны да өсті: өт жолдарының, бауыр тамырларының зақымдануы, өт жұмысының нашарлауы, өт жолдарының тарылуы, өт жолдарын айдаудағы ақаулар және өт қабы айналымын дұрыс өңдемеу, іш қуысын жеткіліксіз түрде айдап шығару.

Бүгінгі таңда хирургиялық емдеудің көптеген аспектілері және өт жолдары жарақаттарының алдын алу бүгінгі таңға дейін даулы мәселе болып келеді. Осы асқынулардың негізгі себептері: хирургтың тәжірибесінің жеткіліксіз болуы, ұқыпсыздық, бауыр қақпалары мен бауыр-дуоденальды байлам аймағындағы маңызды анатомиялық түзілімдердің негізгі нұсқалары мен мүмкін болатын ауытқуларын білмеу, техникалық қателіктер.

Хат алысатын автор:
Исмет Ж.И. – 7 курс дәрігер-
интерн, «С.Ж. Асфендияров
атындағы Ұлттық медицина
университеті» Ке АҚ, Алматы қ.,
Қазақстан.
E-mail: jansila_96@mail.ru

Мүдделер қақтығысы
Авторлар мүдделер қақтығысының
жоқтығын мәлімдейді

Түйін сөздер

өт жолдарының ятрогенді
жарақаты, өт жолдарының
зақымдануы, лапароскопиялық
холицистэктомия

Повреждение желчных протоков после лапароскопической холицистэктомии. Обзор литературы

Автор для корреспонденции:
Исмет Жансила – врач-интерн
7 курса, НАО «Национальный
медицинский университет имени
С.Д. Асфендиярова», г. Алматы,
Казахстан.
E-mail: jansila_96@mail.ru

Конфликт интересов
Авторы заявляют об отсутствии
конфликта интересов

**Досханов М.О.¹, Баймаханов Б.Б.¹, Чорманов А.Т.¹, Баймаханов Ж.Б.¹,
Каниев Ш.А.¹, Скакбаев А.С.¹, Исмет Ж.И.², Шарметова К.К.², Усен Л.С.²,
Мадеханова Д.Е.²**

¹АО «Национальный научный центр хирургии им. А.Н. Сызганова», г. Алматы, Казахстан

²НАО «Национальный медицинский университет им. С.Д. Асфендиярова», г. Алматы, Казахстан

Аннотация

В данной статье представлен обзор литературы о повреждениях желчных протоков после лапароскопической холицистэктомии. Лапараскопия считается золотым стандартом при лечении желчнокаменной болезни. Данная методика имеет ряд положительных преимуществ: малоинвазивность, быстрая реабилитация, более короткий срок пребывания в стационаре, хороший косметический эффект, низкий летальный исход. Вместе с данными преимуществами возросло и число осложнений: повреждение желчных протоков, печеночных сосудов, желчеистечение, образование стриктур, дефекты дренирования желчных путей и неправильная обработка пузырного протока, недостаточное дренирование брюшной полости.

На сегодняшний день многие аспекты хирургического лечения и профилактика травм желчных протоков остаются спорными и по сей день считается актуальным. Основные причины данного осложнения: отсутствие опыта хирурга, невнимательность, незнание основных вариантов и возможных аномалий важных анатомических образований в зоне ворот печени и печеночно-дуоденальной связки, технические ошибки.

Ключевые слова
ятрогенная травма
желчевыводящих протоков,
повреждение желчевыводящих
протоков, лапароскопическая
холицистэктомия

The urgency of the problem

Gallstones constitute a significant health problem in developed societies, affecting 10% to 15% of the adult population [1]. With an increase in the incidence of cholelithiasis, the number of surgical interventions on the gallbladder and bile ducts is increasing everywhere. The frequency of damage to the bile ducts during open cholecystectomy remains stable and amounts to 0.05-0.2% [2]. The widespread use of laparoscopic interventions contributed to an increase in iatrogenic injuries by 2-10 times to the level of 0.08-2.7 (Table 1) [3]. Also, the results of surgical treatment of injuries of the bile ducts indicate a high frequency of complications (48.7%), mortality (13-25%) and unsatisfactory long-term results (20-30%) [4]. Scarring of anastomoses reaches 8.4-28.3% [5]. Iatrogenic injury of the biliary tract have increased in incidence in the first decade with the introduction of laparoscopic cholecystectomy. Although a number of factors have been identified with a high risk of injury (and number of technical steps have been emphasized to avoid these injury, the incidence of the bile duct injury has reached at least double the rate observed with open cholecystectomy [6]. The aim of this work is to identify and assess the significance and degree of iatrogenic and biliary complications during laparoscopic cholecystectomy on the basis of the literature data, as well as to pay attention to the factors that increase the likelihood of complications and techniques to avoid these complications.

Material and methods

The article was analyzed from 2015 to 2020 in electronic databases (Cochrane, PubMed) of evidence-based medicine. 138 articles were found. The analysis of the condition of 815 patients (age from 21-70) was carried out. The average age is 46.32 ± 4.64 years. The disease was detected more often in women than in men [7]. According to autopsy data, the detection of stones in the gallbladder is 20-25% [8, 9].

Risk factors for bile duct injury after laparoscopic cholecystectomy

In the works of authors Fedorov, R. Martin and R. Rossi have identified several groups of risk factors for complications during LCE as dangerous anatomy (various structures of the extrahepatic bile ducts, arteries and the presence of pronounced fatty tissue in the gates of the liver and hepato-duodenal ligament), dangerous pathological findings (acute cholecystitis, stone in Hartmann's pocket, short cystic duct, thickened walls of the gallbladder, dilated common bile duct, chronic scars of the gallbladder, bleeding into Calot triangles, adhesions in the abdominal cavity), dangerous surgery (mobilization of the gallbladder body from the liver, maximum mobilization Kahlo's triangle closer to the wall of the gallbladder, intraoperative cholangiography or laproscopic ultrasound, mobilization of the gallbladder from the bottom, performing subtotal cholecystectomy with pronounced cicatricial process and if it is not possible to mobilize it, conversion) [23,24].

Authors, educational institutions, departments	The Title of an article	Research year	Number of patients	Incidence rate
Institute of Gastroenterology of the Academy of Medical Sciences of Ukraine, Dnipetrovsk National University [10].	Iatrogenic complications of laparoscopic cholecystectomy	1993-2003	3864-LCh 46- IBDD	1,19%
Khalidov O.Kh., Gudkov A.N., Dzhaddzhiev A.B., Kartsev A.G., Fomin V.S., Dmitrienko G.P. [7].	Extrahepatic bile duct injury during laparoscopic cholecystectomy	2007-2017	1787- LCh 8- IBDD	0,45%
Filistovich V., Turchina S., Maslennikov S., Filistovich A. [11].	Severe damage to the external bile ducts in laparoscopic cholecystectomy	2004-2008	21- IBDD	
Kubachev K.G., Fokin A.M. [12].	Iatrogenic damage to the extrahepatic bile ducts in laparoscopic cholecystectomy	2001-2016	113- IBDD	39,8%
N. A. Maistrenko, P. N. Romashchenko, A. S. Pryadko, A. K. Aliev [4].	Substantiation of surgical tactics for iatrogenic injuries of the bile ducts	1988-2005	254- IBDD	
Takeyuki Misawa, Ryota Saito, Hiroaki Shiba, Kyonsu Son, Yasuro Futagawa, Takuya Nojiri, Kumiko Kitajima, Tadashi Uwagawa, Yuichi Ishida, Yuji Ishii and Katsuhiko Yanaga [13].	Analysis of bile duct injuries (Stewart-Way classification) during laparoscopic cholecystectomy	1990-2005	5750- LCh 34- IBDD	0,59%
Andrea Frilling, Jun Li, Frank Weber, Nils Roman Fruhauf, Jennifer Engel, Susanne Beckebaum, Andreas Paul, Thomas ZoÉpf, Massimo Malago, Christoph Erich Broelsch [14].	Major Bile Duct Injuries After Laparoscopic Cholecystectomy: A Tertiary Center Experience	1998-2003	40- IBDD	
J. Li, A. Frilling, S. Nadalin, A. Paul, M. Malago and C. E. Broelsch [15].	Management of concomitant hepatic artery injury in patients with iatrogenic major bile duct injury after laparoscopic cholecystectomy	1998-2005	40-IBDD	17 %
S. C. Schmidt J. M. Langrehr U. Settmacher P. Neuhaus [16].	Chirurgische therapie von gallengangverletzungen nach laparoskopischer cholezystektomie . welchen einfluss auf den langzeitverlauf hat die gleichzeitige verletzung der arteria hepatica dextra ?	1990-2002	54- BDD	
A Paczyński , T Koziarski, E Stanowski, J Krupa [17].	Damage to extrahepatic bile ducts during laparoscopic cholecystectomy--own experience	1991-2000	6873- LCh 9- IBDD	
Mohammad Ibrahim Khalil, Haridas Saha, Azmal Kader Chowdhury, Imarat Hossain [18].	Bile duct injuries following laparoscopic cholecystectomy	2013-2015	336- LCh 2- BDD	0,6%
V.F. Kulikovskiy, A.L. Yarosh, A. Karpachev, Coman A.V. Soloshenko, S.B. Nikolaev, E.P. Bitenskaya, N.A. Linkov [19].	Bile leakage after cholecystectomy. Experience with minimally invasive treatment methods	2010-2016	5038- LCh 31- BDD	0,6%

Table 1.
Literature data

G E Chinnery , JEJ Krige , PC Bornman , M M Bernon , S Al - Harethi , S Hofmeyr , M A Banderker , S Burmeister , S R Thomson [20].	Endoscopic management of bile leaks after laparoscopic cholecystectomy	1991-2011	113- BDD	
J.M. Kurbanov [21].	Experience in surgical treatment of complications of laparoscopic colicystectomy	2003-2012	421- LCh 3- BDD	0,7%
Sitnikov V.A., Styazhkina S.N., Ibragimova D.R., Kasimova [22]	Iatrogeny as a cause of postcholecystectomy syndrome	1978-2018	87-BDD	

*LCh** - laparoscopic cholecystectomy

*IBDD** - iatrogenic bile duct damage

*BDD** - bile duct damage

The technical reasons contributing to iatrogenic injuries during cholecystectomy include: Features of the anatomy of the extrahepatic biliary tract; factors complicating the performance of cholecystectomy; violation of the technique of performing operations on the biliary tract. In the anatomy of the biliary tract, there is a wide variety of anatomical options. A practical surgeon is obliged to remember these options, to be able to understand them in a timely manner during the operation and to avoid possible complications. On average, in every fifth to sixth operated patient, the surgeon may encounter difficulties in identifying the place of fusion of the cystic and hepatic ducts (VN Chernyshev, 2001). And this is one of the reasons for the high frequency of iatrogenic injuries of the bile ducts. [22]

Also the risk factors for damage to the biliary tract include old age (increases the risk of damage by 2.5 times), female sex (increases the risk by 26%), late hospitalization of patients [22].

The Laparoscopic damage to the bile ducts has rather large consequences. In recent years, the introduction of new technologies has again made the issue of compliance with the principles of safe surgery and prevention of complications urgent.

Prevention of bile duct injury during and after laparoscopic cholecystectomy

The prevention of damage to the bile ducts is a complex of measures (techniques, diagnostic methods) carried out directly during the performance of laparoscopic cholecystectomy and aimed at preventing damage to the bile ducts. It is based on strict adherence to the principles of a safe technique for performing endoscopic interventions, the correct sequence of the stages of laparoscopic cholecystectomy, taking into account the peculiarities of anatomy and pathological changes, and an understanding of the mechanisms of complications [25].

The risk of complications dictates the need for a complex of preventive measures to prevent complications and optimize intraoperative processes. Safe laparoscopic cholecystectomy involves understanding anatomic landmarks, these include: Calot's triangle, Callo's lymph node, Rouvier's groove, umbilical fissure with the round ligament lying in it, the fourth segment of the liver, pericholedochial venous plexuses [26].

The main requirement when performing laparoscopic cholecystectomy is a thorough preparation of tissues in the area of the Calot triangle and the lower third of the gallbladder bed, as well as conversion or "change of hand" after "idle time" when manipulating the gallbladder neck for more than 30-40 minutes. An important factor in the analysis of the technique and interpretation of the intraoperative situation is the video recording of the entire operation with the subsequent discord of errors and possible shortcomings. If the listed requirements are met, the risk of postoperative complications will be minimized [7].

Intraoperative ultrasound is a screening method for laparoscopic operations, playing the role of the surgeon's "hand", and allows to reduce the number of intraoperative complications. The use of IOUS is advisable in cases of an unclear topographic picture, with various anatomical variants of the bile ducts and great vessels. The high resolution of IOUS in determining structures both in hepaticoholedochus and outside it proves the effectiveness of this diagnostic method, and speaks of the advisability of using echography during laparoscopic and traditional operations [27].

Fluorescence cholangiography significantly reduces the time to reach the "safety critical" in LCE and avoids damage to the bile ducts compared to standard laparoscopy. PC can be successfully used to assess the patency of the IVS in certain situations (suspicion of transient choledocholithiasis, signs of parenchymal jaundice in combination with cholelithiasis, for example, jaundice in liver cirrhosis or chronic hepatitis) [28].

The classification of bile duct injury after laparoscopic cholecystectomy

Currently, there are many classifications of damage to the bile ducts. Abroad, the Bismuth classification (Fig. 1) is especially popular, which classifies damage to the extrahepatic ducts according to the level of their damage [26].

However, most of the developed classifications do not determine the choice of surgery, which significantly reduces their value for a practical surgeon. The classification developed by E.I. Halperin, according to the type of damage, according to the author himself, makes it possible to fill this gap [26].

In 1986 E.I. Galperin et al. Proposed a classification for determining the type of damage and narrowing of the bile ducts, which is very close to the classifications of N. Bismuth and S. Strasberg. V.N. Chernyshev and V.E. Romanov (2001) combined the classification of N. Bismuth and S. Strasberg into a single one (Fig. 1), which they used in their studies [29].

Type I - stricture of hepaticoholedochus with the presence of its unaffected area below the confluence of the hepatic ducts more than 2 cm long;

Type II - stricture of hepaticoholedochus with a free area of the common hepatic duct less than 2 cm long;

Type III - complete cicatricial damage to the common hepatic duct with a free zone of confluence of the lobar hepatic ducts;

V type - complete cicatricial obliteration of the common hepatic duct with the transition to the lobar hepatic ducts;

Type V - high or low cicatricial stricture of the hepatic choleculu with atypical anatomy of the biliary tract.

In 2002 E.I. Galperin published a refined classification of postoperative cicatricial strictures of the hepatic ducts.

The Stewart-Way classification included both complex lesions of the biliary tract and vascular lesions. Based on the Stewart-Way classification (Fig. 2), bile duct trauma is divided into four classes:

Class I injuries occur when the common hepatic duct is mistaken for the cystic duct, but the error is recognized before the common hepatic duct is divided.

Class II injuries involve damage to the common hepatic duct due to clamps or cauterization used too close to the duct. This often happens when vision is limited due to inflammation or bleeding.

Class III injury, the most common type, occurs when the common bile duct is mistaken for the cystic duct. The common duct is transected and the variable portion, including the junction of the cystic and common ducts, is excised or removed.

Class IV injuries involve damage to the right hepatic duct, either because this structure is mistaken for the cystic duct or because it is damaged during dissection [13].

The intraoperative signs of damage to the bile ducts can be: the appearance of bile in the operating field, with an unclear source of bile leakage, the appearance of additional tubular structures in the area of the Calot triangle, expansion of the alleged cystic duct stump during the operation. Any suspicion of injury requires intraoperative cholangiography or conversion. Each removed (gallbladder) should be carefully examined for additional tubular structures before surgery is completed [30].

Bile leakage can sometimes be associated with unrepaired biliary hypertension caused by choledocholithiasis, stenosis of the large duodenal papilla.

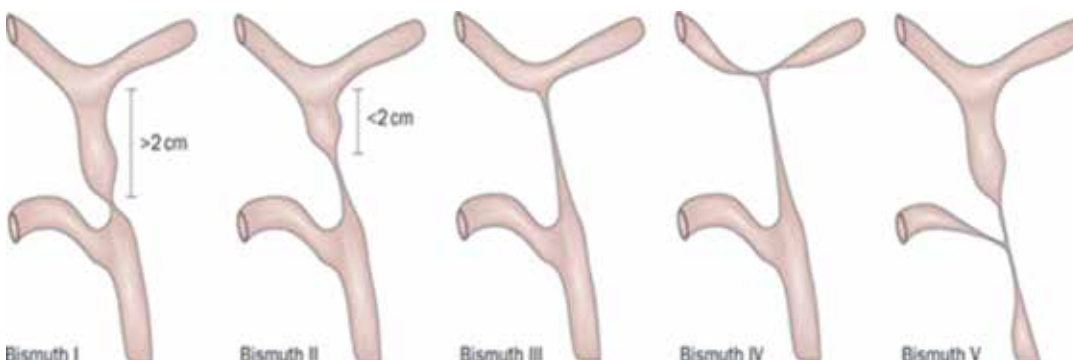
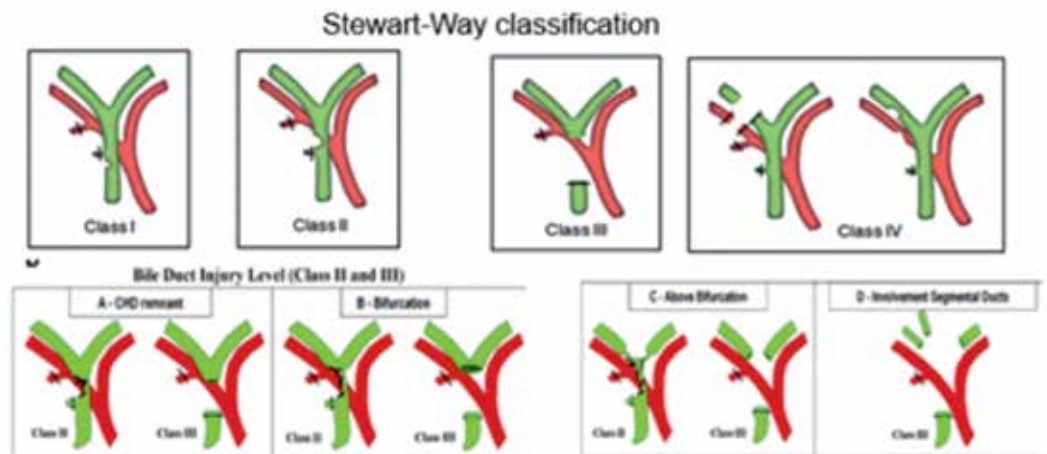


Figure 1.
Anatomical types or classification

Type	Characteristic of strictures
+2	Medium and low - common hepatic duct (AKI) more than 2 cm
+1	High - TPI is 1 - 2 cm
0	Bifurcation - OPP is 0-1 cm
-1	Transbifurcation - the connection of the lobar hepatic ducts (PP) is preserved
-2	Ductal - lobe PP are disjointed
-3	Segmental - lobar RA (more often right) cicatricial changes, preserved segmental RA

Table 2.
Classification of postoperative cicatricial strictures of the bile ducts (E.I. Galperin, 2002)

Figure 2.
Diagnosis of injuries of the
bile ducts after laparo-
scopic cholecystectomy
during surgery



Less than 50% of duct injuries are detected intraoperatively, usually due to bile leakage [31].

Intraoperative recognition usually requires immediate surgical intervention as this gives the best results; however, during surgery, <25–30% of bile duct lesions are recognized, and not all surgeons perform intraoperative cholangiography. If the surgeon is inexperienced, an intra-abdominal drain should be placed and the patient immediately transferred to a large hepatobiliary center [32].

Intraoperative ultrasonography (IUS) visualizes the transverse and the longitudinal planes of not only the biliary structures, but also the portal vein, as well as the hepatic arteries by introducing a linear ultrasound probe [33].

If in open cholecystectomy the main mechanisms of trauma are transection, excision and ligation, then in laparoscopic cholecystectomy clipping and diathermic necrosis of the bile duct wall are added to them [34,35]. Currently, monopolar electrocoagulation remains the main type of dissection in laparoscopic cholecystectomy [36].

Surgical tactics for detecting damage to the bile duct during surgery

In case of intraoperative detection of damage to the bile ducts, it is necessary to immediately perform corrective surgery or, if reconstructive surgery is impossible, external drainage is performed [24].

As a rule, with small marginal lesions, plastic closure of the duct at the site of injury with interrupted sutures with absorbable atraumatic sutures (vicryl, polysorb 4-0) is sufficient in combination with external drainage of the bile ducts through the cystic duct stump or, most often, using a T-shaped drainage. In the case of a dislocation of the clip and the failure of the cystic duct stump in the absence of hypertension in the biliary system and obstructions to the main bile outflow, sanitation of the abdominal cavity and reclipping can be performed with relaparoscopy. With complete confidence in

parietal or complete clipping of the bile duct without violating the integrity of its wall, relaparoscopy with the removal of the clip and external drainage of the biliary tract through the cystic duct cult is also advisable [25].

If a traumatic injury to the bile ducts is detected (during the transection or excision of a segment), 3 options for subsequent actions are possible: external drainage of the biliary system, performing a restorative (biliary-biliary anastomosis end-to-end, prosthetics of the defect) or reconstructive surgery (biliodihistic anastomosis). Surgeons with little experience, in our opinion, should confine themselves to external drainage of the biliary tract, and drain or bandage the distal common bile duct to avoid leakage of pancreatic juice into the abdominal cavity. Subsequently, the patient should be transferred to a specialized department to perform reconstructive surgery [31].

In case of damage to the bile ducts, in many cases, the operation of choice is the imposition of a biliodihistic anastomosis according to Roux, hepaticojejunostomy with transhepatic frame drainage according to Pradery-Smith or Goetze-Saypol-Kurian, and hepaticojejunostomy according to Nerr-Couinaud. The frequency of good and satisfactory results in the treatment of patients with biliary tract injury when using biliodigistive anastomoses ranges from 46 to 94%. Restoration of the common bile duct on a T-shaped drainage of the “end-to-end” type in 50-60% of cases leads to unsatisfactory results [37].

For restoration or reconstruction of damaged bile ducts, the optimal period should be considered 3-5 days, surgical reconstruction in the volume of the Roux loop is accompanied by success in more than 90% of observations within the next 5 years after surgery [38].

With an average level of damage, the incision is extended in the direction of the left lobar duct. In cases of high lesions for access to the left lobar

Injury (1)	Localization (L)	Experience surgeon	Recommended operation
Intersection, Excision	Intra- and extrahepatic	XC (SS)	Reconstructive
	Extrahepatic	X(S)	Drainage of the main bile ducts as the first stage of the operation *
Partial (edge) thermal, clipping	Intrahepatic	X (S)	Reconstructive, usually on a frame drainage
		XC (SS)	Reconstructive, usually on a frame drainage
		X (S)	Drainage connection to the damage site *

Table 3. Classification of “fresh” injuries of the main bile ducts (PLC-ILS), which determines the choice of surgery (E.I. Galperin, A.Yu. Chevokin, 2010)

duct, it is necessary to bring down and dissect the portal plate according to the Hepp-Couinaud technique [25].

In the surgical treatment of high lesions of hepaticoholedochus (from “0” to “-3”) with the involvement of confluence, planar resection of the parenchyma of the hepatic hilum is performed, the unification of the lobar ducts into one trunk, followed by the formation of a bihepaticojejunostomy [12].

Based on the analysis of the experience of surgical treatment of patients with iatrogenic injuries of the biliary tract, it was shown that hepaticojejunostomy was resorted to with high injuries and strictures of the bile ducts and the length of the duct stump at least 30 mm, with high injuries and the residual length of the extrahepatic bile ducts less than 10 mm used hepaticojejunostomy with transhepatic frame drainage according to Pradery-Smith or Goetze-Saupol-Kurian, which allowed the authors to achieve positive results in more than 80% of cases [39].

In case of biliary tract injuries of type IY according to Bismuth, it is possible to use two variants of the operation: the first is the formation of anastomosis separately with each of the lobar ducts, the second is a single anastomosis with a fork formed by stitching the adjacent walls of the lobar ducts according to the method of Shalimov A [25].

In 2009 E.I. Galperin and A. Yu. Chevokin proposed the classification of ILS “fresh” lesions. In 2010, it was supplemented with the heading “Surgeon’s Experience” - the classification of PLC – ILS [29].

Diagnosis of damage to the bile ducts in the postoperative period and surgical tactics

Postoperative diagnosis is based on the clinical picture (manifested in the form of three possible options: bile outflow syndromes, obstruction syndromes or a combination of obstruction and bile outflow), laboratory test results (serum bilirubin level, transaminases, shift of the leukocyte formula to the left, etc.). non-invasive (ultrasound, CT, cholespintigraphy, fistulography through a safety drainage or drainage of the common bile duct) and invasive (retrograde cholecystopancreatography;

percutaneous transhepatic cholangiohepatography and laparoscopy) instrumental methods [31].

Symptoms will be nonspecific and may include fever, pain, and mild hyperbilirubinemia (2.5 mg / dL) due to biloma or biliary peritonitis. Bile leakage may be suspected if bile is produced by percutaneous abdominal drainage or abdominal drainage from cholecystectomy. In the case of injuries associated with occlusion of the common bile duct without intraperitoneal bile flow, the main symptoms will be jaundice with or without abdominal pain [40].

In severe early postoperative cases, patients present with sepsis due to cholangitis or fluid accumulation in the abdomen. If a bile leak is suspected, ultrasound and / or computed tomography of the abdomen will reveal peritoneal fluid, biloma, or abscess. In case of accumulation of perihepatic fluid, drainage can be applied percutaneously. Generally, broad-spectrum parenteral antibiotics are given against common biliary tract pathogens. When percutaneous drainage is applied and ongoing biliary drainage is observed, active bile flow is confirmed [40].

Damage to the bile ducts after laparoscopic cholecystectomy is recognized by the release of bile into the abdominal cavity, which causes peritonitis and creates a favorable environment for bacterial reproduction [26]

Bile leakage, jaundice, biliary peritonitis are the diagnostic triad of damage to the extrahepatic ducts in the postoperative period. Surgical tactics in this case are built after a complete diagnosis of the anatomic structure of the bile ducts, the level and nature of the damage [26].

Radiological examination determines the damage to the bile ducts and its severity, its length and severity, for planning therapeutic treatment. Abdominal ultrasound is the first diagnostic tool to detect any liver congestion, common bile duct dilatation, and any associated vascular lesions [41].

Computed tomography of the abdomen is the primary test that detects the possible presence of focal intra- or focal lesions, accumulation of perihepatic fluid, ascites, obstruction of the biliary tract with upstream dilation, or long-term consequences of prolonged bile stricture such as croupous atrophy of the liver or signs of secondary biliary cirrho-

sis. Computed tomography can also identify any associated vascular lesion, such as the right hepatic artery [42].

Magnetic resonance cholangiopancreatography (MRCP) is the gold standard for the complete morphological assessment of the biliary tract because it offers detailed information about the integrity of the biliary tract [43]. Magnetic resonance cholangiopancreatography can also be performed with a contrast medium (a gadolinium-based contrast medium, gadoxetic acid and its salt, gadoxetate disodium), and it is much more informative in bile leakage than conventional magnetic resonance cholangiopancreatography [44]. The use of contrast media during magnetic resonance cholangiopancreatography allows active bile leakage to be detected by direct contrast imaging, extravasation of material in the fluid collection in addition to demonstrating the anatomical location of the leak and the type of bile duct injury. In the same way, hepatobiliary scintigraphy can confirm the presence of an active bile duct with progressive accumulation of the radioactive tracer within the abdominal cavity, but this test is much less reliable [45].

If bile leakage occurs in the postoperative period, the tactics of treatment depend on the adequacy of the outflow of bile from the abdominal cavity and the cause of complications. If earlier, with bile leakage, many surgeons performed relaparotomy, in recent years, laparoscopic interventions have been performed, during which the source of bile leakage is eliminated (clipping of the bile ducts in the bed of the bladder or the cystic duct stump) or is limited to sanitation of the abdominal cavity and its additional drainage [31].

Reconstructive surgery of damaged bile ducts is performed no earlier than 2 months later. It is more difficult and more difficult to perform biliodigestive anastomosis in patients with complete external biliary fistulas, especially with high confluence and resolution [46].

Damage to the aberrant gallbladder is one of the rarest type of iatrogenism in laparoscopic cholecystectomy, manifested by bile leakage of varying intensity. In most cases, these complications regress on their own, which is associated with the small diameter of the aberrant duct, which is quickly obliterated. Reoperations (suturing the stump of the duct or its restoration on a T-shaped drainage) are required only in cases of a long-term functioning bile fistula or the development of complications against the background of bile leakage [46].

Performing retrograde transpapillary stenting contributes to effective cessation of bile leakage and refusal to perform repeated surgical interven-

tions in case of failure of the cystic duct stump, in case of bile outflow from the gallbladder bed, as well as in case of marginal damage to the extrahepatic bile ducts [47].

Liver resection for bile duct injuries after laparoscopic cholecystectomy

Liver resection is not required for isolated damage to the bile duct [48]. However, the presence of vascular damage worsens the clinical course of the patient, due to the development of complications such as liver necrosis and bile duct stricture [16,49,50]. Because the right hepatic artery runs close and parallel to the cystic duct, it is more vulnerable to injury [51,52] and can be easily ligated if the structures in the Calot triangle are not well defined [53]. Although occlusion of the right hepatic artery is usually well tolerated, as collateral arteries from the diaphragm and retroperitoneal space support the liver [16,54]. The development of intrahepatic abscess [18], ischemic necrosis of the right lobe of the liver [16], recurrent cholangitis and subsequent secondary biliary cirrhosis [16], as well as liver atrophy, require liver resection for successful treatment. The incidence of liver necrosis in patients with damage to the bile duct and arteries with or without abscess formation reaches 75%. Nearly half of these patients who underwent bilioenteric anastomosis to treat a damaged bile duct developed postoperative biliary leakage due to primary hepaticojejunostomy [55] or late ischemic peripheral bile duct stenosis [55]. Thus, patients with confirmed damage to the bile duct should be examined for concomitant hepatic artery damage, and if present, comprehensive treatment should be undertaken immediately [56]. Combined damage to the bile ducts and hepatic artery requires different types of liver resections to treat mainly secondary biliary cirrhosis [57].

Morbidity and mortality in bile duct injuries after laparoscopic cholecystectomy

In the postoperative period after Y-shaped hepaticojejunostomy according to Ruu, 80% of patients developed cholangitis and 20% jaundice. All were re-operated. The average follow-up period after surgery was 49 + 40 months. In the postoperative period, 16% of patients underwent another 2-3 surgical interventions, with a good result achieved in 89% of those operated [58].

The quality of life after the formation of a biliary anastomosis for iatrogenic damage to the biliary tract received disappointing results - their quality of life was significantly reduced ($p < 0.05$). With complete intersection of the duct, in contrast to the marginal wound, poor long-term results of reconstruc-

tive operations were explained by impaired blood supply to the biliary tract and the development of ischemia, which apparently contributed to their postoperative scarring. The indicators of the quality of life of patients with biliodigestive anastomosis superimposed on the duodenum were significantly reduced. After the formation of the Roux-en-Y biliary anastomosis with the hepatic transhepatic drainage, the patients showed decreased indicators of physical functioning, pain intensity, vital activity, general health and role functioning, due to the general physical condition. It is noteworthy that low indicators of the quality of life of the operated patients were characteristic of this group during the period of hepatic transhepatic drainage functioning. After hepaticojejunostomy according to Brown with a "plug" according to Shalimov, the indicators of role functioning and vital activity were reduced on hepatic transhepatic drainage [59].

Combined injuries of the bile ducts and blood vessels account for more than half of the unsatisfactory treatment results and mortality. When the operation is performed by a surgeon who does not have sufficient experience in hepatobiliary surgery, mortality rises to 30%. At the same time, if the operation is performed in a specialized center, the successful result is recorded in 90% [60,61,62,63]. The effectiveness of the radiological approach with

transhepatic stenting of the damaged bile duct is estimated at 40-85% [64].

After repeated operations in the long-term period, cicatricial strictures on the biliary tract develop in 20-30% of cases, and biliary cirrhosis and portal hypertension develop against the background of chronic cholangitis – complications leading to disability [65,66].

The immediate and long-term results of treatment of injuries of the main bile ducts (IVS) are unsatisfactory: the immediate mortality rate is 8-10%, and in the later stages 13-17% [67,68].

Conclusion

The analysis of the literature showed that the prevention, timely diagnosis and treatment of damage to the bile ducts during and after laparoscopic cholecystectomy remains an unresolved issue. Timely diagnosis of damage to the bile ducts and surgical tactics at different stages give good long-term results. In the absence of experience in reconstructive operations, the intervention must be limited to external drainage of the ducts with the subsequent referral of the patient to a specialized hospital. Reconstructive and restorative surgeries for gallbladder injuries should be performed using precision techniques with the presence of atraumatic absorbable suture materials.

References

1. Laura M. Stinton and Eldon A. Shaffer Epidemiology of Gallbladder Disease: Cholelithiasis and Cancer Gut and Liver, Vol. 6, No. 2, April 2012, pp. 172-187 doi:10.5009/gnl.2012.6.2.172
2. Starkov Yu.G., Vyborny M.I., Dzhantukhanova S.V., Andreitseva OI, Khon E.I. Endoscopic treatment of surgical trauma of the right lobar bile duct. Experimental and clinical gastroenterology. 2018; 152 (4): 107-110.
3. Borisov AE Guidelines for surgery of the liver and biliary tract. In two volumes), St. Petersburg SPb: Scythia, 2003.- 488 p.
4. Maistrenko N.A., Romashchenko P.N., Pryadko A.S., Aliev A.K. Substantiation of surgical tactics for iatrogenic injuries of the bile ducts. ISSUES OF GENERAL AND PRIVATE SURGERY "Bulletin of Surgery" 2015 UDC 616.361-089-06.616.361-001-08.
5. Nalbandyan A.G., Anishchenko V.V., Kovgan Y.M., "Methods of percutaneous transhepatic and trans-drainage stenting of post-traumatic strictures of the bile ducts." № 1 - 2015 14.00.00 medical sciences UDC 616.367-001-089.
6. Svab J., Peskova M., Krska Z., Gurlich R., Kasalicky M. Prevention, diagnosis and surgical treatment of injuries of the biliary tract during laparoscopic cholecystectomy. Treatment of papilla injuries caused by invasive endoscopy. Part 2. Surgical treatment of biliary tract injuries. Rozhledy v chirurgii: mesicnik Ceskoslovenske chirurgicke spolecnosti. 2005 April 84(4):182-90.
7. Khalidov O.Kh., Gudkov A.N., Dzhaddzhiev A.B., Kartsev A.G., Fomin V.S., Dmitrienko G.P. "Damage to the extrahepatic bile ducts in laparoscopic cholecystectomy." Annals of Surgical Hepatology, 2017, Volume 22 No. 4 DOI: 10.16931 / 1995-5464.2017446-52
8. Galperin E.I., Vetsheva P.S. - M., 2009. Guidelines for surgery of the biliary tract-569 p.
9. Ivashchenko A. V. "Some questions of the epidemiology of gallstone disease in young patients in the light of 20 years of experience in laparoscopic surgery" / A. V. Ivaschenko // Klin. surgery. – 2012-№ 10 UDK 616.366–003.7–053.81:616.381–072.1–089–036.22.
10. Institute of Gastroenterology, AMS of Ukraine, Dnipetrovsk National University. "Iatrogenic complications of laparoscopic cholecystectomy". <https://medic.ua/bolezni/yatrogennyye-oslozhneniya-laparoskopiche/>
11. Filistovich V., Turchina S., Maslennikov S., Filistovich A. "Severe injuries of the external bile ducts during laparoscopic cholecystectomy." <http://www.sibmedport.ru/article/1090-tjazhelie-povrezhdeniya-naruzhnykh-zhelchnih-protokov-pri-laparoskopicheskoy-holecistektomii/>
12. Kubachev K.G., Fokin A.M. "Iatrogenic damage to the extrahepatic bile ducts in laparoscopic cholecystectomy" Takeyuki Misawa, Ryota Saito, Hiroaki Shiba, Kyonsu Son, Yasuro Futagawa, Takuya

- Nojiri, Kumiko Kitajima, Tadashi Uwagawa, Yuichi Ishida, Yuji Ishii, and Katsuhiko Yanaga. «Analysis of bile duct injuries (Stewart-Way classification) during laparoscopic cholecystectomy» T. 22, № 3, 2017 UDK 616,366-089.87.
13. Takeyuki Misawa, Ryota Saito, Hiroaki Shiba, Kyonsu Son, Yasuro Futagawa, Takuya Nojiri, Kumiko Kitajima, Tadashi Uwagawa, Yuichi Ishida, Yuji Ishii, and Katsuhiko Yanaga. «Analysis of bile duct injuries (Stewart-Way classification) during laparoscopic cholecystectomy» Journal of Hepato-Biliary-Pancreatic Surgery, 13(5), 427–434. doi:10.1007/s00534-006-1099-z.
 14. Andrea Frilling, Jun Li, Frank Weber, Nils Roman FruÈhauf, Jennifer Engel, Susanne Beckebaum, Andreas Paul, Thomas ZoÈpf, Massimo Malago, Christoph Erich Broelsch. «Major Bile Duct Injuries After Laparoscopic Cholecystectomy: A Tertiary Center Experience» Journal of Gastrointestinal Surgery volume 8, pages 679–685 (2004). DOIhttps://doi.org/10.1016/j.gassur.2004.04.005.
 15. Li J., Frilling A., Nadalin S., Paul A., Malago M. and Broelsch C. E. «Management of concomitant hepatic artery injury in patients with iatrogenic major bile duct injury after laparoscopic cholecystectomy» British Journal of Surgery, 95(4), 460–465. doi:10.1002/bjs.6022
 16. Schmidt S.C., Langrehr J.M., Settmacher U., Neuhaus P. «Chirurgische Therapie von Gallengangverletzungen nach laparoskopischer Cholezystektomie. Welchen Einfluss auf den Langzeitverlauf hat die gleichzeitige Verletzung der Arteria hepatica dextra?» ZentralblChir2004;129(6): 487-492 DOI: 10.1055/s-2004-832413
 17. A Paczyński , T Koziarski, E Stanowski, J Krupa «Damage to extrahepatic bile ducts during laparoscopic cholecystectomy--own experience». Medical science monitor 2001 May;7 Suppl 1:102-4.
 18. Mohammad Ibrahim Khalil , Haridas Saha , Azmal Kader Chowdhury , Imarat Hossain «Bile Duct Injuries Following Laparoscopic Cholecystectomy» Journal of Science Foundation 2017;15(1):14-19 DOI: https://doi.org/10.3329/jsf.v15i1.34778
 19. Kulikovskiy F., Yarosh A.L., Karpachev A.A., Coman Soloshenko A.V., Nikolaev S.B., Bitenskaya E.P., Linkov N.A., Av. «Bile leakage after cholecystectomy. Experience of using minimally invasive methods of treatment» Surgery. Journal them. N.I. Pirogov. 2018; (4): 36-40 DOI 10.17116 / hirurgia2018436-40
 20. Chinnery G.E., Krige J.E.J., Bornman P.C., Bernon M.M., Harethi S.A.I., Hofmeyr S., Banderker M.A., Burmeister S., Thomson S.R. «Endoscopic management of bile leaks after laparoscopic cholecystectomy» » South African journal of surgery. 2013 Oct 25;51(4):116-21. DOI: 10.7196/sajs.1829
 21. Dzh.M. Kurbanov «Experience of surgical treatment of complications of laparoscopic colicystectomy» SCIENTIFIC MEDICAL JOURNAL «VESTNIK AVICENNYY» OF THE TAJIK STATE MEDICAL UNIVERSITY NAMED AFTER ABUALI IBNI SINO No. 3, JULY-SEPTEMBER 2013
 22. Sitnikov V.A., Styazhkina S.N., Ibragimova D.R., Kasimova N.R. «Iatrogeny as a cause of postcholecystectomy syndrome. Perm Medical Journal 2020 Volume XXXVII No. 2 DOI: 10.17816 / pmj37241–47
 23. Martin R. F. Bile duct injuries. Spectrum, mechanisms of injury, and their prevention / R. F. Martin, R. L. Rossi // Surg Clin North Am. – 1994 Aug. – Vol. 74, N 4. – P. 781–803
 24. Fedorov I.V., Slavin L.E., Chugunov A.N. Damage to the bile ducts during laparoscopic cholecystectomy. M., 2003.79 p.
 25. Yu.V.Ivanov, D.V. Sazonov, D.P. Lebedev, O.E. Nechaeva Prevention and treatment of intraoperative damage to the extrahepatic bile ducts during laparoscopic cholecystectomy. Original Research Clinical Practice No. 4, 2011.
 26. Almasud R., Osmanova A.O., Mikhailichenko V.Yu. Iatrogenic complications during laparoscopic cholecystectomy and their prevention .Scientific Review. Medical sciences. - 2020. - No. 4 - P. 7-11 doi: 10/17513 / srms.1120
 27. Kurpilyansky, A.V. Intraoperative study of extrahepatic bile ducts, 2005 VAK RF 14.00.27
 28. Malinovsky A.V., Mayorenko M.N., Chernov N.N. The first experience of using fluorescent cholangiography to assess the patency of extrahepatic bile ducts. Hirurgiya of Ukraine.— 2018.— No. 1.— P. 40-45. UDC 616.367-073.8: 681.3
 29. Belokonev V.I. Surgical treatment of patients with injuries and strictures of the bile ducts., 22-24 p.
 30. PA Askarov «Fresh» damage to the extrahepatic bile ducts. Samarkand State Medical Institute, Republic of Uzbekistan. ISSN 1681-2778. Spital surgery. L. Ya. Kovalchuk's magazine. 2018. No. 1 DOI 10.11603 / 2414-4533.2018.1.8854
 31. N. A. Mizurov, A.G. Derbenev, V.V. Voronchikhin. Errors and Complications During Biliary Surgery 2010, «Health care of Chuvashia» 2010, 1 issue
 32. Seeras K, Qasawa RN, Kashyap S, et al. Bile Duct Repair. [Updated 2021 May 30]. In: StatPearls [Internet]. Treasure Island (FL): StatPearls Publishing; 2021 Jan-. Available from: https://www.ncbi.nlm.nih.gov/books/NBK525989/
 33. Floyd W. vande Graaf*, Ina Zaimi, Laurents P. S. Stassen, Johan F. Lange 2018 Safe laparoscopic cholecystectomy: A systematic review of bile duct injury prevention International journal of sutgery 2018 Dec;60:164-172. doi: 10.1016/j.ijssu.2018.11.006. Epub 2018 Nov 12.
 34. Romaschenko P.N., Maistrenko N.A., Pryadko A.S., Aliev A.K. Bile duct trauma and a systemic approach to their elimination Annals of Surgical Hepatology, 2019, volume 24, No.1 DOI:10.16931/1995-5464.2019171-82
 35. Nichitailo M.E., Skums A.V. Surgical treatment of injuries and strictures of the bile ducts after cholecystectomy. Almanac of the Institute of Surgery. A.V. Vishnevsky. 2008 3 (3), 71-76.
 36. Maistrenko N.A., Romashchenko P.N., Aliev A.K., Sibiriev S.A. Acute damage to the bile ducts bulletin of the russian military medical academy founders: military medical academy named after CM. Kirov, LLC «Eco-Vector», Ministry of Defense of the Russian Federation (St. Petersburg) ISSN: 1682-7392eISSN: 2687-1424.
 37. Kurbanov D.M., Rasulov N.I., Ashurov A.S. Complications of laparoscopic cholecystectomy. Novosti Khirurgii. 2014 May-Jun; Vol 22 (3): 366-373.
 38. Kurbanov J.M. «Clinic, diagnosis and surgical treatment of complications of laparoscopic cholecystectomy and methods of their prevention» UDK 616.336-003.7-089.87-072.

39. Pospelov D. Laparoscopic cholecystectomy. Tactics and results of treatment of the most dangerous complications / D. Pospelov // Ukr. honey. hour painting. 2012-06-06
40. Renz, B. W., Bırsch, F., & Angele, M. K. (2017). Bile Duct Injury after Cholecystectomy: Surgical Therapy. *Visceral medicine*, 33(3), 184–190. <https://doi.org/10.1159/000471818>
41. Latteri S, Malaguarnera G, Mannino M, et al. Ultrasound as point of care in management of polytrauma and its complication. *Ultrasound*. 2017;20(2):171–177
42. Antonio Pesce, Stefano Palmucci, Gaetano La Greca, and Stefano Puleo «Iatrogenic bile duct injury: impact and management challenges» *Clinical and Experimental Gastroenterology* • February 2019 DOI: 10.2147/CEG.S169492
43. Palmucci S, Mauro LA, Coppolino M, et al. Evaluation of the biliary and pancreatic system with 2D SSFSE, breathhold 3D FRFSE and respiratory-triggered 3D FRFSE sequences. *Radiol Med*. 2010 ultrasonography in the diagnosis of extrahepatic biliary pathology. *Radiol Med*. 2010;115(3):467–482. DOI:10.1007/s11547-010-0508-1
44. Palmucci S, Mauro LA, La Scola S, et al. Magnetic resonance cholangiopancreatography and contrast-enhanced magnetic resonance cholangiopancreatography versus endoscopic ultrasonography in the diagnosis of extrahepatic biliary pathology. *Radiol Med*. 2010.;115(5):732–746 DOI: 10.1007/s11547-010-0526-z
45. Stewart L. Iatrogenic biliary injuries: identification, classification, and management. *Surg Clin North Am*.2014;94(2):297-310.
46. Nazirov F.G., Devyatov A.V., Babadzhanov A.H., Baibekov R.R. Damage to aberrant bile ducts during laparoscopic cholecystectomy . *Shoshilinch tibbiyot axborotnomasi*, 2019, XII (5) UDK. 611.365-002-003.6-017.
47. Sokolov A.A., Artemkin E.N., Kudishkinan I.N., Saveleyev V.S. «Bile flow in the early stages of post-cholecystectomy: diagnosis and treatment» *Topical issues of endoscopy*, St. Petersburg, 2010.
48. Perini RF, Uflacker R, Cunningham JT, et al. Isolated right segmental hepatic duct injury following laparoscopic cholecystectomy. *Cardiovasc Intervent Radiol* 2005.28:185–195.
49. Madariaga JR, Dodson SF, Selby R, et al. Corrective treatment and anatomic considerations for laparoscopic cholecystectomy injuries. *J Am Coll Surg* 1994. 179:321–325.
50. Nishio H, Kamiya J, Nagino M, et al. Right hepatic lobectomy for bile duct injury associated with major vascular occlusion after laparoscopic cholecystectomy. *J Hepatobiliary Pancreat Surg* 1999-6:427–430.
51. Stewart L, Robinson TN, Lee CM, et al. Right hepatic artery injury associated with laparoscopic bile duct injury: incidence, mechanism, and consequences. *J Gastrointest Surg* 2004-8:523–530; discussion 530–521.
52. Way LW, Stewart L, Gantert W, et al. Causes and prevention of laparoscopic bile duct injuries: analysis of 252 cases from a human factors and cognitive psychology perspective. *Ann Surg* 2003. 237:460–469.
53. Scott-Conner CE, Hall TJ. Variant arterial anatomy in laparoscopic cholecystectomy. *Am J Surg* 1992 163:590–592.
54. Mays ET, Wheeler CS. Demonstration of collateral arterial flow after interruption of hepatic arteries in man. *N Engl J Med* 1974. 290:993–996.
55. Koffron A, Ferrario M, Parsons W, et al. Failed primary management of iatrogenic biliary injury: incidence and significance of concomitant hepatic arterial disruption. *Surgery* 2001.130:722–728; discussion 728–731.
56. Sekido H, Matsuo K, Morioka D, et al. Surgical strategy for the management of biliary injury in laparoscopic cholecystectomy. *Hepatogastroenterology* 2004.;51:357–361.
57. Slater K, Strong RW, Wall DR, et al. Iatrogenic bile duct injury: the scourge of laparoscopic cholecystectomy. *ANZ J Surg* 2002;72:83–88.
58. Treatment of failed Roux-en-Y hepaticojejunostomy after post-cholecystectomy bile ducts injuries / A. Benkabbou [et al.] *Surgery*. – 2013 Jan. – Vol. 153, N 1. – P. 95–102.
59. G. A. Pogosyan 1, A. Z. Vafin 1, A. N. Aidemirov 1,2, E. G. Mnatsakanyan 1,2, K. I. Delibaltov. Quality of life of patients after reconstructive surgery for iatrogenic injury and / or stricture of the bile ducts *MEDICAL BULLETIN OF THE NORTH CAUCASUS* 2014. V. 9. No. 1 DOI - <http://dx.doi.org/10.14300/mnnc.2014.09029>
60. Akbarov M.M., Kurbaniyazov Z.B., Nishanov M.Sh., Rakhmanov K.E., Davlatov S.S. Features of surgical treatment of intraoperative injuries of the bile ducts // *Problems of Biology and Medicine*, 2013. .№2(73). C.383-384.
61. Davlatov S.S., Kurbaniyazov Z.B., Babazhanov A.S., Rakhmanov K.E., Amonov M.M. An improved method of plasmapheresis in the treatment of endotoxemia in purulent cholangitis // *Materials of the Republican scientific-practical conference “Actual problems of hepatology and HIV infection” dedicated to the World AIDS Day. Andijan, 2012.*79-81 p.
62. Kurbaniyazov Z.B., Rakhmanov K.E., Davlatov S.S., Saidmurodov K.B., Zainiev A.F. Factor analysis of the results of surgical treatment of injuries of the bile ducts // *National Surgical Congress in conjunction with the XX Anniversary Congress of ROEH 2017. Moscow. ISSN- 2075-6895. C. 383-384.*
63. Kasimov S. et al. haemosorption In Complex Management of Hepatargia: The International Journal of Artificial Organs, 2013 T. 36. №8.
64. Saidullaev Z.Ya., Rustamov S.U. Surgery of iatrogenic injuries of the main bile ducts. <https://cyberleninka.ru/article/n/hirurgiya-yatrogennyh-povrezhdeniy-magistralnyh-zhelchnyh-protokov-obzor-literatury/viewer>.
65. Gal'perin EI, Vetshev PS. *Manual of bile duct surgery. Moscow: Vidar-M; 2006.*
66. Johnson SR, Koehler A, Pennington LK, Hanto DW. Long-term results of surgical repair of bile duct injuries following laparoscopic cholecystectomy. *Surgery*. 2000. 2000;128(4):668-77.
67. Shapovalyants, C.G., Orlov, S.Yu., Mylnikov, A.G., Pankov, A.G., Budzinskiy, S.A., & Matrosov, A.L. (2005). *Endoskopicheskoye lecheniye “svezhikh” povrezhdeniy zhelchnykh protokov.*
68. Akbarov, M., Askarov, P., & Kurbaniyazov, Z. (2017). Optimization of surgical treatment of “fresh” injuries of the main bile ducts. *European Multi Science Journal*, (10).