ISSN 2306-5559 (print)
ISSN 2410-938X (online)

А.Н.Сызғанов
атындағы
ҰЛТТЫҚ
ҒЫЛЫМИ ХИРУРГИЯ
ОРТАЛЫҒЫ

№ 2 (59) 2019

ҚАЗАҚСТАН ХИРУРГИЯСЫНЫҢ ХАБАРШЫСЫ

ВЕСТНИК ХИРУРГИИ КАЗАХСТАНА

BULLETIN OF SURGERY IN KAZAKHSTAN

АЛМАТЫ /ALMATY

№ 2 (59) 2019
Издается с 2005 г.
ISSN 2306-5559 (print)
ISSN 2410-938X (online)

ҚАЗАҚСТАН ХИРУРГИЯ ХАБАРШЫСЫ
ВЕСТНИК ХИРУРГИИ КАЗАХСТАНА
BULLETIN OF SURGERY IN KAZAKHSTAN

әр тоқсанда шығып тұратын А.Н. Сызғанов атындағы Ұлттық ғылыми хирургия орталығының ғылыми-тәжірибелік журналы
ежеквартальный научно-практический журнал Научного центра хирургии им. А.Н. Сызганова
a quarterly scientific-practical journal of the National Scientific Center of Surgery named after A.N. Syzganov

Журнал ҚР ақпарат, мәдениет және спорт Министрлігінде тіркелген.
«Қазақстан хирургиясының хабаршысы» ҚР ҒБМ Ғылым және білім саласындағы бақылау комитеті ұсынған Ғылыми еңбектің негізгі нәтижелерін жариялау үшін ұсынатын ғылыми баспалар тізбесі енгізілген.
Тіркеу нөмірі 5564-Ж.
Журналдың иесі – «А.Н. Сызғанов атындағы Ұлттық ғылыми хирургия орталығы» АҚ.
Баспаның мекен-жайы:
050004, Алматы қ., Желтоқсан көш. 62,
тел. 7(727) 2795306
http://vhk.kz, e-mail: kaz.vestnik@mail.ru
Әрленім және беттеу:
«*ДАНиЛЕНКО*» ЖК-де дайындалған,
Алматы қ., Чайковский көш. 23-3,
тел. 7(727) 2780172
Таралымы – 500 дана
Корректор: Нұрғалиева А.Н.
e-mail: aigul.nur10792@mail.ru
тел: 87786690021
Жарияланатын мақалалардың мазмұнына авторлар жауапты.
ҚАЗПОЧТА жазылу индексі – 75327

Журнал зарегистрирован в Министерстве информации, культуры и спорта РК.
Журнал включен в перечень научных изданий, рекомендуемых Комитетом по контролю в сфере образования и науки МОН РК
Регистрационный номер: 5564-Ж.
Владелец журнала - АО «Национальный научный центр хирургии имени А.Н. Сызганова».
Адрес редакции:
050004, г. Алматы, ул. Желтоксан, 62,
тел. 7 (727) 2795306
http://vhk.kz, e-mail: kaz.vestnik@mail.ru
Дизайн и верстка:
ИП «*ДАНиЛЕНКО*»,
г. Алматы, ул. Чайковского, 23-3,
тел. 7 (727) 2780172
Тираж – 500 экз.
Корректор: Нургалиева А.Н.
e-mail: aigul.nur10792@mail.ru
тел: 87786690021
Ответственность за содержание публикуемых материалов несут авторы.
Подписной индекс КАЗПОЧТЫ – 75327

The journal is registered with the Ministry of Information, Culture and Sports of the Republic of Kazakhstan.
The "Bulletin of Surgery in Kazakhstan" is included in the list of scientific publications recommended by the Committee for Control of Education and Science, Ministry of Education and Science of Kazakhstan.
Registration number: 5564-Ж
The owner of the journal - JSC «National scientific center of surgery named after A.N. Syzganov»
Editorial address:
62, Zheltoksan street, Almaty, 050004
tel. 7 (727) 2795306
http://vhk.kz, e-mail: kaz.vestnik@mail.ru
Design and lead out:
«*ДАНиЛЕНКО*» SP,
23, Tchaikovsky street, apt.3, Almaty,
tel. 7 (727) 2780172
Edition – 500 copies.
Corrector: Nurgalyeva A.N.
e-mail: aigul.nur10792@mail.ru
tel: 87786690021
The authors are responsible for the content of published materials.
Subscript index of KAZPOST – 75327

МАЗМҰНЫ

ДИАГНОСТИКА ЖӘНЕ ЕМДЕУ

ХИРУРГИЯ

СОДЕРЖАНИЕ

ДИАГНОСТИКА И ЛЕЧЕНИЕ

ХИРУРГИЯ

CONTENTS

DIAGNOSTICS AND THREATMENT

SURGERY

МАЗМҰНЫ

СОДЕРЖАНИЕ

CONTENTS

STATISTICAL INDICATORS ANALYSIS OF PRIMARY LIVER CANCER IN THE REPUBLIC OF KAZAKHSTAN

ID:2019(59)210
DOI: 10.35805/kazsurgeryvhk
2019(59)210
УДК 616.36-006.6-036.22 (575.2)

Issamatov B.K.[1,2], Baimakhanov B.B.[1], Zholdybay Zh.Zh.[2], Medeubekov U.Sh.[1], Chormanov A.T.[1], Tajibaev T.K.[1], Kaniev Sh.A.[1], Sagatov I.Y.[1], Moskalenko N.I.[1], Shmonin V.M.[1], Lagunov I.I.[1]

[1]JSC "National scientific center of surgery named after A.N. Syzganov", Almaty, Kazakhstan
[2]JSC "National medical university", Almaty, Kazakhstan

ABOUT THE AUTHORS
Issamatov Bekzhan Kalibayevich *- researcher of the JSC «NSCS named after A.N. Syzganov»; doctorant of the Department «Visual diagnostics» JSC "National Medical University".*
Baimakhanov Bolatbek Bimendeevich *– Doct. of Med. Sci., Professor, Chairman of the Board JSC «NSCS named after A.N. Syzganov».*
Zholdybay Zhamilya Zholdybayevna *- Doct. of Med. Sci., Professor, Chairman of the Department «Visual diagnostics», JSC "National Medical University".*
Medeubekov Ulugbek Shalkarovich *– Doct. of Med. Sci., Professor, Deputy Chairman of the Board of JSC «NSCS named after A.N. Syzganov».*
Chormanov Almat Tursynzhanovich *– PhD., Deputy Chairman of the Board of JSC «NSCS named after A.N. Syzganov».*
Tajibaev Talgat Kydyraliyevich *– MD, Department of Hepatopancreatobiliary surgery and liver transplantation, JSC «NSCS named after A.N. Syzganov».*
Kaniyev Shokan Ahmedbekovich *– Surgeon, Department of Hepatopancreatobiliary surgery and liver transplantation, JSC «NSCS named after A.N. Syzganov».*
Sagatov Inkar Yergalievich *– Doct. of Med. Sci., Head Department of Scientific, Innovation activity and international cooperation, JSC «NSCS named after A.N. Syzganov».*

For correspondence:
Issamatov Bekzhan Kalibayevich *- 62, Zheltoksan str., Almaty, 050004, Republic of Kazakhstan. Phone: +7-707-828-83-51. E-mail: b.isamatov@mail.ru*

Abstract

Hepatocellular carcinoma is one of the most important problems of the oncological service of the world and Kazakhstan. The article describes the analysis of the main statistical indications of primary liver cancer (hepatocellular carcinoma, HCC) in the Republic of Kazakhstan in the period of 2007-2017. Describes the features of the spread of HCC in the world and in some regions of Kazakhstan. The places for the main indicators of HCC in the structure of oncopathology are identified. Dynamic changes in morbidity and mortality rates of HCC depending on gender, and we have the prognosis for the next 5 years. The incidence and mortality rates of hepatocellular carcinoma of men are higher than women.

Keywords
statistics, liver cancer, hepatocellular carcinoma, morbidity, mortality.

Қазақстан Республикасындағы баурдың біріншілік обырының статистикалық көрсеткіштерін талдау

Исаматов Б.К.[1,2], Баймаханов Б.Б.[1], Жолдыбай Ж.Ж.[2], Медеубеков У.Ш.[1], Чорманов А.Т.[1], Тажибаев Т.К.[1], Қаниев Ш.А.[1], Сағатов І.Е.[1], Москаленко Н.И.[1], Шмонин В.М.[1], Лагунов И.И.[1]

[1]«А.Н.Сызғанов атындағы Ұлттық ғылыми хирургия орталығы» АҚ, Алматы, Қазақстан
[2]«Ұлттық медицина университеті» АҚ, Алматы, Қазақстан

АВТОРЛАР ТУРАЛЫ
Исаматов Бекжан Калибайұлы *– «А.Н. Сызғанов атындағы ҰҒХО» АҚ ғылыми қызметкері, «Ұлттық медицина университеті» АҚ «Визуалды диагностика» кафедрасының докторанты*
Баймаханов Болатбек Бимендеұлы *– м.ғ.д. профессор, А.Н. Сызғанов атындағы ҰҒХО» АҚ басқармасының төрағасы.*
Жолдыбай Жамиля Жолдыбайқызы *- м.ғ.д. профессор, «Ұлттық медицина университеті» АҚ «Визуалды диагностика» кафедрасының меңгерушісі*
Медеубеков Ұлықбек Шалхарұлы *– м.ғ.д. профессор, «А.Н. Сызғанов атындағы ҰҒХО» АҚ басқарма төрағасының орынбасары.*
Чорманов Алмат Турсыжанұлы *- м.ғ.к., «А.Н. Сызғанов атындағы ҰҒХО» АҚ бас дәрігері*
Таджибаев Талғат Қыдыралиұлы *– «А.Н. Сызғанов атындағы ҰҒХО» АҚ Гепатобилиарлы хирургия және бауыр трансплантациясы бөлімінің дәрігері.*
Қаниев Шоқан Ахмедбекұлы *– «А.Н. Сызғанов атындағы ҰҒХО» АҚ Гепатобилиарлы хирургия және бауыр трансплантациясы бөлімінің хирург-дәрігері.*
Сағатов Іңкар Ерғалиұлы *– м.ғ.д., «А.Н. Сызғанов атындағы ҰҒХО» АҚ ғылым, инновация қызметі менеджменті және халықаралық ынтымақтастық бөлімінің жетекшісі.*

Хат-хабар алмасу үшін:
Исаматов Бекжан Калибайұлы *- 050004, Алматы қ., Желтоқсан көш, 62 үй, Қазақстан Республикасы. Тел.: +7-707-828-83-51. E-mail: b.isamatov@mail.ru*

Аңдатпа

Гепатоцеллюлярлық карцинома - әлемдегі және Қазақстандағы онкологиялық қызметтің маңызды мәселелерінің бірі болып табылады. Мақалада 2007-2017 жылдар аралығындағы Қазақстан Республикасындағы бауырдың біріншілік ісігінің (гепатоцеллюлярлық карцинома) негізгі статистикалық көрсеткітеріне талдау жасалды. Әлем және Қазақстанның аймақтарында ГЦК таралуының ерекшеліктері сипатталды. Онкопатология құрылымында ГЦК-ның негізгі көрсеткіштері бойынша орындары анықталды. ГЦК-ның аурушаңдық және өлім-жітім көрсеткіштерінің динамикалық өзгерістері талқыланды, алдағы 5 жылға негізгі көрсеткіштерге болжау жасалды. Ерлердегі гепатоцеллюлярлы карциноманың ауру және өлім-жітім көрсеткіштері әйелдерден жоғары болды.

Түйін сөздер
статистика, бауыр обыры, гепатоцеллюлярлық карцинома, аурушаңдық, өлім-жітім.

Анализ статистических показателей первичного рака печени в Республике Казахстан

Исаматов Б.К.[1,2], Баймаханов Б.Б.[1], Жолдыбай Ж.Ж.[2], Медеубеков У.Ш.[1], Чорманов А.Т.[1], Таджибаев Т.К.[1], Каниев Ш.А.[1], Сагатов И.Е.[1], Москаленко Н.И.[1], Шмонин В.М.[1], Лагунов И.И.[1]

[1]АО «Национальный научный центр хирургии им. А.Н. Сызганова», Алматы, Казахстан
[2]АО «Национальный медицинский университет» Алматы, Казахстан

ОБ АВТОРАХ

Исаматов Бекжан Калибаевич *- научный сотрудник АО «ННЦХ им. А.Н. Сызганова»; докторант кафедры «Визуальная диагностика» АО «Национальный медицинский университет».*

Баймаханов Болатбек Бимендеевич *– д.м.н., профессор, председатель правления АО «ННЦХ им. А.Н. Сызганова».*

Жолдыбай Жамиля Жолдыбаевна - *д.м.н., профессор, заведующая кафедрой «Визуальная диагностика» АО «Национальный медицинский университет».*

Медеубеков Улугбек Шалхарович *– д.м.н., профессор, заместитель председателя правления АО «ННЦХ им. А.Н. Сызганова».*

Чорманов Алмат Турсыжанович *- к.м.н., главный врач АО «ННЦХ им. А.Н. Сызганова»*

Таджибаев Талгат Кыдыралиевич *– младший научный сотрудник отделения Гепатобилиарной хирургии и трансплантации печени АО «ННЦХ им. А.Н. Сызганова»*

Каниев Шокан Ахмедбекович *– врач хирург отделения Гепатобилиарной хирургии и трансплантации печени АО «ННЦХ им. А.Н. Сызганова».*

Сагатов Инкар Ергалиевич – д.м.н., *руководитель отдела менеджмента научной, инновационной деятельности и международного сотрудничества АО «ННЦХ им. А.Н. Сызганова».*

Для корреспонденции:
Исаматов Бекжан Калибаевич - *050004, г. Алматы, ул. Желтоксан, 62, Республика Казахстан. Тел.: +7-707-828-83-51, E-mail: b.isamatov@mail.ru*

Ключевые слова
статистические показатели, рак печени, гепатоцеллюлярная карцинома, заболеваемость, смертность.

Аннотация

Гепатоцеллюлярная карцинома является одной из важнейших проблем онкологической службы мира и Казахстана. В статье описывается анализ основных статистических показаталей первичного рака печени (гепатоцеллюлярная карцинома, ГЦК) в Республике Казахстан за период 2007 – 2017гг. Описывается особенности распространения ГЦК в мире, а также в отдельных регионах Казахстана. Определены места по основным показателям ГЦК в структуре онкопатологии. Приведены динамические изменения показателей заболеваемости и смертности ГЦК в зависимости от пола, проведен прогноз показателей на ближайший 5 лет. Показатели заболеваемости и смертности при гепатоцеллюлярной карциноме у мужчин выше, чем у женщин.

Background

Hepatocellular carcinoma (HCC) - the most common malignant neoplasm of the liver (up to 95%), it is characterized by progressive growth and development [1].

In recent years, the frequency of HCC throughout the world has been increased, for example, more than 600,000 newly detected cases are reported annually [2]. HCC is one of the most actual medical and social problems in the world and in the Republic of Kazakhstan. In the period of 2013-2017, in Kazakhstan has increased the incidence rate of HCC to 5.5 cases per 100 000 (% 000) of population, while the mortality rate remains high (about 1,000 people annually). In 2017, 69% of patients with HCC died before the end of the year. The five-year survival rate is very low (23.7%, 2017) [3 - 13].

HCC is characterized by an aggressive course and an unfavorable prognosis in the most of cases. The five-year survival does not exceed 18%, and after operational recurrence is about 50% [14].

In Kazakhstan, HCC is one of the most actual problems in oncology. The analysis of liver cancer statistics is important in studying of epidemiological situation in the country, consequently the search and development of measures for improving the prevention and diagnosis of HCC.

Hepatocellular carcinoma in the world. According to The GLOBOCAN, in 2018, 18.1 million new cases of cancer and 9.6 million deaths from them were registered worldwide, 841,080 (4.7%) from which were the new cases of HCC and 781,631 (8.2 %) deaths. In the structure of oncopathology, the incidence rate of HCC ranks 6th, after lung, breast, colorectal, prostate and stomach cancers. In terms of mortality it ranks 4th place after lung, colorectal and gastric cancers (figure 1). However, the frequency of men HCC morbidity and mortality was 2-3 times higher than women, therefore, the morbidity and mortality for men ranks 5th and 2nd, respectively [15, 16].

The highest rates of HCC are observed in countries with transitional economies with the low human development index, for example, some African countries (Egypt, Gambia, Guinea) and East and Southeast Asia (Mongolia, Cambodia and Vietnam). In Mongolia, HCC incidence is much higher than in any other country, for example, according to 2018, the incidence of men in Mongolia is four

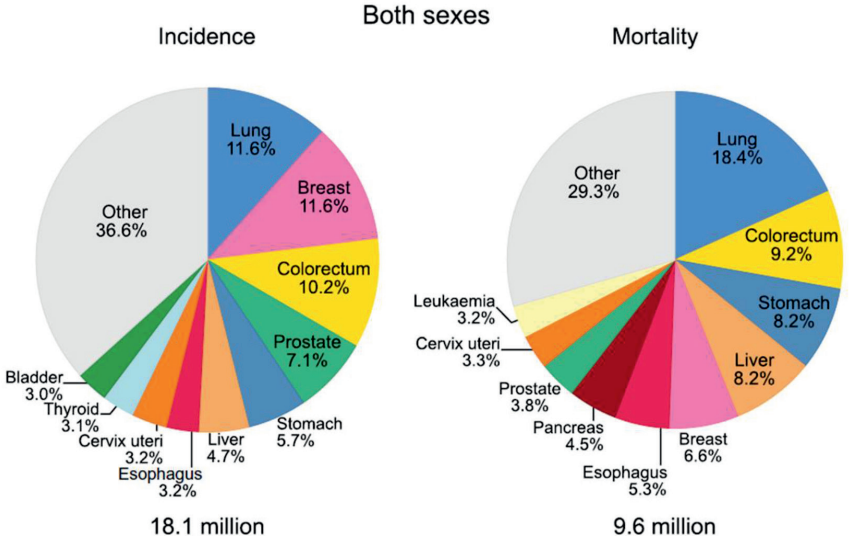

Figure 1.
Diagrams of incidence and mortality of 10 the most common malignant neoplasms in the world (GLOBOCAN 2018)

times higher than in China and the Republic of Korea (figure 2, 3) [15, 16].

The main risk factors depend from the region. In the regions with the highest risk of HCC (China, East Africa), the main determinants are chronic HBV infection and influence of aflatoxin, while in other countries (Japan, Egypt), the prevailing cause is HCV infection. In Mongolia, HBV and HCV infection, HBV co-infection with HCV or HBV with δ (delta) agent, as well as alcohol abuse, are the main risk factors for HCC [15, 16].

The purpose of the research. Analysis of incidence and mortality rates of primary liver cancer (HCC) in Kazakhstan for 2007 - 2017 years.

Material and methods

The analysis is based on the official data of the Committee on Statistics and data of the electronic

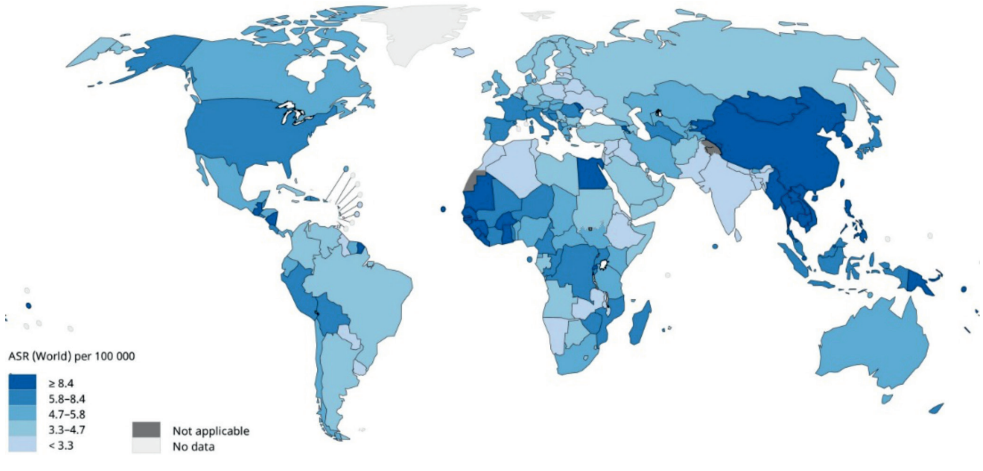

Figure 2.
Worldwide incidence rate of liver cancer (GLOBOCAN 2018).

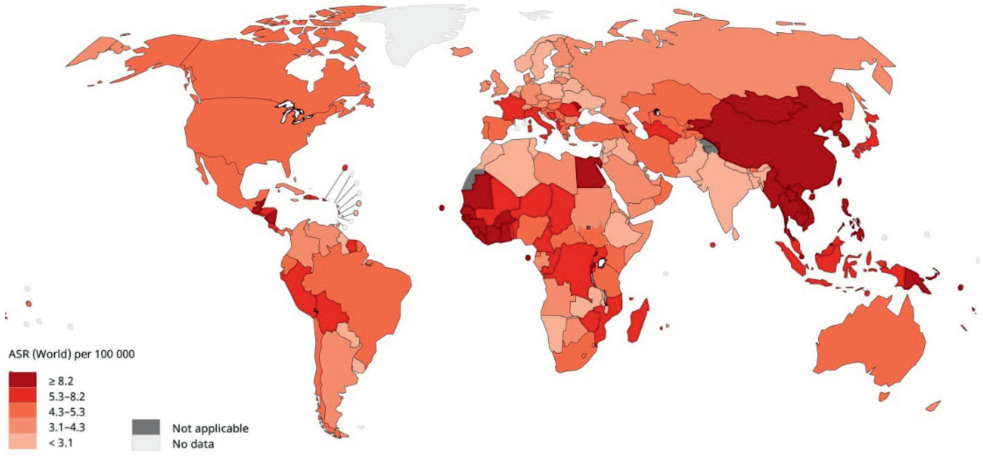

Figure 3.
Worldwide liver cancer mortality rate (GLOBOCAN 2018).

Figure 4. Dynamics of incidence and mortality indicators of HCC in Kazakhstan for the period 2007-2017 per 100 000 population

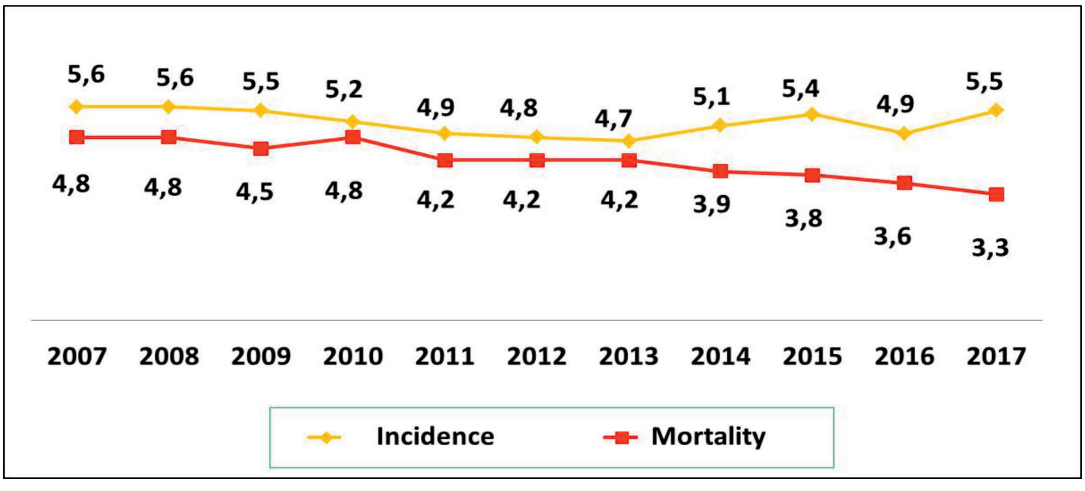

register of oncological diseases of the Republic of Kazakhstan for 2007-2017. Data of the 1st detected cases of HCC disease also were used.

In the analysis standardized incidence and mortality rates (European standard of age) were used, including methods of demographic and mathematical statistics.

For statistical tests carrying out and dynamic graphs of the main indicators of HCC plotting, we've used the SPSS and Microsoft Excel packages.

Results and discussion

During the period of 2007 - 2017, 8615 patients with primary liver cancer were registered in the Republic of Kazakhstan, 59% of which are men, 41% are women.

According to the data of 2016, the incidence rate of HCC of both sexes ranked 12th in the structure of oncological diseases, namely, after malignant neoplasms of the breast, lung, stomach, cervix, colon, lymphatic and hematopoietic tissues, prostate, rectum, esophagus, pancreas, and among men it takes the 10th place.

The incidence of primary liver cancer in the period from 2007 to 2017, increased on 1.3%. If the incidence rate of HCC in 2007 was 5.6% 000, then in 2013 it decreased to 4.7% 000. However, in recent years, the HCC incidence rate has gradually increased and in 2017 reached 5.5% 000, which is 10.9% more compared to 2016. Analysis of the dynamics of changes in the HCC incidence during the period of the research study showed that there is a risk further increase in incidence in subsequent years (figure 4) [3-13].

The mortality rate of HCC consistently occupied the 10th place in the structure of oncological diseases in Kazakhstan during the analysis of study. For example, in 2017, the mortality rate of HCC was after malignant neoplasms of the lung, stomach, breast, esophagus, colon, under the gastric gland, hemoblastosis, rectum, cervix, accounting for 4.2% of all oncological mortality. Analysis of the dynamics of changes in the mortality rate showed that over the study period, mortality decreases annually, and has a tendency to further decrease, not counting the years where the indicator was the same as the previous year. So, for example in 2007 mortality was 4.8% 000, and in 2017 - 3.3% 000. The average level of HCC mortality over the past decade decreased by 0.84% annually, and in 2017 the absolute number of deaths decreased on 8.0% comparing to 2007 (figure 4) [3-13].

For making the prognosis for the next 5 years (2018 - 2022), incidence and mortality rates of HCC in the Republic of Kazakhstan, we've used the SPSS and Microsoft Excel packages. When performing a regression analysis in terms of incidence and mortality, the approximation coefficient R2 was 0.64 and 0.92 respectively, and the standard error of R2 was 0.23% and 0.15% ($p = 0.017$; $p < 0.001$) respectively. Whereas the standard error R2 is less than 15%, then the data which we obtained, have reliable significance and can be used as regression. The test of the significance of the regression model was carried out with the F - Fisher criterion using (table 1).

Table 1. Determination of the significance of the regression model in terms of incidence and mortality rates HCC 2007 – 2017, with F - Fisher criterion using.

Year / indicator (per 100 000 population)	2007	2008	2009	2010	2011	2012	2013	2014	2015	2016	2017	Approximation coefficient R^2	Standard error R^2	p-value
Incidence	5,6	5,6	5,5	5,2	4,9	4,8	4,7	5,1	5,4	4,9	5,5	0,64	0,23	0,017
Mortality	4,8	4,8	4,5	4,8	4,2	4,2	4,2	3,9	3,8	3,6	3,3	0,92	0,15	<0,001

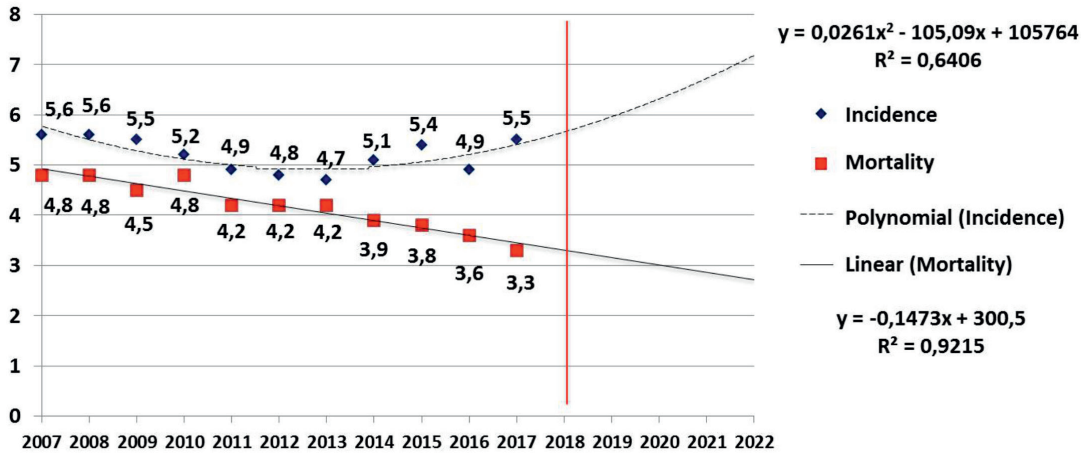

Figure 5.
Building a trend line to predict incidence and mortality rates for HCC of both sexes for the next 5 years on the basis of data for the period 2007 - 2017

An increasing trend was obtained, during the usage of a polynomial curve of the second degree to build a trend line in terms of incidence rates of HCC 2007 - 2017. It predicts an increase in the incidence of HCC over the next 5 years. Also for the mortality rate, a linear trend was built, which had a downward line, which predicts a decrease of mortality over the next 5 years (figure 5).

An analysis of the dynamic changes in incidence and mortality in 2008–2017 was carried out all over the regions of Kazakhstan. A graph has been made in the context of 2008, 2010, 2013, 2015, 2017 and the following data obtained. In 2008, the highest incidence of the morbidity marked in West Kazakhstan (11.8% 000), Kyzylorda (10.4% 000), Akmola (7,0% 000) regions and the lowest index marked in North Kazakhstan (3.7% 000), the South Kazakhstan (3.2 % 000), Pavlodar (4.4 % 000) regions. In 2017, the worst situation was registered in Karaganda (8.0 % 000), West Kazakhstan (7.6 % 000) and In East Kazakhstan (6.8% 000) regions. The lowest incidence rates were recorded in Astana (4.2% 000), Aktobe (4.1% 000) and North Kazakhstan regions (3.6% 000) (figure 6) [3-13].

The highest mortality rate in 2008 was registered in West Kazakhstan (10.4% 000) Kyzylorda (8,5% 000), East Kazakhstan (6.1% 000)) regions and the lowest number of deaths observed in South Kazakhstan (2,5% 000), Almaty (2.7% 000), and Pavlodar (3.2% 000) regions. In dynamics, in 2017 the mortality rate prevailed in East Kazakhstan (5.2% 000), Akmola (5.0% 000), West Kazakhstan (4.7% 000) regions. The lowest mortality rate was observed in Kostanay (1.4% 000), Astana (2.1% 000), Aktyubinsk (2.4% 000) belts (figure 7) [3-13].

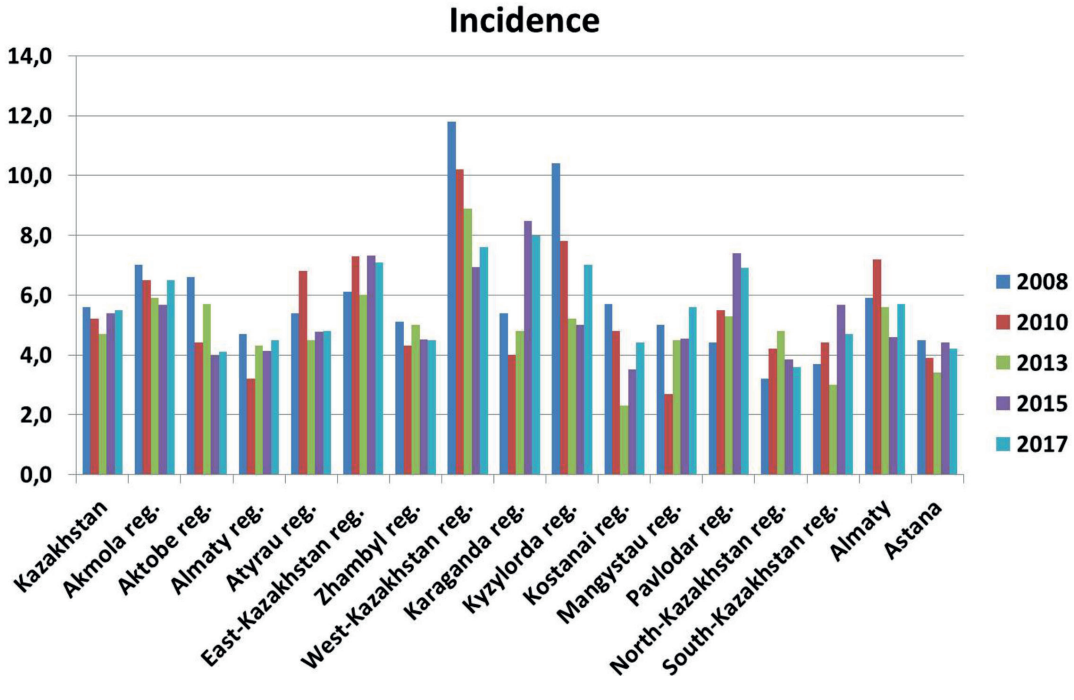

Figure 6.
The graph of dynamic changes in the incidence rate of HCC for all regions of Kazakhstan in 2008, 2010, 2013, 2015 and 2017 for 100 000 population.

Figure 7. A graph of the dynamic changes in the mortality rate of HCC for all regions of Kazakhstan in 2008, 2010, 2013, 2015 and 2017 per 100 000 population.

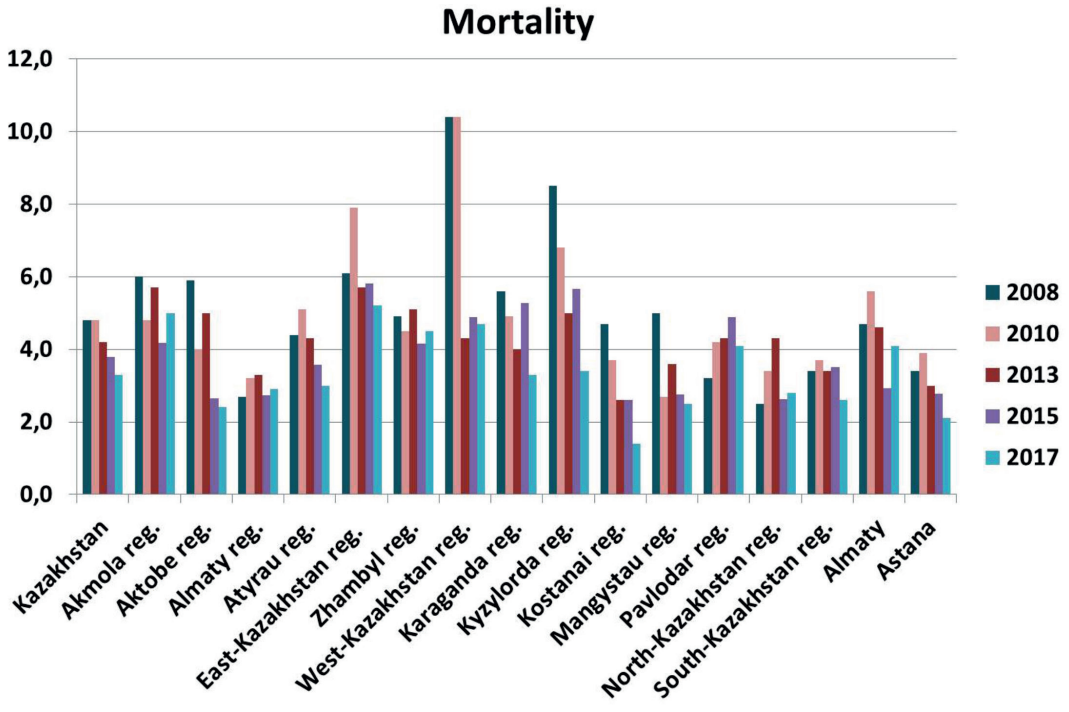

For a comparative analysis of the incidence rate depending on the age group of both sexes, the ratio of the absolute number of new cases of HCC to the population of this age group was calculated and the indicator was obtained in a ratio per 100 000 population. For example, there is a significant increase in the incidence rate among men in the age group of 50 - 54 years, reaching a peak in the group of 70 - 74 years. It is assumed that there is a natural increase in the incidence of HCC after 50 years, with the highest number of new cases up to 70 years of men. Women, the incidence significantly increases from 55 years, but reaches the highest values in the group 75-79 years. Consequently, the data obtained tell us about the dependence of the incidence of HCC on sex and age (table 2, figure 8).

Conclusion

Thus, primary liver cancer, namely, hepatocellular carcinoma, is one of the most important prob-

Table 2. Indicators of HCC incidence for 2007 – 2017 of men and women, depending on age group per 100 000 population

Age group	0-4	5-9	10-14	15-19	20-24	25-29	30-34	35-39	40-44	45-49	50-54	55-59	60-64	65-69	70-74	75-79	80 +
Men	0,23	0,07	0,07	0,12	0,16	0,35	0,55	1,07	2,56	5,43	12,75	22,22	38,21	52,85	63,18	60,27	51,25
Women	0,31	0,01	0,06	0,17	0,12	0,14	0,40	1,05	1,63	2,62	5,16	9,36	14,55	22,29	31,39	32,26	26,49

Figure 8. Graph of HCC incidence rate in 2007-2017 depending on the age group of both sexes (per 100,000 population)

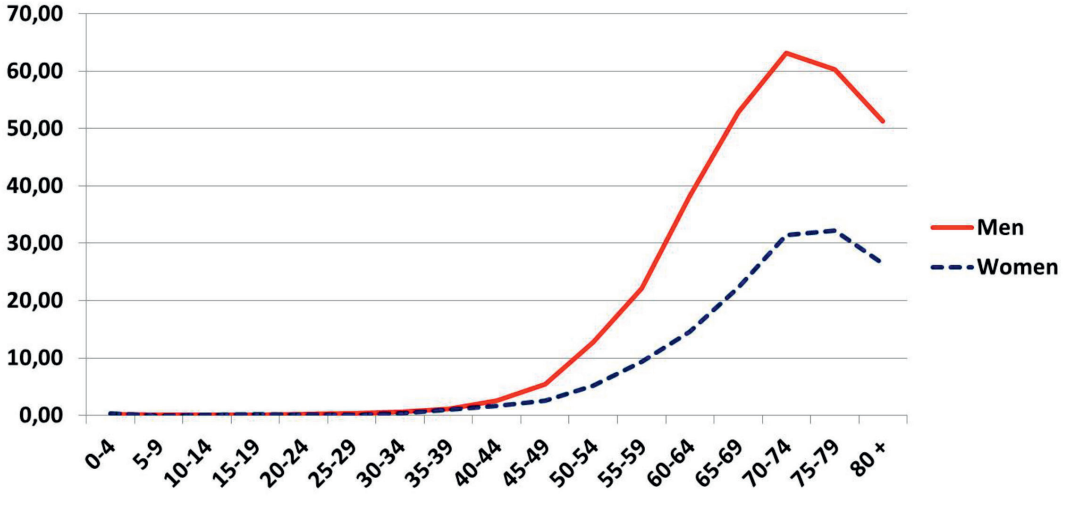

lems of the oncological service of the world and Kazakhstan. According to statistics, there is an annual increase in the number of new cases of HCC. HCC occupies the leading places in terms of incidence and mortality in the world. In the structure of oncological diseases of Kazakhstan, HCC, in terms of incidence and mortality, takes, although not the leading places, nevertheless has a significant problem in connection with the progressive course, late detection, low survival rate and unfavorable prognosis. In recent years, there has been an increase in the incidence of HCC and a decrease in the death rate. According to the prognostic test, a further increase in morbidity and a decrease in mortality rate of HCC in both sexes in the next 5 years in Kazakhstan is expected. The highest incidence and mortality rates for the study period were observed in the West Kazakhstan, Kyzylorda and East Kazakhstan regions. The lowest incidence rates are registered in Almaty, North Kazakhstan and Kostanay regions. The lowest mortality rates were observed in the South Kazakhstan, Kostanay and Almaty regions. For men, morbidity and mortality values were 2 times higher than for women. A significant increase in the incidence was observed for men after 50 years and up to 74 years, and for women after 55 years and up to 79 years. Summarizing all of the above, in order to solve this medical and social problem, namely reducing the incidence and mortality rate, in our opinion, we need the mechanisms to identify the causes of morbidity in each region of the country, to pay special attention to people over 50 years old, namely in the “red” regions of the country to apply effective measures for early and clarifying diagnostics, as well as timely tactics for treating patients with hepatocellular carcinoma.

References

1. Bray F., Stuart B, et al. Transitions in human development and the global burden of cancer. ed. World Cancer Report 2014. Lyon: IARC Press; 2014: 42-55.
2. Masao Omata, Ann-Lii Cheng, Norihiro Kokudo et al. Asia–Pacific clinical practice guidelines on the management of hepatocellular carcinoma: a 2017 update. Hepatol Int 2017; 11:317–370
3. [Indicators of the cancer service of the Republic of Kazakhstan for 2007]. [Published in Russian]. (statistical materials - KazIOR - Almaty - 2008)
4. [Indicators of the cancer service of the Republic of Kazakhstan for 2008]. [Published in Russian]. (statistical materials - KazIOR - Almaty - 2009)
5. [Indicators of the cancer service of the Republic of Kazakhstan for 2009]. [Published in Russian]. (statistical materials - KazIOR - Almaty - 2010)
6. [Indicators of the cancer service of the Republic of Kazakhstan for 2010]. [Published in Russian]. (statistical materials - KazIOR - Almaty - 2011)
7. [Indicators of the cancer service of the Republic of Kazakhstan for 2011]. [Published in Russian]. (statistical materials - KazIOR - Almaty - 2012)
8. [Indicators of the cancer service of the Republic of Kazakhstan for 2012]. [Published in Russian]. (statistical materials - KazIOR - Almaty - 2013)
9. [Indicators of the cancer service of the Republic of Kazakhstan for 2013]. [Published in Russian]. (statistical materials - KazIOR - Almaty - 2014)
10. [Indicators of the cancer service of the Republic of Kazakhstan for 2014]. [Published in Russian]. (statistical materials - KazIOR - Almaty - 2015)
11. [Indicators of the cancer service of the Republic of Kazakhstan for 2015]. [Published in Russian]. (statistical materials - KazIOR - Almaty - 2016)
12. [Indicators of the cancer service of the Republic of Kazakhstan for 2016]. [Published in Russian]. (statistical materials - KazIOR - Almaty - 2017)
13. [Indicators of the cancer service of the Republic of Kazakhstan for 2017]. [Published in Russian]. (statistical materials - KazIOR - Almaty - 2018)
14. Kulik LM, Chokechanachaisakul A. Evaluation and management of hepatocellular carcinoma. Clin Liver Dis 2015; 19: 23-43
15. F.Bray; J.Ferlay; I.Soerjomataram et al. Global Cancer Statistics 2018: GLOBOCAN Estimates of Incidence and Mortality Worldwide for 36 Cancers in 185 Countries\\ CA CANCER J CLIN 2018;68:394–424
16. Global Cancer Statistics 2018: GLOBOCAN, https://gco.iarc.fr/today/home

ID:2019(59)211
DOI: 10.35805/kazsurgeryvhk
2019(59)211
МРНТИ 76.29.34

EFFECT OF REPERFUSION TO THE ANTIOXIDANT PROTECTION SYSTEM OF HEPATIC TISSUE IN EARLY STAGE OF ISCHEMIA

ABOUT THE AUTHORS

Mirzayev Mirhafiz Ibrahim oglu *– of Assistant the Department of pathomorphology AMU*

Mirzayev M.I.
Azerbaijan Medical University, Department of Pathologic Anatomy, Baku, Azerbaijan

Abstract

One of the actual problems of contemporary medicine is the restoration of the tissue structure that has been impaired. Because today, with the rapid development of medical technology, the pathologies called "inoperabel" were brought to life by organ transplantation. Liver cirrhosis, malignant tumors without metastasis, chronic renal failure, and so on. liver and kidney transplantation has become a therapeutic tool for the treatment of illness.

The experiments were performed on head white rats. Experiments were carried out in accordance with the rules set out in Protocol No. 31 of the Bioethics Committee of 21 April 2008. All weighing procedures and experimental extraction on animals have been accomplished through inhalation anesthesia.

Anesthesia was given to animals to form a liver ischemia model, and the abdominal cavity was opened at full disinfection. The right part of the artery entering the liver has been mobilized and taken to the liver. By using the ligature, a reperfusion pattern has been created to relieve the ischemia.

Keywords
Liver, pathology, tissue, ischemia.

Ишемияның ерте сатысында реперфузияның бауыр тінінің антиоксиданттық қорғау жүйесіне әсері

АВТОРЛАР ТУРАЛЫ

Mirzayev Mirhafiz Ibrahim oglu *– АМУ-ң патоморфология кафедрасының ассистенті 0704366394*

Mirzayev M.I.
Әзірбайжан медициналық университеті,Патологиялық анатомия бөлімі,Баку, Әзірбайжан

Аңдатпа

Замануи медицинаның өзекті проблемаларының бірі тіннің бұзылған құрылымын бұрынғы қалпына келтіру болып табылады. «Ота жасауға болмайтын» деп танылған патологиялар бойынша қазіргі таңда медициналық технологиялардың жылдам дамуымен органдар трасплантатталуға тиісті. Бауыр циррозына шалдыққан, қатерлі өсінділер мен ісіктер пайда болған кезінде метазданусыз, созылмалы бүйрек жетіспеушілігісіз және өзге де аруларға шалдыққан жағдайда, бауыр мен бүйректі трансплантаттау емдеу әдістерінің бірі болып табылады.

Эксперименттер ақ түсті егеуқұйрықтардың __ басына жасалған. Аталмыш эксперименттер 2008 жылғы 21 сәуірдегі биоэтика бойынша Комитетте баяндалған ережелеріне сәйкес жүргізілген. Жануарларда жасалатын өлшеу және сынама үшін ішінен алу емшаралары ингаляциялық анестезия арқылы іске асырылған.

Жануарларға бауыр ишемиясының моделін қалыптастыру үшін наркоз берілген, сонымен ішперде құысы толық асептикалық жағдайларында ашылған.

Бауырға келіп түсетін артерияның оң жағы жұмылдырылып, бауырға жеткізілген. Лигатураны қолдана отырып, ишемияны жеңілдету үшін реперфузиялық суреті салынған.

Түйін сөздер
Бауыр, патология, тін, ишемия

Влияние реперфузии на систему антиоксидантной защиты ткани печени на ранней стадии ишемии

Mirzayev M.I.
Азербайджанский Медицинский университет, отдел патологической анатомии, Баку, Азербайджан

ОБ АВТОРАХ

Mirzayev Mirhafiz Ibrahim oglu, *асс. кафедры патоморфологии АМУ 0704366394*

Аннотация

Одной из актуальных проблем современной медицины является восстановление нарушенной структуры ткани. Сегодня с быстрым развитием медицинских технологий, патологии, называемые «неоперабельными», подлежат трансплантации органов. При циррозе печени, злокачественных новообразованиях без метастазирования, хронической почечной недостаточности и других заболеваниях трансплантация печени и почек стала одним из методов лечения.

Эксперименты проводились на __ головах белых крыс. Эксперименты проводились в соответствии с правилами, изложенными в Протоколе № 31 Комитета по биоэтике от 21 апреля 2008 года. Все процедуры взвешивания и экспериментального извлечения на животных были выполнены под ингаляционной анестезией.

Животным давали наркоз для формирования модели ишемии печени, и брюшную полость открывали при полных асептических условиях. Правая часть артерии, поступающая в печень, была мобилизована и доставлена в печень. Используя лигатуру, был создан реперфузионный рисунок для облегчения ишемии.

Ключевые слова
печень, патология, ткани, ишемия

One of the actual problems of contemporary medicine is the restoration of the tissue structure that has been impaired. Because today, with the rapid development of medical technology, the pathologies called “inoperabel” were brought to life by organ transplantation. Liver cirrhosis, malignant tumors without metastasis, chronic renal failure, and so on. liver and kidney transplantation has become a therapeutic tool for the treatment of illness (1,2,3). However, there are a number of problems waiting to be resolved in the organ transplantation. One of them is a toxic effect on the cell membrane, which is formed during tissues during the ischemia and is distributed to the tissues during reperfusion of toxic substances collected into the tissue areas. Despite the fact that the various research efforts to neutralize this effect, some pathological processes in the cell membrane have a negative impact on the function of the transposed member (4,5,6), even under the influence of reperfusion. Given all this, we considered it appropriate to study the effect of strengthening the body’s antioxidant protection system by creating liver function and reperfusion in the experiment.

The experiments were performed on __ head white rats. Experiments were carried out in accordance with the rules set out in Protocol No. 31 of the Bioethics Committee of 21 April 2008. All weighing procedures and experimental extraction on animals have been accomplished through inhalation anesthesia.

Anesthesia was given to animals to form a liver ischemia model, and the abdominal cavity was opened at full disinfection. The right part of the artery entering the liver has been mobilized and taken to the liver. By using the ligature, a reperfusion pattern has been created to relieve the ischemia.

At the end of the experiment, the liver was removed from the abdominal cavity and placed in the Petri casserole and washed with a physiological solution. Then, finely chopped porcelain was assembled into the case and homogenate was prepared by homogenisator. The antioxidant markers were determined by rinsing 1:3 with the homogeneous physiological solution.

To evaluate the body’s antioxidant protection system, the following markers have been identified for the liver-prepared homogenate.

1. Protein hydrosulfide groups on the surface (nmol / mq).
2. Structural internal protein hydrosulfide groups (nmol / mq).
3. Reduced glutation (nmol / mq).
4. Activity of the catalase (sv).
5. Total antioxidant activity (cc).

Surface and structural internal hydrosulfide, reducted glutathione Elman (7), catalase enzyme thickness Bergmeyer (8), General antioxidant activity (UAF) E.V.Spector and co. (9).

The experiments were divided into five groups (Table 1).

Table 1.
Separation of white rats by groups under experiment

N	Groups	Experiments	Quantity of experimental animals
1	1	Intact condition	5
2	2	Hepatic ischemic model	15
3	3	Reperfusion after ischemia during 5 minutes	25
4	4	5 min. Ischemia after injection of Mexidol	5
5	5	Perfusion after ishemia of 5 min. through injection of Mexidol	

The obtained quantitative data are statistically quantified by non-parametric method of Wilcoxon - Manna - Whitney taking into account modern recommendations (10).

Practice results.

The homogeneous surface SH - group consisting of liver lipids included in Group 1 is 31.4-35.1 nmol / mg and the mean density is 33.5 ± 0.7 nmol / mg. The density of the reduced gluten is between 12.4 and 14.7 nmol / mg. The average thickness is 13.2 ± 0.4 nmol / mg. The density of the catalase is 264,67-267,35 sq.m. The average thickness is 265.9 ± 0.5 sq. Km. UAF activity was 39.61-41.57% and the mean density was 40.6 ± 0.3%.

The liver's ischemic model has been developed to reduce the thickness of the antioxidant protection system in experimental animals on the fifth minute of the ischemia.

Compared to the intracorporal condition, the density of the SH group in the liver tissue decreased by 0.5%, the concentration of the structural SH group - 1.2%, the density of the reduced gluten content - 1%, the catalase density - 0.2%, the UAF concentration - 1.6% . The quantitative data from the experiments are given in Table 2. As you can see from this, it has been a catalase-enzyme resistant to ischemia. UAF activity is a marker that is more sensitive to ischemia.

On the 15th minute of the Ishemia model, the antioxidant protection system in liver tissue has significantly lessened.

In 15 minutes after the creation of the Ishemia model, the thickness of the SH group in the liver tissue decreased 6% compared to the intimal state. The decline in the structure of the internal SH group of structures has reached 9.6%. The most decline was recorded in the thickness of the coagulation. The concentration of the known enzyme decreased by 11.5% compared with the intake. During the 15-minute ischemia, as in the previous observation, the density of catalase decreased at a slower pace. Thus, the density of catalase in this period decreased by 0.9% compared to the intake situation. More interesting dynamics were observed in the decrease in UAF activity. Thus, in the fifth minute of the ischemia, when its activity was 1.6%, in the 15th minute this decrease was 4%;

Thus, as the ischemia period lengthens, the antioxidant protection system in the liver tissue paralyzes. This condition is more apparent in the 30th minute of the ischemia. Thus, in the 30th minute, the concentration of homogeneity of liver tissue

Table 2.
Changes in the thickness of the antioxidant protection system markers depending on the duration of the ischemia.

N	Stages of the experiment	Statistical indices	Surface SH group	Structural SH group	Gluation	Catalase	UAF
1	Intact situation	Min Max M±m	31,4 35,1 33,5±0,7	20,9 24,6 22,7±0,7	12,4 14,7 13,2±0,4	264,67 267,35 265,9±0,5	39,61 41,57 40,06±0,3
2	Ischemia for 5 minutes	Min Max M±m P	31,3 35 33,3±0,7 *	20,07 24 22,4±0,6 *	12,2 14,6 13,1±0,4 *	264,15 267 265,4±0,5 *	38,4 41 40,0±0,5 *
3	Ischemia for 15 minutes	Min Max M±m P	30 33,2 31,4±0,6 **	17,6 22 20,5±0,8 **	9,2 13,6 11,7±0,8 *	261 266 263,4±0,9 **	36,4 40 38,9±0,6 *
4	Ischemia for 30 minutes	Min Max M±m P	27,5 32 29,5±0,8 ***	15,6 22 18,7±1,1 **	8,2 13,6 10,4±0,9 **	258,8 266 261,6±1,5 **	35 39 37,0±0,7 ***

Note ** - P>0,05, ** - P<0,05, *** - p<0,01*

was significantly higher than that of the SH group in 11.8%, the density of the structural SH group was 17.5%, the density of reducted gluten content was 21.4%, catalase density was 1.6%, UAF activity was reduced by 9%.

Thus, the results of our experiments allow us to conclude that the liver's ischemia weakens the overall antioxidant protective system in liver tissue and its weakness is correlated with the duration of the ischemia (Table 2).

The white rats included in Group 3 were reperfused for 15 minutes after 5 minutes of ischemia. At this time, the following changes in the markers of the general antioxidant protection system in the liver tissue were detected.

The liver tissue in the liver tissue of the experimental animals included in group III decreased by 2.6% compared to the intensity of the SH group and by 2.1% compared to the 5th minute of the 2nd group. Structural density SH group density, respectively, decreased by 4.1% and 2.9% respectively.

The density of the reduced glucose continued to decline. This difference was 6.3% compared to the 1st group and 5.4% compared to the second group. The density of catalase decreased by 1.1% compared with the 1st group and by 0.9% compared to the corresponding period of the 2nd group.

Relevant changes have also been made in the UAF's activity. Thus, its activity decreased by 8.4% compared with the current situation and by 7% compared to the 5th minute of the 2nd group.

Thus, despite the restoration of blood flow, the organism's total antioxidant defense system continues to weaken due to the spread of some intermediate products.

The density of markers of antioxidant protection system, except for the surface SH group, continues to decline in the 30th minute of reperfusion.

The surface SH group, compared with other indicators, increased by 1.4% compared with the current situation and by 2% compared to the corresponding period of the 2nd group.

The density of the internal SH group of the structure decreased by 6.8% in comparison with the intestine and by 5.6% compared to the 30th minunte of the ischemia. The thickness of the reduced glucose in liver tissue continued to decline (Table 3). The decrease in its thickness was 4.9% in comparison with the intimal state and 3.9% in 30 minutes of the ischemia.

Unlike other markers of the antioxidant protection system, the density of catalase has changed relatively little. Compared with the duration of both observations, its density was reduced by 1%.

Table 3.
Changes in density of antioxidant protection system markers, depending on the duration of reperfusion conducted on 5-minute ishemic background

N	Stages of the reperfusion	Statistical indices	Surface SH group	Structural SH group	Gluation	Catalase	UAF
1	Intact condition	Min Max M±m	31,4 35,1 33,5±0,7	20,9 24,6 22,7±0,7	12,4 14,7 13,2±0,4	264,67 267,35 265,9±0,5	39,61 41,57 40,06±0,3
2	15min	Min Max M±m P	30,4 34,5 32,6±0,7 *	20 23,4 21,8±0,6 *	11,2 13,8 12,4±0,4 *	261,5 264,9 263,0±0,6 **	35 39 37,2±0,7 **
3	30 min	Min Max M±m P	30,8 39,9 33,9±1,6 *	19,5 22,7 21,1±0,6 *	11,6 14 12,5±0,4 *	260 266 263,2±0,9 **	35 41 38,5±1,0 **
4	1 hour	Min Max M±m P	29,7 34 32,3±0,7 *	18,6 23,1 20,8±0,9 *	11,1 14 12,3±0,5 *	261,5 265 263,1±0,6 ***	34,1 40,8 37,9±1,2 **
5	3 hours	Min Max M±m P	29,1 33,5 31,8±0,8 *	18 22 20,3±1,0 *	10,8 14 12,2±0,6 *	261 264,7 262,5±0,6 ***	34 40 37,3±1,1 **
6	24 hours	Min Max M±m P	29,4 33,8 31,4±0,8 **	16,7 23 20,4±1,3 *	9 15 12,1±1,0 *	261,7 265 262,9±0,6 ***	34 41 37,8±1,3 **

Note ** - P>0,05, ** - P<0,05, *** - p<0,01*

The decrease in UAF activity continued intensively. Compared to the 30th and 30th week of intestinal and ischemia, its density decreased by 5.2% and 3.6%, respectively.

Thus, in the 30th minute of reperfusion, the antioxidant protection system in liver transplantation continues to decline.

After 1 hour of reperfusion, the density of the SH group in the liver tissue was 3.5% in intravenous condition and 2.9% in comparison with the corresponding period of the 2nd group. The density of the structural SH group has been significantly reduced. This difference was 8.1% in comparison with the intensity level and 7% compared to the 1st hour of the 2nd group. The density of the reduced oxidation has sharply declined. This difference is 6.4% compared to the intensity situation and 5.4% compared to the 1st hour of the 2nd group.

As in each stage, there is not much difference in the thickness of the catalase in the first hour. Its thickness decreased by 1% compared to both comparisons.

There was also a sharp change in the UAF's activity. Its activity decreased by 6.7% in comparison with the current situation and by 5.2% compared to the corresponding period of the 2nd group.

Despite the fact that 3 hours after reperfusion, the antioxidant defense system in the liver continues to weaken.

The concentration of homogeneous surface SH produced from liver decreased by 5.1% compared with the intake and by 4.6% compared to the corresponding period of the 2nd group.

The density of the structural SH group has dropped sharply. The decrease in its concentration was 10.4% compared to the intake situation and 9.3% compared to the corresponding period of the 2nd group.

The density of reduced gluten was 7.7% in comparison with the intake situation and 6.8% in comparison with the corresponding period of the 2nd group. Reduction of catalase density is relatively intensified. Thus, decrease of catalase concentration in liver tissue was 1,3 and 1,1%, respectively, compared to the 1st and 3rd groups.

The density of UAF decreased by 8.1% in comparison with the intensive care unit and by 6.6% compared to the corresponding time of the 2nd group.

Comparison with 24 hours after reperfusion showed that except for the superficial SH group and the density of the reduced glucose, the other indicators were somewhat stabilized and tend to increase compared to the third hour of reperfusion (Table 3).

Thus, the thickness of the surface SH group decreased and the difference in intensity was 6.2% and the difference in the 24th hour of the 2nd group was 5.7%.

Structural SH group density was 10.1% in comparison with the intensity and 8.9% in the 24th hour of the 2nd group.

Decreased density of reduced gluten was 8.3% in comparison with its intake condition and 7.4% compared to the 24th hour of the 2nd group. The density of catalase decreased by 1% compared to the two periods.

Unlike the catalase, the concentration of UAF has been significantly reduced. This difference was 7% compared to the intake situation and 5.5% compared to the 2nd group. Thus, as a result of our experiments, it has been established that, despite the short duration of the ischemia (5 minutes) in the liver, the antioxidant protection system in liver tissue continues to weaken within 24 hours after reperfusion.

References

1. Готе С.В. Трансплантация печени: клинические и хирургические аспекты //50 лекций по хирургии. Под ред. В.С.Савельева, М.: Триада – Х. 2004. С.436-451.
2. Шумаков В.И. Трансплантология М.: МИА, 2006, - 540 с.
3. Busuttil R.W., Klintmalm G.K. Transplantation of the liver – Elsevier Saunders, 2005. – 1485 p.
4. Феодоров В.Д., Вишневский В.А., Назаренко Н.А., и др. Основные осложнения обширных резекций печени и пути их предупреждения //Бюллетень, Сибирский медицины 2007, № 3, с.16-21.
5. Ходосовский М.Н., Зинчук В.В. Влияние нитропруссида натрия на кислород связывающие свойства крови при ишемии реперфузии печени у кроликов //Российский физиологический журнал им. И.М.Сеченова 2012, № 5, с.610-617.
6. Abbulla Oguz, Murat Kapan, Ibrahim Kaplan et al., The effects of sulforaphane on the liver and remote organ damage in hepatic Ischemia – reperfusion model formed with pringle maneuver in rats //International Journal of Surgery. 2015, N 18, p.163-168.
7. Ellman C., Tissue Sulfhydryle groups //Archivcs of Biochemistry and Biophysics 1959, N 1, p.70-77.
8. Bergmeyer H. Biochemistry Information. Methods of enzymatic analysis. Verlag Chemic 1974. V.2, p.45-47.
9. Спектор Е.В., Ананенко А.А., Политова Л.Н. Метод определения антиокислительный активности сыворотки крови //Лаб.дело. 1984, № 1, с.26-28.
10. Лакин П.Ф. Биометрия М. Высшая школа. 1990, 352 с.

THE ROLE OF DIABETES IN THE DEVELOPMENT OF PERIPHERAL ARTERY DISEASES AND RECENT WAYS OF REVISCULARIZATION OF LOWER LIMB ARTERIES (REVIEW)

МРНТИ 76.29.37

Zhakubayev M.A.[1,2], Egemberdiev T.Zh.[2], Matkerimov A.Zh.[1], Baubekov A.A.[1,2], Tergeusizov A.S.[1], Tajibayev TK.[1], Shamshiev A.S.[1], Saduakas A.E.[1], Makkamov R.O.[1], Nurmaganbet S.T.[1], Sharifova B.K.[1]
[1]JSC "National scientific center of surgery named after A.N. Syzganov", Almaty, Kazakhstan
[2]JSC "National medical university", Almaty, Kazakhstan

ABOUT THE AUTHORS
Zhakubayev M.A. *- angiosurgeon, PhD doctoral student of KazNMU named after S.D. Asfendiyarov, a vascular surgeon of the Department of Angiosurgery of the JSC NSCS named after A.N. Syzganov;*
Yegemberdiyev T.Zh. *- professor, MD, the head of the cardiovascular surgery department of surgical diseases № 3 KazNMU named after S.D. Asfendiyarov;*
Baubekov A.A. *- Phd doctoral student of KazNMU named after. S.D. Asfendiyarov, a vascular surgeon of the Department of Angiosurgery of the JSC NSCS named after A.N. Syzganov;*
Matkherimov A.Zh. *- Head of the Department of Angiosurgery of the JSC NSCS named after A.N. Syzganov;*
Tergeusizov A.S. *- angiosurgeon of the JSC NSCS named after A.N. Syzganov;*
Tadjibaev T.K. *- angiosurgeon of the JSC NSCS named after A.N. Syzganov.*
Shamshiev A.S. *- angiosurgeon of the JSC NSCS named after A.N. Syzganov;*
Saduakas A.E. *– resident angiosurgeon of the JSC NSCS named after A.N. Syzganov;*
Makkamov R.O. *– resident angiosurgeon of the JSC NSCS named after A.N. Syzganov;*
Nurmahanbet S.T. *– resident angiosurgeon of the JSC NSCS named after A.N. Syzganov;*
Sharifova B.K. *– resident angiosurgeon of the JSC NSCS named after A.N. Syzganov.*

Abstract

Diabetes is one of the priority diseases in the health care system of all countries of the world, due to the high prevalence of this pathology in the population and the increase in socio-economic losses associated with the development of severe disabling complications. Every year, more than 1 million operations of amputation of the lower extremities in diabetes are performed in the world, more than 600 thousand patients lose their sight, and approximately 500 thousand patients develop renal failure. Over 50% of all non-traumatic amputations are accounted for by diabetics. The article provides a literature review, covering foreign and domestic data. The review is devoted to modern approaches to various types of diagnostics and treatment of peripheral artery diseases caused by diabetes, comparative studies, as well as prevention methods.

Keywords
diabetes, peripheral artery diseases, amputation.

Қант диабетінің перифериалық артериялардың ауруларының дамуындағы рөлі және аяқ артерияларын реваскуляризациялаудың заманауи әдістері (әдеби шолу)

Жакубаев М.А.[1,2], Егембердиев Т.Ж.[2], Маткеримов А.Ж.[1], Баубеков А.А.[1,2], Тергеусизов А.С.[1], Таджибаев Т.К.[1], Шамшиев А.С.[1], Садуакас А.Е.[1], Маккамов Р.О.[1], Нурмаганбет С.Т.[1], Шарифова Б.К.[1]
[1]«А.Н.Сызғанов атындағы Ұлттық ғылыми хирургия орталығы» АҚ, Алматы, Қазақстан
[2]«Ұлттық медицина университеті» АҚ, Алматы, Қазақстан

АВТОРЛАР ТУРАЛЫ
Жакубаев М.А. *– С.Д. Асфендияров атындағы ҚазҰМУ Phd докторанты, А.Н. Сызғанов атындағы ҰҒХО АҚ қан-тамырлар бөлімшесінің ангиохирургы;*
Егембердиев Т.Ж. *- профессор, м.ғ.д., С.Д. Асфендияров атындағы ҚазҰМУ №3 хирургиялық аурулар кафедрасының жүрек-қан тамырлары хирургиясы курсының меңгерушісі;*
Маткеримов А.Ж. *– А.Н. Сызганов атындағы ҰҒХО АҚ қан-тамырлар бөлімшесінің меңгерушісі;*
Баубеков А.А. *- С.Д. Асфендияров атындағы ҚазҰМУ Phd докторанты, А.Н. Сызғанов атындағы ҰҒХО АҚ қан-тамырлар бөлімшесінің ангиохирургы;*
Тергеусизов А.С. *- А.Н. Сызганов атындағы ҰҒХО АҚ қан-тамырлар бөлімшесінің дәрігер- ангиохирургі;*
Таджибаев Т.К. *– А.Н. Сызганов атындағы ҰҒХО АҚ қан-тамырлар бөлімшесінің дәрігер- ангиохирургі.*
Шамшиев А.С. *– А.Н. Сызганов атындағы ҰҒХО АҚ қан-тамырлар бөлімшесінің дәрігер- ангиохирургі;*
Садуакас А.Е. *– А.Н. Сызганов атындағы ҰҒХО АҚ резидент - ангиохирургі.*
Маккамов Р.О *– А.Н. Сызганов атындағы ҰҒХО АҚ резидент - ангиохирургі.*
Нурмаганбет С.Т. *– А.Н. Сызганов атындағы ҰҒХО АҚ резидент - ангиохирургі.*
Шарифова Б.К. *– А.Н. Сызганов атындағы ҰҒХО АҚ резидент - ангиохирургі.*

Аңдатпа

Қант диабеті - халықтың осы патологиясының жоғары таралуы және ауыр бұзылуға әкелетін асқынулардың дамуымен байланысты әлеуметтік-экономикалық шығындардың өсуіне байланысты әлемнің барлық елдерінің денсаулық сақтау жүйесіндегі басым аурулардың бірі. Жыл сайын әлемде қант диабетіне байланысты төменгі аяқтардың ампутациясы 1 миллионнан астам операция жасалады, 600 мыңнан астам пациент өз көзқарасын жоғалтады, ал 500 мыңға жуық пациент бүйрек жетіспеушілігін дамытады. Травматикалық емес ампутацияның 50% -дан астам диабетпен ауратын науқастарда тіркелген. Мақалада шетелдік және отандық деректерді қамтитын әдеби шолу қарастырылған. Шолу пациенттердің қант диабеті, салыстырмалы зерттеулер, сондай-ақ алдын алу әдістерімен туындаған шеткері артерия ауруларын диагностикалаудың және емдеудің заманауи тәсілдеріне арналған.

Түйін сөздер
қант диабеті, периферия артерия аурулары, ампутация.

Роль сахарного диабета в развитии заболеваний периферических артерий и современные способы реваскуляризации артерий нижних конечностей (обзор литературы).

Жакубаев М.А.[1,2], Егембердиев Т.Ж.[2], Маткеримов А.Ж.[1], Баубеков А.А.[1,2], Тергеусизов А.С.[1], Таджибаев Т.К.[1], Шамшиев А.С.[1], Садуакас А.Е.[1], Маккамов Р.О.[1], Нурмаганбет С.Т.[1], Шарифова Б.К.[1]

[1]АО «Национальный научный центр хирургии им. А.Н. Сызганова», Алматы, Казахстан
[2]АО «Национальный медицинский университет» Алматы, Казахстан

ОБ АВТОРАХ

Жакубаев М.А. *– PhD докторант КазНМУ им С.Д. Асфендиярова, сосудистый хирург отделения ангиохирургии АО ННЦХ им. А.Н. Сызганова;*
Егембердиев Т.Ж. *- профессор, д.м.н., зав.курсом сердечно-сосудистой хирургии кафедры хирургических болезней №3 КазНМУ им. С.Д. Асфендиярова;*
Маткеримов А.Ж. *– заведующий отделом ангиохирургии АО ННЦХ им. А.Н. Сызганова;*
Баубеков А.А. *- PhD докторант КазНМУ им. С.Д. Асфендиярова, сосудистый хирург отделения ангиохирургии АО ННЦХ им. А.Н. Сызганова;*
Тергеусизов А.С. *- врач-ангиохирург АО ННЦХ им. А.Н. Сызганова;*
Таджибаев Т.К. *– врач-ангиохирург АО ННЦХ им. А.Н. Сызганова;*
Шамшиев А.С. *– врач-ангиохирург АО ННЦХ им. А.Н. Сызганова;*
Садуакас А.Е. *– Резидент ангиохирург АО ННЦХ им. А.Н. Сызганова;*
Маккамов Р.О. *- Резидент ангиохирург АО ННЦХ им. А.Н. Сызганова;*
Нурмаганбет С.Т. *- Резидент ангиохирург АО ННЦХ им. А.Н. Сызганова;*
Шарифова Б.К. *- Резидент ангиохирург АО ННЦХ им. А.Н. Сызганова.*

Ключевые слова
сахарный диабет, заболевания периверических артерий, ампутация.

Аннотация

Сахарный диабет (СД) является одним из приоритетных заболеваний в системе здравоохранения всех стран мира, что обусловлено высокой распространенностью данной патологии в популяции и ростом социально-экономических потерь, связанных с развитием тяжелых инвалидизирующих осложнений. Каждый год в мире производят более 1 миллионов операций по ампутации нижних конечностей при сахарном диабете, более 600 тысяч больных теряют зрение, приблизительно у 500 тысяч пациентов развивается почечная недостаточность. Более 50% всех нетравматических ампутаций приходится на долю больных сахарным диабетом. В статье проводится литературный обзор, охватывая зарубежные и отечественные данные. Обзор посвящен современным подходам к различным видам диагностики и лечения заболеваний периферических артерий, обусловленные сахарным диабетов, сравнительные исследования, а так же методы профилактики.

Diabetes mellitus (DM) is one of the priority diseases in the health care system of all countries of the world, due to the high prevalence of this pathology and the increase in socio-economic losses due to the presence of disabling complications. Social significance is due to chronic complications, leading to early disability, deterioration of quality of life and reduction of its life expectancy. These include microangiopathy (nephropathy, acute coronary death, retinopathy, coronary heart disease, angina), peripheral vascular disease, diabetic foot syndrome, including gangrene, cerebrovascular disease (transient cerebral ischemia, stroke), diabetic neuropathy. According to the WHO, one person with diabetes dies every 10 seconds in the world; - about 4 million people. Every year, more than 1 million operations on amputation of lower extremities in diabetes are performed in the world, more than 600 thousand patients lose their sight, approximately 500 thousand patients develop renal failure [1]. International Diabetic Federation leads to complications caused by diabetes: every 12 min. registered stroke, 15 min. - amputation, 18 min. - myocardial infarction, 30 min; - blindness, the need for dialysis - 90 min [2].

In the predominant half of people suffering from type 2 diabetes, the disease progresses, leading to serious complications. Often, from the onset of the disease and the formulation of the diagnosis itself, it takes a long time, during which late complications develop, which are the main cause of disability and death. Diabetes in 70-80% of cases, leads to the development of cardiovascular diseases, cerebrovascular diseases, diabetic retinopathy and blindness, diabetic foot and the development of gangrene of the lower extremities. Diabetes of the second type leads to an increase in the risk of cardiovascular diseases by 2 times, blindness by 10 times, amputations of the limbs by 20 times [3]. Over 50% of all non-traumatic amputations are accounted for by diabetics. At the same time, half of all amputations can be prevented, as well as it is possible to prevent vision loss by patients due to the development of retinopathy and cataracts in them. These facts make the need for early diagnosis of complications vital, and the late detection of these complications can lead to the emergence of medical and social problems [4]. Diabetes worldwide is recognized as one of the most important non-communicable diseases, ranking fourth among causes of death in developed countries. The number of patients with diabetes mellitus is constantly growing due to an increase in the number and age of the population, the urbanization of the territory, the prevalence of obesity and a sedentary lifestyle [5]. In Kazakhstan, according to the National Register of Diabetes mellitus for 2012, the number of patients with diabetes has reached 207,935 people. According to the IDF Diabetes Atlas for 2017, the prevalence of diabetes in Kazakhstan among adults

is 6.97%. In 2045, the expected increase in diabetes will be 7.74%. Diabetes worldwide is recognized as one of the most important non-communicable diseases, ranking fourth among causes of death in developed countries. The number of patients with diabetes mellitus is constantly growing due to an increase in the number and age of the population, the urbanization of the territory, the prevalence of obesity and a sedentary lifestyle [5]. In Kazakhstan, according to the National Register of Diabetes mellitus for 2012, the number of patients with diabetes has reached 207,935 people. According to the IDF Diabetes Atlas for 2017, the prevalence of diabetes in Kazakhstan among adults is 6.97%. In 2045, the expected increase in diabetes will be 7.74%.

PAD in patients with diabetes is much more aggressive, with early involvement of large vessels, together with distal symmetric neuropathy. The need for high amputation in diabetics occurs 5-10 times more often than non-diabetics. Sensory neuropathy contributes to an increase in the frequency of amputations with a decrease in resistance to the development of infectious complications. Based on this evidence, the American Diabetes Association recommends screening patients with diabetes for PAD and measuring the ankle-brachial index every 5 years [13]. Arthropathy of arteries is 3 times more common in patients with diabetes. The percentage of occurrence in patients with diabetes who are over 50 years old is 29% [14,15].

According to the IDF (International Diabetes Federation), the prevalence of diabetes in adults (20–79 years old) is on average 5.1% (of which 90% is in the proportion of diabetes II) [16,17]. About 10% of elderly patients with diabetes have an ulcer or gangrene of the foot. In the structure of ulcers in diabetic foot syndrome, 48% are neuroischemic and 7% ischemic. Thus, 55% of ulcers in diabetic patients develop against the background of critical lower limb ischemia [18].

According to the international recommendations of TASC II, the frequency of critical lower limb ischemia is 500–1000 cases per 1 million population per year. In the structure of the incidence of critical ischemia of the lower extremities, the proportion of elderly and senile patients is 80% [19,20].

To date, there is a constant discussion of treatment methods for PAD: which method is best used in a particular case. The rapid development of the arsenal of interventional surgery does not detract from the results of open revascularization of the peripheral arteries. What method of revascularization is acceptable for a particular patient is still a pressing issue. There is a sufficient amount of research regarding the methods of treatment of peripheral arterial diseases, however, the issue of limb preservation, prevention of mortality, improvement of the quality of life in such patients remains insufficiently studied [21]. Prior to the publication of the directive of the American College of Cardiology / American Heart Association in 2011, there were no precise recommendations on the use of revascularization techniques. This publication referred to the Bypass versus Angioplasty in Severe Ischemia of the Leg (BASIL), a single-center, randomized study that showed similar results in patients with critical limb ischemia after endovascular and open surgery [22].

The 2007 Inter-Community Consensus Document for the Management of Patients with PAD (TASC II) and the 2012 National Institute of Health and Clinical Quality of the Kingdom of Great Britain (NICE) published recommendations on the diagnosis and treatment of peripheral arterial disease. However, the proposed recommendation does not provide sufficient data on the management of patients with PAD, with concomitant diabetes [23, 24].

Obliterating diseases of the lower limb arteries associated with diabetes, for the most part, have a lesion of the distal segments of the tibial arteries, which in turn requires shunting of the arteries of the rear foot, plantar artery and more distal posterior minor tibial artery [25]. Clinical manifestations of arterial lesions below the popliteal fossa are mostly manifested as critical lower limb ischemia than intermittent claudication. Infrapopliteal damage to arteries is more common in patients with diabetes and renal failure [26]. The caliber of the arteries is smaller than the arteries above the knee, and the lesion of the arteries is extensive [27]. The disease is characterized by media calcification or Mockenberg sclerosis, as a result of which the lumen of the vessel narrows, which is different from isolated atherosclerosis, in which the pathological process occurs in the intimal layer of the vessel [28]. Arteries below the knee have a greater involvement in diabetic patients. It should be noted that the incidence of trophic disorders of the lower limbs and life-threatening infections are more common in patients with diabetes [29,30].

According to the literature there is a sufficient amount of research that compares various treatment methods. So in a randomized clinical trial of BASIL, initiated by the UK, 452 patients with lesions of the lower limb arteries participated. In this study, two methods of treatment were compared: endovascular treatment, surgical treatment in patients with lesions of the infrainguinal arteries, where one third of the patients underwent shunting operations on the arteries of the lower leg and 62% of patients with balloon angioplasty of the superficial hip artery. Separately, there was no assessment of the results in the subgroup with the infra-popular

lesion of the arteries [31]. The worst result and the highest probability of high amputation is observed in patients with diabetes and with concomitant PAD [32]. Despite the constantly improving technique of minimally invasive endovascular procedures, bypass surgery, patients with PAD are still in demand [33].

Abd Moain Abu Dabrh MBBCh, MS together with co-authors conducted a systematic review on the topic: Distal bypass surgery against endovascular intervention for critical lower limb ischemia, including 9 studies, 3 of which are randomized clinical studies and 6 cohort studies. The conclusion of the review is that there is an identical effect on mortality and large amputations no matter what type of intervention was used. However, the primary patency when performing open surgery is higher. But, further research is needed with the inclusion of additional endpoints [34]. Endovascular interventions are considered safer in terms of morbidity and mortality, but the risk of failure of the interventional procedure may be higher compared to distal bypass surgery [35]. The Inter-Community Transatlantic Consensus Document (TASC II) recommends arterial revascularization as the most appropriate treatment option, but the method of revascularization remains debatable [36].

Nasser M. Malyar and co-authors, in their study, evaluated the immediate and long-term results in patients with diabetes complicated by a lesion in the lower limb arterial pool and a diabetic foot in Germany. The authors divided patients, the number of which reached up to 40,335, into 3 groups: patients with diabetic foot, patients with diabetes and PAD, patients with PAD without diabetes. Greater amputation was more common in patients with diabetic foot in comparison with the group of diabetes in combination with PAD and isolated lesions of the lower limb arteries (31.9% versus 11.1% versus 6%). Also in the question of 4-year survival (57.4%, 60.8% and 70.0%) and limb preservation (45.4%, 74.4% and 86.5%), a group of patients with diabetic foot and Diabetes, combined with damage to the arteries of the lower extremities, had worse results. In conclusion, the authors summarized the need to study the factors influencing the prognosis in patients with diabetes and PAD [37].

In a study conducted by Yisu Gu and co-authors, the results of conservative treatment and various types of revascularization were assessed in patients with diabetes, where there was no significant difference in limb preservation after 1 year of follow-up. But, in the future, after 5 years of observation, in patients after revascularization, the chances of maintaining the limb were higher, the mortality rate was lower compared to the group where the drug therapy was carried out [38].

D. W. Good and co-authors conducted a study where 24 patients, 19 of whom suffered from diabetes, underwent popliteal pedal autovenous shunting. For 5 years, an observation was conducted in which the frequency of limb preservation reached 81.8% after 1, 3, 5 years. All 3 amputations were performed in the first 3 months. In conclusion, the authors consider distal shunting - popliteal-pedal autovenous shunting as an effective treatment. However, a randomized study is required, where endovascular treatment would be compared [39].

Lee MS et al. Evaluated the clinical outcome in patients with PAD with and without diabetes who underwent balloon angioplasty. After two years of observation, it was revealed that the frequency of restenoses and amputations is higher in the group of patients with diabetes [40].

Discussion

It is worth noting that diabetes remains a dynamically developing disease that can make its own adjustments to the patient's quality of life. Complications arising from the presence of diabetes, in particular, the PAD of interest to us, significantly aggravates the course of the disease, in comparison with the lesion of the arteries of the lower extremities in isolation from atherosclerosis. The fact that diabetes is one of the main factors of non-traumatic amputations of the lower extremities encourages us to search for optimal treatment methods to save the limb, reduce deaths and improve the quality of life of patients. Currently, there are two main methods of treatment for PAD: open surgery and interventional surgery. The end point of the existing methods in stopping the signs of ischemia, by restoring blood circulation in the basin of the lower extremities. The arsenal for endovascular interventions is inexorably increasing, which expands the field of activity for revascularization of the affected arteries. But, open surgery also does not stand still. If earlier, the lesion of the arteries immediately under trifurcation was considered unacceptable for the reconstruction of the arterial bed, and treatment was limited to palliative or drug therapy, today the revascularization of the arteries of the leg and foot by a surgical method has become possible. Based on the above, there remains an open question about the best way to treat PAD, with concomitant diabetes. In connection with the continuity of a particular school, the opinions of many authors are divided. According to the classification of TASC II, A, B in lesions of the infra-juvial arteries, among the authors there is an agreement on the method of revascularization. But, with TASC C, D, the method of revascularization remains insufficiently studied.

References

1. Дедов, И.И. Сахарный диабет в пожилом возрасте: диагностика, клиника, лечение. Практическое руководство для врачей / И.И. Дедов, М.В. Шестакова. – Москва. – 2011. – С. 310;
2. American Diabetes Association, Standards of medical care in diabetes, 2006;
3. Пузин С. Н., Балаболкин М. И., Целина М. Э. Инвалидность, медико-социальная экспертиза и реабилитация при эндокринной патологии. – М., 2003.
4. Маслова О.В., Сунцов Ю.И., Эпидемиология сахарного диабета и микрососудистых осложнений, 2011
5. Criqui M. Peripheral arterial disease: epidemiological aspects//Vascular. Med. 2001. #6 (Suppl. 1), P.3 – 7].
6. Thefeld W. Prevalence of diabetes mellitus in the adult German population. Gesundheitswesen. 1999; 61: 85–9. 2.
7. Shaw JE, Sicree RA, Zimmet PZ. Global estimates of the prevalence of diabetes for 2010 and 2030. Diabetes Res Clin Pract 2010;87(1):4–14.
8. Newman AB, Siscovick DS, Manolio TA, et al. Ankle-arm index as a marker of atherosclerosis in the Cardiovascular Health Study. Cardiovascular Heart Study (CHS) Collaborative Research Group. Circulation 1993;88:837–45.
9. Marso SP, Hiatt WR. Peripheral arterial disease in patients with diabetes. J Am Coll Cardiol. 2006;47(5):921–9 (Review).
10. Forbang NI, MacDermott MM, Liao Y. Ix JH, Allison M, Liu K, Tian L,Evans N, Criqui MH. Associations of diabetes mellitus and other cardiovascular disease risk factors with decline in the ancle brachial index. Vasc Med 2014;19: 465-472 [PMID: 25358555].
11. American Diabetes Association. Peripheral arterial disease in people with diabetes. Diabets care 2003; 26: 3333-3341[PMID: 14633825 DOI: 10.2337/diacare. 26.12.3333].
12. Fowkes FG, Rudan D, Rudan I, et al. Comparison of global estimates of prevalence and risk factors for peripheral artery disease in 2000 and 2010: a systematic review and analysis. Lancet. 2013; 382:1329–40.
13. ADA. Peripheral arterial disease in people with diabetes. Diabetes Care 2003;26(12):3333e3341.
14. Selvin E, Erlinger TP. Prevalence of and risk factors for peripheral arterial disease in the United States: results from the National Health and Nutrition Examination Survey, 1999-2000. Circulation 2004;110:738-43;
15. Hirsch A, Criqui M, Treat-Jacobson D, Regensteiner J, Creager M, Olin J, et al. Peripheral arterial disease detection, awareness, and treatment in primary care. JAMA 2001;286: 1317-24.
16. Dunstan D.W., Zimmet P.Z., Welborn T.A., De Courten M.P., Cameron A.J., Sicree R.A., Dwyer T., Colagiuri S., Jolley D., Knuiman M., Atkins R., Shaw J.E. The rising prevalence of diabetes and impaired glucose tolerance: the Australian Diabetes, Obesity and Lifestyle Study. Diabetes Care. 2002; 25: 829–34. 4.
17. Gregg E.W., Cadwell B.L., Cheng Y.J. Trends in the prevalence and ratio of diagnosed to undiagnosed diabetes according to obesity levels in the U.S. Diabetes Care. 2004; 27 (12): 2806–12).
18. Бокерия Л.А., Темрезов М.Б., Коваленко В.И., Борсов М.Х., Булгаров Р.С., Альбориев И.Н. Актуальные проблемы хирургического лечения больных с критической ишемией нижних конечностей – пути решения (состояние проблемы). Анналы хирургии. 2011; 1: 5–9.
19. Inter-Society Consensus for the Management of Peripheral Arterial Disease (TASC II), 2007.
20. Дуданов И.П., Карпов А. В., Капутин М.Ю. Комплексное лечение атеросклеротических поражений абдоминального сегмента аорты, периферических артерий с критической ишемией нижних конечностей у больных преклонного и старческого возраста. Медицинский академический журнал. 2007; 7 (1). 166–72.).
21. Jaff MR, Cahill KE,Yu AP, et al. Clinical outcomes and medical care costs among Medicare beneficiaries receiving therapy for peripheral arterial disease. Ann Vasc Surg 2010; 24: 577-87.
22. Adam DJ, Beard JD, Cleveland T,et al. Bypass versus angioplasty in severe ischaemia of the leg (BASIL): multicentre, randomised controlled trial. Lancet 2005;366:1925-34
23. Norgren L, Hiatt WR, Dormandy JA, Nehler MR, Harris KA, Fowkes FG. Inter-Society Consensus for the Management of Peripheral Arterial Disease (TASC II). Eur J Vasc Endovasc Surg. 2013;33:S1–75, National Institute for Clinical and Healthcare Excellence. Lower limb peripheral arterial disease (CG147). 2012. http://guidance.nice.org.uk/ CG147. Accessed Jul 20, 2015.
24. National Institute for Clinical and Healthcare Excellence. Diabetic foot problems. Inpatient management of diabetic foot problems. CG119. 2011. http://www.nice.org.uk/guidance/CG119. Accessed Jul 20, 2015.
25. Sarah P. Pradka, Vahram Ornekian, and Cameron M. Akbari, Surgical Revascularization of Chronic Limb Ischemia. Springer International Publishing Switzerland 2017. R.S. Dieter et al. (eds.), Critical Limb Ischemia, DOI 10.1007/978-3-319-31991-9_36.
26. Peregrin JH, Koznar B, Kovac J (2010) PTA of infrapopliteal arteries: long-term clinical follow-up and analysis of factors influencing clinical outcome. Cardiovasc Intervent Radiol 33: 720–725.
27. Graziani L, Silvestro A, Bertone V et al (2007) Vascular involvement in diabetic subjects with ischemic foot ulcer: a new morphologic categorization of disease severity. Eur J Vasc Endovasc Surg 33:453–460.
28. Drueke TB (2008) Arterial intima and media calcification: distinct entities with different pathogenesis or all the same? Clin J Am Soc Nephrol 3:1583–1584.
29. DeRubertis BG, Pierce M, Ryer EJ, Trocciola S, Kent KC, Faries PL. Reduced primary patency rate in diabetic patients after percutaneous intervention results from more frequent presentation with limb-threatening ischemia. J Vasc Surg 2008;47:101-8;
30. Prompers L, Schaper N, Apelqvist J, Edmonds M, Jude E, Mauricio D, et al. Prediction of outcome in individuals with diabetic foot ulcers: focus on the differences between individuals with and without

peripheral arterial disease. The EURODIALE Study. Diabetologia 2008;51:747-55.
31. Adam DJ, Beard JD, Cleveland T et al (2005) Bypass versus angioplasty in severe ischaemia of the leg (BASIL): multicenter, randomized controlled trial. Lancet 366(9501):1925–1934
32. Jude EB, Oyibo SO, Chalmers N, Boulton AJ (2001) Peripheral arterial disease in diabetic and nondiabetic patients: a comparison of severity and outcome. Diabetes Care 24:1433–1437.
33. Society for Vascular Surgery Lower Extremity Guidelines Writing Group, Conte MS, Pomposelli FB, Clair DG, Geraghty PJ, McKinsey JF, et al. Society for Vascular Surgery practice guidelines for atherosclerotic occlusive disease of the lower extremities: management of asymptomatic dis- ease and claudication. J Vasc Surg 2015;61(Suppl):2S-41S.
34. Abd Moain Abu Dabrh, MBBCh, MS, Mark W. Steffen, MD, MPH, Noor Asi, MD,Chaitanya Undavalli, MBBS, Zhen Wang, PhD, Mohamed B. Elamin, MD, Michael S. Conte, MD, and Mohammad Hassan Murad, MD, MPH, Rochester, Minn; and San Francisco, Calif. Bypass surgery versus endovascular interventions in severe or critical limb ischemia.
35. Arain SA, White CJ. Endovascular therapy for critical limb ischemia. Vasc Med 2008;13:267-79).
36. Rooke TW, Hirsch AT, Misra S, Sidawy AN, Beckman JA, Findeiss LK, et al. 2011 ACCF/AHA Focused Update of the Guideline for the Management of Patients With Peripheral Artery Disease (updating the 2005 guideline): a report of the American College of Cardiology Foundation/American Heart Association Task Force on Practice Guidelines. J Am Coll Cardiol 2011;58:2020-45.
37. Nasser M. Malyar, Eva Freisinger, Matthias Meyborg, Florian Lьders, Katrin Gebauer, Holger Reinecke, Holger Lawall. Amputations and mortality in in-hospital treated patients with peripheral artery disease and diabetic foot syndrome// Journal of Diabetes and Its Complications 30 (2016) 1117–1122
38. Yisu Gu. Chatchai Kokar. Catherine Gooday. Darren Morrow. Ketan Dhatariya// Diabetes Ther (2015) 6:481–493 DOI 10.1007/s13300-015-0131-1.
39. D. W. Good, H. Al Chalabi , F. Hameed, B. Egan, S. Tierney, T. M. Feeley. Popliteo–pedal bypass surgery for critical limb ischemia// Ir J Med Sci (2011) 180:829–835 DOI 10.1007/s11845-011-0740-2.
40. Lee MS, Rha SW, Han SK, Choi BG, Choi SY, Ali J, Xu S, Ngow HA, Lee JJ, Lee KN, Kim JB, Lee S, Na JO, Choi CU, Lim HE, Kim JW, Kim EJ, Park CG, Seo HS, Kong J, Oh DJ. Comparison of diabetic and nondiabetic patients undergoing endovascular revascularization for peripheral arterial disease// J Invasive Cardiol. 2015 Mar;27(3):167-71.

INTRAPERITONEAL COMPLETE RUPTURE OF BLADDER CUPULA, COMPLICATED BY TEN-DAYS URINE PERITONITIS. CASE FROM PRACTICE

УДК 616.62:616.381-002-031.81-089
МРНТИ 76.29.29, 76.29.39

Baizharkinova A.B., Kurmangaliev O.M., Taishibaev K.R.

West Kazakhstan State Medical University named after M. Ospanov, Aktobe, Kazakhstan

Abstract

A rare case is given in our article with 10 days old closed injury with isolated full intraperitoneal rupture of the bladder dome. In the surgical department of our hospital, with bladder ruptures, which are given according to literary data, but have met with such a case first. At the insistence of a linear medical assistant after 10 days, the patient was brought by train to us with a diagnosis cirrhosis, ascites. The intraperitoneal rupture of the bladder, complicated by 10 days of urinary peri- tonit, which is not found in the available literature. At the first catheterization the patient is exposed diagnosis.

Due to the severity of the patient's condition, the therapists showed vigilance and after consulting Stov in the intensive care unit held preoperative preparation, operation: rehabilitation of the abdominal cavity with drainage, suturing the wound of the dome of the bladder with the imposition of epicystostomy, postoperative care and adequate treatment, based on practical experience, led to a positive outcome. the results of surgical treatment, the patient lives, now on a well-deserved rest.

ABOUT THE AUTHORS

Bayzharkinova Ayash Boldybayevna *Surgeon of the highest category, к.м.н.,Ph.D., professor of RAE, member of the expert council, consultant on LCE, trainer*

Kurmangaliev Oleg Maratovich *Doctor of Medicine, Professor of the Department of Surgical Diseases with Urology, MKTU named after Marat Ospanov*

Taishibaev Kairat Ryszhanovich*, assistant of the department of general surgery.*

Keywords
bladder, trauma, peritonitis

Онкүндік несеп перитонитімен асқынған қуықтың күмбезінің ішпердеішілік толық зақымдануы. Клиникалық оқиға

Байжаркинова А.Б., Курмангалиев О.М., Тайшибаев К.Р.
М.Оспанов атындағы Батыс Қазақстан мемлекеттік медициналық университеті, Актобе, Казахстан

Аңдатпа

Мақалада қуық күмбезінің оқшауланған толық ішпердеішілік жабық жарақаты бар сирек жағдай келтірілген.

Біздің аурухананың хирургиялық бөлімінде қуық жаралары бар операциялар жасалды, олар әдеби мәліметтер бойынша жасалады, бірақ бұл бірінші оқиға.

Фельдшердің талабы бойынша 10 күннен кейін пациент бізге пойызбен «бауыр циррозы, асцит» диагнозымен жеткізілді.

Біз қолда бар әдебиеттерде таппаған 10 күндік несеп перитонитпен асқынған қуықтың ішперде ішілік жарылуы.

Катетеризация кезінде науқасқа диагноз қойылды. Науқастың жағдайының ауырлығына байланысты терапевттер қырағылық танытып, маманмен кеңескеннен кейін интенсивті терапия бөлімінде операция алдындағы дайындық жүргізілді. Операция: құрсақ қуысын дренажбен қалпына келтіру, қуық күмбезінің жарасын эпицистостомиямен тігу, операциядан кейінгі күтім және тиісті ем, тәжірибеге сүйене отырып, оң нәтижеге әкелді.

Хирургиялық емнің алщақ нәтижелері бойынша пациент қазір бірқалыпты лайықты демалыста.

АВТОРЛАР ТУРАЛЫ

Байжаркинова Аяш Болдыбайқызы *– жоғары санатты хирург, м.ғ.к., профессор, сараптамалық кеңестің мүшесі, теміржол ауруханасы бойынша ЛЭК кеңесшісі*

Құрманғалиев Олег Маратұлы *– медицина ғылымдарының докторы, Марат Оспанов атындағы БҚММУ-ң урология хирургиялық аурулар кафедрасының профессоры*

Тайшыбаев Қайрат Рысжанұлы *– теміржол ауруханасының жалпы хирургия кафедрасының ассистенті*

Түйін сөздер
қуық, жарақат, перитонит

Внутриперитонеальное полное повреждение купола мочевого пузыря, осложненное десятидневным мочевым перитонитом. Случай из практики

ОБ АВТОРАХ

Байжаркинова Аяш Болдыбаевна *врач-хирург высшей категории,к.м.н., Ph.D.,профессор РАЕ, член экспертного совета, консультант по ЛХЭ ж.д .б-цы*

Курмангалиев Олег Маратович *доктор медицины, профессор кафедры хирургических болезней с урологией ЗКГМУ им Марата Оспанова*

Тайшибаев Кайрат Рысжанович, *ассистент кафедры общей хирургии ж.д. б-цы*

Байжаркинова А.Б., Курмангалиев О.М., Тайшибаев К.Р.
Западно-Казахстанский государственный медицинский университет имени М. Оспанова, Актобе, Казахстан

Ключевые слова
мочевой пузырь, травма, перитонит

Аннотация

В нашей статье приведен редкий случай 10 дневной закрытой травмы с изолированным полными внутрибрюшинным разрывом купола мочевого пузыря. В хирургическом отделении больницы оперирован пациент с разрывами мочевого пузыря. По настоянию линейного фельдшера через 10 дней больной привезен на поезде к нам с диагнозом: «цирроз печени, асцит». Внутрибрюшинный разрыв мочевого пузыря, осложненный 10 дневным мочевым перитонитом, о котором в доступной литературе информация нами не найдена. При первой катетеризации больному выставлен диагноз. Из-за тяжести состояния больного терапевты проявили бдительность и после консультации специалистов в отделение реанимации проведена предоперационная подготовка. Операция: санация брюшной полости с дренированием, ушивание раны купола мочевого пузыря с наложением эпицистостомии, послеоперационный уход и адекватное лечение, привели к положительному исходу. По отдаленным результатам хирургического лечения пациент жив, сейчас на заслуженном отдыхе.

Urgency

During the recent 50 years of practice in surgical department of railroad hospital among operated patients with bladder traumas with the following complications: 10-days urine peritonitis, it has been the first case in which the patient was saved. According to literature data, even in case of isolated damage of bladder lethality equaled 4,4 %. During the recent 10 years articles, devoted to ruptures of bladder with such complications, have not been published.

The main cause of bladder ruptures is trauma. V.A. Klyuzhev (2001) illustrates that bladder injuries and urine-discharging ways are very rare in peaceful times, it is defined by its anatomic location in encirclement of pelvis bones. However, in case of anthropogenic traumas bladder damages grew by 7 %, and in case of traffic accidents bladder injuries take place in 86–90 % of events, among those 70–80 % of them are hazardous for life, and in combined traumas bladder ruptures form 25,7 %. The Cause of rupture is a direct injury along the lower part of stomach: a kick, hit by a moving transport, fall from a certain height, overrun by an automobile, etc. More rare are indirect injuries: a strike to sacrum, buttock, thigh.

Works of such authors as (T.A. Revenko, 1981; P.S. Jalilov, 1985; S.B. Petrov, 1999; Tiquert R.et al., 2000) show us that bladder rupture depends not only on a hit, but also the speed of traumatic force. In case of alcohol intoxication bladder rupture takes place much more frequently and grows two times (I.G. Ryabtsev, 1975; N.A. Shor, A.A. Chichetka, 1989), especially among men of able-to-work age. A cause of a complete rupture of bladder in case of an accidental trauma among the injured in condition of alcohol intoxication is lack of protective senses. Intraperitoneal rupture of bladder can happen to a person with an overfilled bladder in case of an accidental downfall under the own weight of the injured person or in case of a hit to the stomach with a dull object. Practical significance has the division of all bladder damages into extraperitoneal and intraperitoneal. Depending on the mechanism of trauma damage of bladder can be, as mentioned above, complete and incomplete. In case of incomplete damages partial rupture of bladder wall takes place: mucous membrane, sometimes mucous membrane and muscle tissue with preservation of wholeness in serous cover. On the contrary, in case fractions of pelvis bones are introduced from external environment, rupture of advention and part of muscle tissue takes place with preservation of wholeness in mucous membrane. The authors claim that incomplete ruptures can further transform into complete due to overflow of bladder with urine and sharp increase in intra-bladder pressure. Intraperitoneal fractures usually happen with fractures of pelvis bones, the mechanic of such rupture is basically defined by traction of pelvis ring at the moment of fracture with an overtension in ligamentous apparatus of bladder. As a result, rupture of bladder wall with rupture of ligaments takes place. More rarely bladder rupture happens due to a damage, caused by bone frac-

tions of pelvis bones. As a rule, intraperitoneal ruptures of bladder aren't succeeded by fractures of pelvis bones, as the main part in the mechanism of trauma is played by hydraulic blow in an overflown bladder.

In his "Guide on urology" of 1998, academy member N.A. Lopatkin illustrates location of bladder in small pelvis, and its volume equals 400-500 ml. In case of overflow of its volume increases hydrostatic pressure, and bladder walls become thin. The thinner bladder wall is due to a chronic urine delay, the greater is atrophy of bladder muscles and easier is rupture. That is why bladder ruptures are more frequent in case of senile atrophy of bladder, prostate adenoma, certain pathologies of bladder (diverticulas, tubercular ulcers, cancer, etc.).

A weak point and mobile part is cupula (top or bottom) of bladder, in this place rupture takes place in 35 % of cases, and it happens on bladder wall in 42 % of events. In peaceful times a combined trauma with damage of other internal organs leads to heavy complications that result in death of patient, death rate equals 20 %. During war death rate equals 4,4 % in case of isolated damage of bladder.

Of all intraperitoneal injuries bladder rupture among mature population happens in 5–12 % of cases, and in 4,4–11,5 % of cases – among children. Bladder traumas are divided into open injuries (12–33 %) and closed traumas (67–88 %), penetrating, non-penetrating, intraperitoneal, extraperitoneal, complete and incomplete damages of bladder. As in case of "non-complicated" form of trauma ruptures usually happen at the top and back wall, they are mostly intraperitoneal, in other words, do not lead to ruptures of other regions of urine-discharging ways or organs of stomach cavity.

Among all patients who experienced surgery from traumatic damages of stomach organs, bladder traumas form 2 % of cases.

Intraperitoneal complete ruptures of bladder happen in 25 % of cases along sanital or longitudinal direction, can be single or multiple and have no definite shape. In case a rupture happens in sanital direction, bleeding is almost absent, the reason of that is lack of large vessels in this area, and small ones contract quickly in tissues of bladder. In case of intraperitoneal rupture concentration of urine increases as it is absorbed by stomach walls and internal organs, at the same time, protein exchange is disturbed, chemical reaction takes place, it causes aseptic peritonitis, in case of secondary infection it transforms into pus peritonitis. Such kind of peritonitis leads to death of patient in case medical assistance is not provided to them urgently. Complete and incomplete ruptures of bladder peritoneal clinic symptoms might not display immediately. In case of intraperitoneal ruptures of bladder signs of peritonitis develop in 10–12 hours since the moment of trauma. Signs of urine intoxication and urosepsis that are revealed on days 2–3 after trauma are also lethal unless an urgent surgery is carried out.

Extraperitoneal rupture is observed among patients with fractures of pelvis bones in 55–57 % of cases, among those 36–39 % are closed intraperitoneal ruptures, and 6 % are combined type of traumas. No less heavy extraperitoneal ruptures are complicated by fractures of pelvis bones and heavy shock, from which is often hard to remove. Nitrous slag is accumulated, proteins break down, sodium of potassium, chlorides, organic acids increase in their volume, acidosis emerges. Water-salt exchange is disturbed. As a result of nitrous intoxication uraemia grows. A patient suffers from weakness, sleepiness, vomiting, diarrhea, edema, short breath, headaches, skin itching, memory loss, ammonia breath.

After three days of urine peritonitis nephritic deficiency takes place. Tongue becomes dry, the patient is thirsty, they feel sickness, urea and creatine concentration in blood samples increases up to 100–200 and 12–15 mg/ml. rupture of bladder usually happens in longitudinal direction as longitudinal muscles of detrusor are significantly more solid than transversal ones. Bladder damages in case of fractures, on the contrary, often create holes of incorrect shape.

Combined ruptures of bladder happen in case of vast injuries, compression of pelvis ring, and bladder overflow. In case there is complicated damage there is no clear localization of rupture, therefore, ruptures can be intra- and extraperitoneal, though the latter are more common. A special form of ruptures is damage that some authors refer to bladder damage, and others – to damage of urethra. We speak of disconnection between the bladder and urethra.

According to bibliographic data, iatrogenic damage of bladder can happen in 0,23–0,28 % of gynaecological surgeries, in other cases iatrogenic trauma happens in 30 % of cases. In case iatrogenic damage of bladder happens during surgery, it is determined faster than other damages of urinal-discharge channels.

Demonstrative medicine is found upon cystoscopy, retrograde cystography, emunctory urography (cardiotrust, venographin, solution of Sergosin, 2- or 3-atomic X-ray-contrast liquids), standard radiography of computer tomography.; mostly R-gram of pelvis bones, for example, in case of determination of its fractures, can suggest a conclusion of extraperitoneal rupture. In about 60 % of cases damage of bladder, cause by counterhit, is observed in the area across place of fracture and near it. Extraperitoneal ruptures of bladder form 54–56 % of all cases of bladder rupture. Combined intra- and extraperitoneal ruptures happen in 5–8 % of cases of bladder rupture. Usually they are determined during surgery. Intraperitoneal rupture of bladder is determined with ultrasound inspection and common introduction of catheter into bladder. Without operative intervention intraperitoneal bladder ruptures usually end in lethality.

Clinic

Closed injuries of bladder have no typical clinic image. During the first hours after the damage patients are usually shocked, though cases are described when even after a heavy trauma of bladder shock condition was not established and patients walked to the hospital. Shock, as well as pain is not a specific sign of bladder rupture and can be caused by damage in other organs.

The basic symptom of bladder rupture is deficiency of urinatiob that is expressed in ceasing act of urination, painful tenesmus in area of bladder and straight bowel. Blood drops discharge from urethra is not typical for bladder damage, as it can also be observed in case of urethra damage. Unlike rupture of bladder, ruptures of urethra usually cause significant urethrorragy and strong urges for urination.

In case of extraperitoneal ruptures pressure of urohaematoma in surrounding tissue causes a false urge for urination and discharge of blood drops from urethra. Palpation of stomach usually reveals sharp painfulness in the area of symphysis, above the bosom a painful blunting of percutory sound and tension of front stomach wall in its lower departments is defined. Direct-bowel or vaginal inspection through straight bowel or vagina reveals stagnation of tissues, and it indicates to urinal infiltration, on days 2–3 after trauma symptoms of urine leakages and urine infiltration into the bladder-surrounding tissue are observed. Emerge skin redness and edema of hypodermic fiber in the area of symphysis, lower part of stomach, scrotum, and penis. These areas become extremely sensitive under palpation and in motion. Urine infiltration can spread into the area of small pelvis, perineum, straight bowel, thighs. The developing urosepsis leads to death even in case of extraperitoneal damage. As damage of bladder is often combined with fractions of pelvis bones, symptoms of pelvis bone fracture are also observed in these cases. In case of any pelvis bone fracture it is necessary to establish if there is no simultaneous damage of bladder and urethra.

In cases of intraperitoneal rupture general symptoms of peritonitis can be observed. They are caused by discharge of urine into stomach cavity and stomach growth: pains in the area of bladder with irradiation into inguinal areas, tension of the front stomach wall. Lack of urine and presence of blood in urine during catheterization is caused by sealing of bladder wound by epiploon or bowel loops, besides, in certain cases condition of a patient might improve, and diagnostics will become complicated. An important symptom of bladder rupture in such cases is lack of definite limits of dullness for percussion sound.

In case of intraperitoneal rupture of bladder thenesmus and disuric sign might not be present if urine discharges freely into stomach cavity, and a sharp pain emerges along with urination disturbance and development of peritonitis. Condition of patients degenerates rapidly. The symptoms are: sickness, vomiting, delay of stool and gases. If much time passes since the moment of rupture, along with urine exudate liquid accumulates in stomach cavity. Bowel peristalsis is not heard through auscultation. Patient's temperature increases, tachycardia develops.

In case of open damage of bladder urine discharges from the wound, and the whole image is clear. Urine peritonitis happens together with secondary infection, signs of pus intoxication, the latter can result in abdominal sepsis, urosepsis, and poly-organ deficiency. In case the rupture is combines with pelvis bones fracture, intraperitoneal bleeding is possible. Late diagnostics can complicate treatment.

Diagnostics

Diagnosis of bladder damage is based upon the data of anamnesis, the described clinical symptoms, and hematuria in urine analysis. In order to confirm the diagnosis data of catheterization, cystoscopy, cystography, emunctory urography, and R-graph of pelvis bones is used. During

catheterization of bladder urine either does not discharge at all, or discharges as a thin stream with addition of blood. Sterile liquid, introduced into bladder through catheter, does not discharges back or discharges as a thin stream. In case of intraperitoneal rupture of bladder, after catheter is advanced deeper into it, a large amount of turbid bloody liquid (urine, blood, exudate from stomach cavity) can discharge unexpectedly. Cystoscopy is implemented for intraperitoneal rupture in rare cases when other methods of diagnostic aren't able to provide clear information, and can be applied only in for partial or small damages, when bladder can be filled for examination. Ultrasound examination produced a mistake in 10 % of cases. The leading part in diagnostics plays cystography: leakages of contract roentgen liquid outside of bladder are registered.

In verification of an open damage of bladder a great significance have probes with colorants (solution of indigocarmine-methylene blue) that confirm discharge of urine from the wound.

Treatment

According foreign scientists, only intraperitoneal ruptures require surgery, all other types of ruptures are treated conservatively. Of course, every problem of treatment is solved individually for a given patient, especially when there is a possibility to use modern medical technology.

A special feature of surgery for intraperitoneal rupture of bladder is that the damage can happen not only in bladder itself. Therefore, during laparotomy it is necessary to begin with revision of stomach organs and urination system. If less than 2 hours pass since the injury of bladder, and urine peritonitis has not yet happened, treatment can be limited to introduction of microirrigators for introduction of antibiotics, the wound is closed completely with placement of epicystoctomy. In case urine peritonitis has happened, drainages are left in 4 places for washing, 8-10 liter of sterile isotonic solution of natrium chloride are introduced through the higher drainages during post-surgical period, the washing liquid is discharged from stomach cavity through the lower drainages.

Conclusion

Our article presents a rare case of 10-days old closed trauma of bladder that was received by patient in alcoholic intoxication. On insistence of medical assistant the patient was delivered to therapeutic department of railroad hospital with diagnosis cirrhosis of liver, ascites. A simple method of examining the patient – catheterization of bladder established the diagnosis: rupture of bladder, urine peritonitis, intoxication. During the surgery a complete isolated intraperitoneal rupture of bladder cupula was established. Other pathologies of stomach cavity organs and pelvis bones were not registered. Post-surgical adequate treatment led the patient to a complete recovery of the patient.

During the period of 50 years of work in surgical department of our railroad hospital we have operated patients with different ruptures of bladder that were found in literature, but were actually faced with for the first time. Intraperitoneal complete rupture of bladder, complicated by 10-days urine peritonitis was not found in the accessible literature. Severity of the patient's condition was evaluated adequately by our specialists who even called specialists in for consultation. Guided by the practical experience, pre-surgical diagnostics of bladder damage, well-maintained pre-surgical preparation in reanimation department, and surgery itself: sanitation of stomach cavity with drainage, closure of bladder cupula wound with placement of epicystectomy, post-surgical treatment, and the corresponding adequate post-surgical treatment has led us to a positive result. According to the received data, after the surgery the patient continued working until retirement and now is having a well-deserved rest.

Deduction

An article in this rare case with a 10-day prescription of closed injury with isolated full intraperitoneal rupture of the bladder dome. In the surgical ward of our hospital operated with bladder ruptures, which are listed according to the literature, but with the opportunity to meet for the first time. At the insistence of linear paramedic after 10 days the patient was brought to us on the train with a diagnosis of cirrhosis, ascites. Intraperitoneal rupture of the bladder, complicated urinary peritonitis day 10, which in the available literature we have not found. When the first patient diagnosed Lab. Because of the severity of the patient's physicians to be vigilant and after consulting experts in the ICU preoperative preparation, operation: reorganization of the abdominal cavity with drainage, wound closure of the bladder dome overlay epitsistostomii, postoperative care and adequate treatment, based on practical experience, has led to a positive outcome. On long-term results of surgical treatment of the patient lives, now in retirement.

References

1. Borisov, V.V. Features of diagnosis of damage to the bladder during gynecological operations / V.V. Borisov, A.I. Ishchenko, H.M. Ali // X Ross, Congress of Urology. M., 2002. - p. 524-525.
2. Bratchikov, O.I. Features of surgical treatment of extraperitoneal and intraperitoneal ruptures of the bladder / O.I. Bratchikov, E.A. Shumakov // X Ross, Congress of Urology. M., 2002. - p. 526-527.
3. Voino-Yasenetsky, A. M. Peritonitis with intraperitoneal ruptures of the bladder / A. M. Voino-Yasenetsky // Nauch. tr. Khabarovsk honey. in-t. 1981. - pp. 109-112.
4. Kamantseva, S.M. Trauma of the genitourinary system / S.M. Kamantsev, N.I. Frolov, Yu.M. Kramzin // X Ross, Congress of Urology. M., 2002. - p. 566-567.
5. Korovin, Yu.I. Rare bladder injury / Yu.I. Korovin, N.I. Dmitriev, V.V. Astafiev // Bulletin of Surgery. 2000. - № 6. - p. 76-77.
6. Skorikov, I.I. Isolated bladder injuries in emergency urological practice / I.I. Skorikov, A.N. Shechenko, Mahmoud Tarek // X Ross, Congress of Urology. M., 2002. - p. 611-612.
7. Strotsky, A.V. Injuries of the genitourinary system in the practice of the urology department of an emergency hospital / A.V. Strotsky, V.N. Polkhovsky // X Ross, congress of urologists. M., 2002. - p. 620
8. Chiou-Tan, F.Y. Lumbosacral plexopthy in gunshot wounds and motor vehicle accidents / F.Y. Chiou-Tan, K. Jr. Kemp, M. Elfenbaum // Am. J. Phys. Med. Rehabil. 2001. - Vol. 80, № 4. - P. 280 - 285.
9. Dreitlein, D.A. Genitourinary trauma / D.A. Dreitlein, S. Suner, J. Basler // Emerg. Med. Clin. North. Am. 2007 -19:569.
10. Lynch, T.H. EAU Guidelines on Urological Trauma / T.H. Lynch, L. Martinez-Pineiro, S. Plas // J.European Urology. 2011. - Vol. 47. - N 47. - P. 6-7.
11. Morey, A.F. Bladder rupture after blunt trauma: guidelines for diagnostic imaging / A.F. Morey, A.J. Iverson, A. Swan// J. Trauma, 2012.-51: 683. .
12. Salzano, A. Segni con Tomografia Cjmputerizzata nel coinvolgimento della pelvi nelle ferite da arma da fuoco. Experienza personale / A. Salzano, V. Nocera, A. De-Rosa// Radiol. Med. (Torino) 2013. - Vol. 100, № 5.-P. 310-313.
13. Baizharkinova A.B INTRAPERITONEAL COMPLETE RUPTURE OF BLADDER CUPULA (BOTTOM), COMPLICATED BY TEN-DAYS URINE PERITONITIS The work is submitted to the International Scientific Conference “Innovative medical technologies”, France (Paris), March 18–25, 2015, came to the editorial office on 15.02.2015. European Journal of Natural History-2015, №2,5-9 Scientific journal | ISSN 2073-4972

RECURRENT RENAL CELL CARCINOMA OF SOLITARY KIDNEY: RENAL SPARING SURGERY. CLINICAL CASE

МРНТИ 76.29.43

Ibragimov R.P., Madadov I.K., Syrymov Zh.M., Belgibaev E.B., Baiguissova D.Z., Syrymova A.K.
National Scientific Center of Surgery named after A.N. Syzganov, Almaty, Kazakhstan.

Abstract

57 years old female was admitted to the hospital absolutely asymptomatic. Previously on ultrasound investigation 3 renal neoplasms were detected. Five years ago patient underwent nephrectomy on the left for renal cell carcinoma. Preoperatively laboratory tests were in reference range.

Patient underwent renal sparing surgery - all neoplasms were fully excised. After each excision arterial circulation was temporarily restored for up to 10 min. We call this - "start-break" technique. Also after excision it was better to assess hemostasis. Total warm ischemic time was 18 min. Total blood loss was 200ml. Patient's condition was relatively stable and did not necessitate hemodialysis. She was discharged on 11th postop day.

Renal cell carcinoma of the solitary kidney presents a great challenge either for the surgeons or patients, because it depends on what is the main purpose of treatment, because organ sparing surgery and radical surgery have mostly different outcomes in long-term period. The decision is made according to the clinical data, patient's preference, safety and good quality of life for patient. But organ sparing surgery bears the risk of recurrence more than the radical surgery. So these aspects must be considered before the informed consent is taken.

ABOUT THE AUTHORS

R.P. Ibragimov *– urologist, transplant-surgeon, head of kidney transplantation, urology and nephrology department, scientific manager. (rava747@mail.ru 87017472070)*

I.K. Madadov *– urologist, kidney transplantation, urology and nephrology department (dominic89@mail.ru 87478397110)*

Zh.M. Syrymov *- urologist, kidney transplantation, urology and nephrology department (syrymov89@mail.ru 87072727002)*

E.B.Belgibaev *- urologist, kidney transplantation, urology and nephrology department (dr_beb@mail.ru 87759776773)*

D. Z. Baiguissova *– radiologist, radiology department (dina_gallyamova@mail.ru. 87017719371).*

A.K. Syrymova *– resident, radiology department (aidana.syrymova@mail.ru, 87072727001).*

Keywords
renal cell carcinoma, solitary kidney, excision, ischemic time.

Жалғыз қалған оң бүйректің рецидивті бүйрек-жасушалық карциномасы: орган сақтау отасы

Ибрагимов Р.П., Мададов И.К., Сырымов Ж.М., Белгибаев Е.Б., Байгуисова Д.З., Сырымова А.К.
А.Н. Сызганов атындағы Ұлттық Ғылыми Хирургия, Алматы, Қазақстан

Аңдатпа

57 жасар науқас ауруханаға түскен кезде оң бүйрегінде ультрадыбыстық зерттеу бойынша 3 ісік табылған және науқаста еш қандай клиникалық симптом болмаған. Анамнезі бойынша науқасқа 5 жыл бұрын сол бүйректін бүйрек-жасушалық қатерлі ісігі себебінен нефрэктомия отасы жасалынған. Келіп түскен кезінде лабораториялық көрсеткіштер дұрыс болған.

Науқасқа орган сақтау отасы жасалынды – ісіктердің барлығы толығымен кесіп алынды. Әр резекциядан кейін артериальді қан айналымы уақытша 10 минутке дейін қалпына келтірілді. Бұл техниканы «старт-пауза» техникасы деп атадық. Осымен гемостаздын бақылауы жақсы болды. Жылу ишемиясының жалпы уақыты 18 минут болды. Жалпы қан кетуі 200 мл болды. Науқастың жағдайы бір қалыпты болды және гемодиализ қажет болмады. Науқас отадан кейінгі 11 тәулікте үйге шығарылды.

Жалғыз қалған бүйректің бүйрек-жасушалық карциномасының емі дәрігерге де наукасқа да өте қиын тандау болып саналады, өйткені барлығы қойылған басты мақсатқа байланысты – орган сақтау отасы немесе радикальді ота жасау, екі жағдайда да ұзақ мерзімде әртүрлі нәтижелері болады.

АВТОРЛАР ТУРАЛЫ

Р. П. Ибрагимов *– уролог-трансплантолог дәрігері, бүйрек трансплантациясы, урология және нефрология бөлімшесінің меңгерушісі, ғылыми жетекші (rava747@mail.ru 87017472070)*

И.К. Мададов *- уролог дәрігері, бүйрек трансплантациясы, урология және нефрология бөлімшесі, кіші ғылыми қызметкер (dominic89@mail.ru 87478397110)*

Ж.М. Сырымов *- уролог дәрігері, бүйрек трансплантациясы, урология және нефрология бөлімшесі (syrymov89@mail.ru 87072727002)*

Е.Б. Белгибаев *- уролог дәрігері, бүйрек трансплантациясы, урология және нефрология бөлімшесі (dr_beb@mail.ru 87759776773)*

Д. З. Байгуисова *– сәулелі диагностика дәрігері, сәулелі диагностика бөлімшесінің меңгерушісі (dina_gallyamova@mail.ru. 87017719371).*

А.К. Сырымова *– резидент-дәрігері, сәулелі диагностика бөлімшесі (aidana.syrymova@mail.ru, 87072727001).*

Түйін сөздер
бүйрек-жасушалық карцинома, жалғыз қалған бүрек, резекция, ишемия уақыты.

Рецидивная почечно-клеточная карцинома единственной оставшейся правой почки: органосохраняющая операция. Клинический случай

Ибрагимов Р.П., Мададов И.К., Сырымов Ж.М., Белгибаев Е.Б., Байгуисова Д.З., Сырымова А.К.
Национальный Научный центр хирургии им. А.Н. Сызганова, Алматы, Казахстан

ОБ АВТОРАХ

Р. П. Ибрагимов *– уролог-трансплантолог, заведующий отделением трансплантации почек, урологии и нефрологии, руководитель исследования (rava747@mail.ru 87017472070)*

Д.А. Исаев *- уролог, отделение трансплантации почек, урологии и нефрологии (dzhanibek@issayev.com 87477218977)*

И.К. Мададов *- уролог, отделение трансплантации почек, урологии и нефрологии, младший научный сотрудник (dominic89@mail.ru 87478397110)*

Ж.М. Сырымов *- уролог, отделение трансплантации почек, урологии и нефрологии, (syrymov89@mail.ru 87072727002)*

Е.Б. Белгибаев *- уролог, отделение трансплантации почек, урологии и нефрологии (dr_beb@mail.ru 87759776773)*

Д. З. Байгуисова *– врач лучевой диагностики, заведующий отделением лучевой диагностики (dina_gallyamova@mail.ru. 87017719371).*

А.К.Сырымова *– врач-резидент, отделение лучевой диагностики (aidana.syrymova@mail.ru , 87072727001).*

Ключевые слова
почечно-клеточная карцинома, единственная почка, резекция, время ишемии.

Аннотация

Пациентка 57 лет поступила в наше учреждение с признаками 3-х образований единственной правой почки по ультразвуковому исследованию, без клинических проявлений. Из анамнеза: 5 лет тому назад пациентке была выполнена левосторонняя нефрэктомия по поводу почечно-клеточного рака. На этапе предоперационного обследования лабораторные показатели были в пределах нормы.

Пациентке была выполнена органосохраняющая операция – все образования были полностью иссечены. После каждой резекции артериальный кровоток был временно восстановлен до 10 мин. Мы назвали эту технику – техника «старт-пауза». Это улучшило контроль гемостаза. Общее время тепловой ишемии составило 18 мин. Общая кровопотеря составила 200 мл. Состояние пациентки было стабильным, гемодиализ не потребовался. Пациентка была выписана на 11 сутки после операции.

Почечно-клеточная карцинома единственной почки является вызовом как для специалиста, так и для пациента, ведь все зависит от того, какова основная цель лечения, так как, органосохраняющая операция и радикальная операция имеют разные результаты в отдаленном периоде. Таким образом, эти аспекты должны быть учтены при получении согласия на операцию.

Introduction

Renal cell carcinoma is the most common type of kidney cancer in adults. [1] It accounts for approximately 3% of adult malignancies and 90-95% of neoplasms arising from the kidney.

Initial treatment is most commonly either partial or complete removal of the affected kidney(s) [2]. Where the cancer has not any metastasis (spread to other organs) or burrowed deeper into the tissues of the kidney, the five-year survival rate is 65–90%, [3] but this is lowered considerably when the cancer has spread.

Small renal tumors (< 4 cm) are treated increasingly by partial nephrectomy when possible. [4] Most of these small renal masses manifest indolent biological behavior with excellent prognosis.[5] Nephron-sparing partial nephrectomy is used when the tumor is small (less than 4 cm in diameter) or when the patient has other medical concerns such as diabetes or hypertension. [6] The partial nephrectomy involves the removal of the affected tissue only, sparing the rest of the kidney, Gerota's fascia and the regional lymph nodes. This allows for more renal preservation as compared to the radical nephrectomy, and this can have positive long term health benefits.[7] Larger and more complex tumors can also be treated with partial nephrectomy by surgeons with a lot of kidney surgery experience.

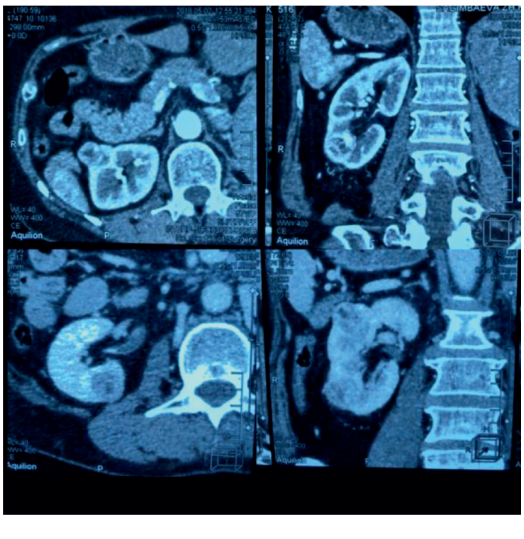

Figure 1. Computed tomography

Case presentation

57- year old female with the previous history of nephrectomy of the left kidney with renal cell carcinoma was admitted to our department completely asymptomatic with no classic clinical signs such as pain, gross hematuria or palpable mass. Preoperatively, on renal computed tomography with contrast enhancement 3 (three) neoplasms were detected on the right kidney: 2.5 cm tumor on posterior surface centrally, 3.0 cm - laterally on the lower pole and 3.0 cm - anteriorly on the upper pole. (Fig.1). Creatinine was 1.02 mg/dl and BUN was 5.2 mmol/l. During the preoperative evaluation there were not detected any sites of metastasis.

According to the patient's history in 2013 she underwent open surgery – radical nephrectomy on the left for renal cell carcinoma. She was on follow up annually to date. Considering the previous history, the neoplasms were regarded as recurrent

renal cell carcinoma. Taking into account normal function of the kidney, the refusal of patient to go on hemodialysis furtherly and the desire to maintain good quality of

life we decided to perform renal sparing surgery.

All neoplasms were fully excised and total warm ischemic time was 18 min (Fig.2). We used "start - break" technique, that refers to the temporary revascularization of kidney after each excision for up to 10 min. This technique has two advantages: firstly, it minimizes the warm ischemic time and, the second, is the opportunity to better control blood loss precisely after each excision. Postoperatively patient was hemodynamically stable, but the levels of creatinine and BUN increased on 2 postop day up to 4.1 mg/dl and 15.6 mmol/l, respectively. Potassium level was constant. Urine output was decreased until 800 ml. Patient's condition was relatively stable and did not necessitate hemodialysis. On the 10th postop day creatinine was 1.78 mg/dl and BUN was 6.5mmol/l. Urine output also greatly increased up to 2.5 l/day. Patient was discharged on 11th postoperative day in stable state condition. Histologically neoplasms were regarded as clear cell renal cell carcinoma grade 2. After 4 weeks of follow up creatinine and BUN are 1.3 mg/dl and 7.0 mmol/l, respectively. 6 month after the surgery patient has arrived for check - up. On computed tomography of kidney were no signs of recurrence and biochemistry assays were normal (Fig. 3). Creatinine was 1.2 mg/dl.

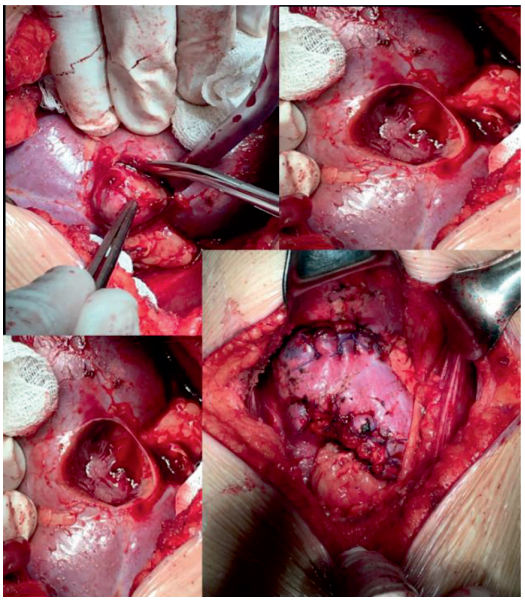

Figure 2.
Excision of neoplasms. End view

Figure 3.
Computed tomography 6 months after surgery

Conclusion

According to previous reports at 5 and 10 years the overall survival rate in such kind of patients after renal sparing surgery was 74.7% and 45.8%, the cancer specific survival rate was 80.7% and 63.7%, the local recurrence-free survival rate was 89.2% and 80.3%, and the metastasis-free survival rate was 69% and 50.4%, respectively [8].

Such cases are very rare but if it is encountered we suppose that "start - break" can be safely used for excision two or more neoplasms in a solitary kidney in order minimize the ischemic injury and preserve the function.

References

1. Jemal A, Murray T, Ward E, et al. Cancer statistics, 2005. CA Cancer J Clin. 2005;55:10–30.
2. Janzen NK, Kim HL, Figlin RA, Belldegrun AS. Surveillance after radical or partial nephrectomy for localized renal cell carcinoma and management of recurrent disease. Urol Clin North Am. 2003;30:843–852.
3. McNichols DW, Segura JW, DeWeerd JH. Renal cell carcinoma: long-term survival and late recurrence. J Urol. 1981;126:17–23.
4. Ljungberg B, Alamdari FI, Rasmuson T, Roos G. Follow-up guidelines for nonmetastatic renal cell carcinoma based on the occurrence of metastases after radical nephrectomy. BJU Int. 1999;84:405–411.
5. Levy DA, Slaton JW, Swanson DA, Dinney CP. Stage specific guidelines for surveillance after radical nephrectomy for local renal cell carcinoma. J Urol. 1998;159:1163–1167.
6. Lam JS, Leppert JT, Figlin RA, Belldegrun AS. Surveillance following radical or partial nephrectomy for renal cell carcinoma. Curr Urol Rep. 2005;6:7–18.
7. Lam JS, Leppert JT, Figlin RA, Belldegrun AS. Surveillance following radical or partial nephrectomy for renal cell carcinoma. Curr Urol Rep. 2005;6:7–18.
8. Bani-Hani AH, Leibovich BC, Lohse CM, et al. Association with contralateral recurrence following nephrectomy for renal cell carcinoma using a cohort of 2352 patients. J Urol. 2005;173:391–4.

ID:2019(59)215
DOI: 10.35805/kazsurgeryvhk
2019(59)215
МРНТИ 76.29.39

SURGICAL TREATMENT OF ANAL PROLAPSE AND THEIR COMPARATIVE CHARACTERISTICS

ABOUT THE AUTHORS

Xalilova L.F. - *Scientific Center of Surgery named M.A. Topchibasheva*

Khalilova L.F.
Scientific Center of Surgery named after M.A. Topchibasheva, Baku, Azerbaijan

Abstract

In the presence of anal prolapse, perform operations on the loose, ulcerated mucous membrane of the anal canal for its sagging is fraught with the danger of bleeding during and after surgery. It is also highly likely that cidiva disease. The purpose of this study is to compare the methods of surgery used for anal prolapse, which most often accompanies stage 4 hemorrhoidal disease. In our study 400 patients in the age group from 20 to 71 years old were operated on from 2006 to 2016. All sick were divided into 3 groups. The main group included 308 (77.0%) patients who underwent hemorrhoidectomy linear stapler. Control group I included 74 patients (18.5%), who produced a typical open.

hemorrhoidectomy. The control group II consisted of patients who underwent surgery according to the method of Longo with use of a circular stapler PPH-18 patients (4.5%). For the duration of the operation using linear the stapler lasted 22.9 ± 0.4 min. The classic Milligan-Morgan operation lasted on average 34.9 ± 0.8 min. Operation Longo took an average of 29.3 ± 1.2 min. Bleeding during surgery was observed in 3 patients (1%) when using a linear stapler, in 6 patients (8.1%) during standard hemorrhoidectomy and in 2 patients comrade (11.1%) during the Longo operation. Long-term complications such as stricture and relapse in the main group one case is 0%; in the control group I, 6 patients had a relapse of the disease (8.1%), in 12 cases - a stricture Anal canal (16.2%); in the control group II, there were 2 cases of relapse (11.1%) and 2 cases of stricture (11.1%). Good quality of life was considered by 162 patients (76.4%) who underwent surgery using a linear stapler; 26 patients comrades (50%) who had open hemorrhoidectomy, and 6 patients (46.2%) after Longo surgery.

Thus, when evaluating the immediate results of the treatment of anal prolapse, surgery using linear stapler has several advantages. The advantage is expressed in the relative simplicity of the technique, and from the absence of a long-term relapse.

Keywords
anal prolapse, linear stapler, Longo operation, anal mucosa, hemorrhoidectomy

Аналдық пролапстың хирургиялық емінің түрлері және олардың салыстырмалы сипаттамасы

АВТОРЛАР ТУРАЛЫ

Халилова Л.Ф. - *М.А. Топчибашев атындағы Ұлттық хирургия орталығы*

Халилова Л.Ф
М.А. Топчибашева атындағы Ғылыми-хирургиялық орталық, Баку, Әзірбайжан

Аңдатпа

Анальды пролапс болған кезде, анальды каналдың борпылдақ, жараланған шырышты қабығына операция кезінде операция кезінде де, одан кейін де қан кету қаупі бар. Аурудың қайталану ықтималдығы да жоғары. Бұл зерттеудің мақсаты геморроидальды аурудың 4 сатысымен жиі кездесетін анальды пролапс кезінде қолданылатын хирургия әдістерін салыстыру болып табылады

Біздің зерттеуге 2006 жылдан бастап 2016 жылға дейін жұмыс істеген 20-дан 71 жасқа дейінгі 400 науқас енгізілді.

Барлық науқастар 3 топқа бөлінді.

Негізгі топқа 308 (77,0%) науқастар кірді, олар геморроидэктомия сызықты степлермен өтті.

I бақылау тобына әдеттегі ашық геморроидэктомиясы бар 74 науқас (18,5%) кірді.

Бақылау тобының II тобына пациенттердің PPH-18 дөңгелек қапсырмаларын (4,5%) қолдана отырып Longo әдісі бойынша операция жасалған пациенттер кірді.

Сызықтық қапсырманы қолдана отырып жұмыс ұзақтығы 22,9 ± 0,4 минутқа созылды. Классикалық Миллиган-Морган операциясы орта есеппен 34,9 ± 0,8 мин созылды. Longo операциясы орташа алғанда 29,3 ± 1,2 минутты құрады. Хирургия кезінде қан кету сызықтық қапсырманы қолданатын 3 науқаста (1%), стандартты геморроидэктомия кезінде 6 пациентте (8,1%) және Лонго операциясы кезінде 2 науқаста (11,1%) байқалды.

Структура және негізгі топтағы рецидив сияқты ұзақ мерзімді асқынулар, еш бір жағдайда жағдайда 0%; I бақылау тобында 6 науқаста аурудың қайталануы байқалды (8,1%), 12 жағдайда - анальды каналдың структурасы (16,2%); II бақылау тобында рецидивтің 2 жағдайы (11,1%) және қатаңдаудың 2 жағдайы (11,1%) болды.

Сызықтық қапсырманың көмегімен операция жасатқан 162 пациент (76,4%), 26 науқас (50%) ашық геморроидэктомиядан өткен, 6 науқас (46,2%) Лонго операциясынан кейін өмірдің жақсы сапасын қарастырды.

Осылайша, анальды пролапсты емдеудің дереу нәтижелерін бағалағанда, сызықты қапсырғышты қолданған хирургияның бірнеше артықшылығы бар. Артықшылығы техниканың салыстырмалы қарапайымдылығында және рецидивтердің алыс кезеңінде болмауында көрінеді.

Түйін сөздер
анальды пролапс, сызғыш қапсырғыш, Лонго операциясы, анальды шырышты қабық, геморроидэктомия

Хирургические методы лечения анального пролапса и их сравнительная характеристика

Халилова Л.Ф.
Научный Центр Хирургии им. М.А. Топчибашева, Баку, Азербайджан

ОБ АВТОРАХ

Халилова Л.Ф. -
Научный Центр Хирургии им. М.А. Топчибашева

Аннотация

При наличии анального пролапса проводить операции на рыхлой, изъязвленной слизистой анального канала из-за ее провисания чревато опасностью кровотечения как во время, так и после операции. Так же высока вероятность рецидива заболевания. Целью данного исследования является сравнить методы операции, используемые при анальном пролапсе, который чаще всего сопровождает геморроидальную болезнь 4 стадии. В проводимое нами исследование включено 400 пациентов в возрастной категории от 20 до 71 года, оперированных с 2006 по 2016 год. Все больные были разделены на 3 группы. В основную группу вошли 308 (77,0%), пациентов, которым выполнена геморроидэктомия линейным степлером. В контрольную группу I включены 74пациента (18,5%), которым произведена типичная открытая геморроидэктомия. Контрольную группу II составили больные, которым выполнена операция по методу Лонго с использованием циркулярного степлера PPH-18 пациентов (4,5%). По длительности операция с применением линейного сшивателя длилась 22,9 ± 0,4 мин. Классическая операция по Миллигану-Моргану длилась в среднем 34,9 ± 0,8 мин. Операция Лонго занимало в среднем 29,3 ± 1,2 мин. Кровотечение во время операции наблюдали у 3 больных (1%) при использовании линейного степлера, у 6 больных (8,1%) во время стандартной геморроидэктомии и у 2 пациентов(11,1%) во время операции Лонго. Отдаленные осложнения, такие как стриктура и рецидив в основной группе ни в одном случае 0%; в контрольной группе I у 6 больных наблюдали рецидив заболевания (8,1%) , в 12случаев - стриктура анального канала (16,2%); в контрольной группе II 2случая рецидива (11,1%) и 2случая стриктуры (11,1%). Хорошим качество жизни сочли 162 пациента (76,4%), перенесших операцию с применением линейного сшивателя, 26 пациентов(50%) перенесших открытую геморроидэктомию, и 6 пациентов (46,2%) после операции Лонго.

Таким образом, при оценке непосредственных результатов лечения анального пролапса операция с применением линейного степлера имеет ряд преимуществ. Выражается преимущество в относительной простоте методики, и отсутствие в отдаленном периоде рецидивов.

Ключевые слова
анальный пролапс, линейный степлер, операция Лонго, слизистая анального канала, геморроидэктомия

Anal prolapse or prolapse of the mucous membrane of the anal canal can be observed as an independent state and may accompany stage 4 hemorrhoidal disease. Muscle and fibroelastic tissues that hold hemorrhoids in the anal canal, under the influence of unfavorable factors are prone to degenerative changes, which leads to «slipping» and displacement of the internal hemorrhoids in the distal direction and later on the mucous membrane of the anal canal. Anal prolapse develops. Maceration of the falling out mucous membrane and anoderm, ulceration of the epithelium, mucus drainage, regular, often heavy bleeding significantly worsen the quality of life of patients.

In all stages, as well as in stage 4 hemorrhoids, the classical Milligan-Morgan operation is used with concomitant anal prolapse [1, 2]. Based on the literature data, a pronounced pain syndrome develops in 23-33% of operated patients. Reflex urinary retention is observed in 14-27% of patients. In 5-7% of operated patients, it becomes bladder atony, requiring prolonged catheterization and medical treatment [3,4]. 4-6% of operated patients develop wound suppuration or early bleeding from the anus [5,6] and 2-4% of patients develop a stricture of the anal canal, insufficiency of the anal press and relapse of the disease [7]. Recent studies comparing the open and closed Milligan-Morgan method were published in 2015 [8]. Despite the slight advantages in the early postoperative period, the authors in the report indicate the absence of a statistically significant difference between open and closed hemorrhoidectomy with 3-4 stages of hemorrhoids. The study lacks data on the presence or absence of rectal or anal prolapse in patients.

Attempts to use a mechanical suture on circular staplers as a lifting operation in the treatment of prolapses were first presented by A. Longo. [9,10]. In contrast to the previously proposed methods, during this operation, the removal of hemorrhoids is not provided.

Although for 20 years considerable experience has been gained in the application of this technique, unambiguous results have not been obtained and data collection continues. The study, conducted by Chinese scientists and published in 2015, involved 1411 patients. This conclusion of the Chinese scientists comes down to the fact that in the presence of anal prolapse, the technique of using the linear PPH stapler has several advantages over standard hemorrhoidectomy. But in the presence of pronounced prolapse of the mucous membrane and prolapse of

Table 1.
Duration of operations

Average duration interventions (min)	Core group n=120	Control group I n=62	Control group II n=18	p
	22,9±0,5	34,9±0,8	29,3±1,2	<0,001

hemorrhoidal nodes of stage 4, the probability of a relapse of the disease is high [11].

There are clinical studies conducted from 2012 to 2014 in several clinics in Italy. The results of these studies were merged and given in a publication in year 2016. The study included patients with anal prolapse in combination with stage 3-4 hemorrhoids. After 12 months, recurrence of hemorrhoids and prolapse was observed in 11 patients out of 621 (1.8%) and in 12 out of 58 patients (1.9%) [12,13]. R. Molloy and D. Kingsmore (2000) described a case of severe pelvic sepsis after the use of a circular mucous-submucosal resection of the rectal section in hemorrhoids [14]. L.P.Wong, J.K.Jiang, S.C.Chang, J.K. Lin (2003) describe a case of rectal perforation with the development of fecal peritonitis after circular stapler hemorrhoidectomy [15].

In 1988 VB Alexandrov and co-authors [16,17,18,19] developed and introduced into practice the method of closed hemorrhoidectomy using a mechanical suture. Yu. K. Bogomazov [20] conducted a comparative assessment of the use of a linear stapler and the operation of Milligan-Morgan [20] in his dissertation work. In the study it was found that postoperative pain is less pronounced in patients of the main group; the decrease in the intensity of pain syndrome is more dynamic in patients of the main group; the need for analgesics, including narcotic ones, is higher in patients of the control group. This paper does not focus on the category of patients - the presence or absence of anal prolapse. Despite the positive opinion on the use of a linear stapler, the technique was not widely used and did not receive recommendations as an option for surgery in the treatment of hemorrhoidal disease. There is also no indication of the possibility of using a linear mechanical suture for the treatment of anal prolapse of both an isolated disease and the accompanying hemorrhoidal disease. In the literature, there are no data on the comparative evaluation of clinical results, in the early and long-term periods, after circular resection of the mucous-submucous layer of the lower ampullae of the rectum, standard hemorrhoidectomy and hemorrhoidectomy using a linear stapler with anal prolapse.

Thus, the relevance of research on the treatment of hemorrhoids with the presence of anal prolapse, a comparative study of clinical results in the early and long-term after circular resection of the mucous-submucosal layer of the lower ampullae of the rectum, standard hemorrhoidectomy and hemorrhoidectomy using a linear stapler during anal prolapse is obvious.

The purpose of this work is to improve the results of surgical treatment of anal prolapse and hemorrhoidal disease of stage IV.

The main content of the work

In our study, 400 patients were included in the age category from 20 to 71 years old, of which 334 (83.5%) were men and 66 (16.5%) women operated from 2006 to 2016. All patients were divided into 3 groups. The main group included 308 (77.0%) patients who underwent hemorrhoidectomy with a linear stapler UO-40. The control group I included 74 patients (18.5%), who produced a typical open hemorrhoidectomy using an electrocoagulator. The control group II consisted of patients who underwent circular hemorrhoidopexy according to the Longo method using the PPH-01 tool kit specially designed and manufactured by Ethicon (USA) for -18 patients (4.5%).

During the Longo operation, excision of the external hemorrhoidal tissue was not performed at the beginning of the study. But after 2 patients were observed postoperative thrombosis of the external nodes, excision of external hemorrhoids is considered mandatory.

The main criteria for evaluating the immediate results of the intervention in patients of the studied groups were: the duration of the operation; frequency of bleeding during and after surgery; severity and duration of pain; the presence of strictures and recurrence of the disease; quality of life after surgery.

The duration of the operation using a linear stapler lasted 22.9 ± 0.4 minutes. The classic Milligan-Morgan operation lasted an average of 34.9 ± 0.8 min. This is an average of 52.2% longer than the operation using a linear stapler ($p < 0.001$). Operation Longo took an average of 29.3 ± 1.2 min. (Table 1). This is 28% longer than the surgery performed in the main group ($p1 < 0.001$) and 15.9% shorter than standard hemorrhoidectomy ($p2 < 0.01$).

Thus, over time, the average duration of surgery using a linear stapler was significantly less by

Table 2.
The frequency of bleeding during surgery.

Intraoperative bleeding	Basic	Control I	Control II	Total	p
	3(01,0%)	6(8,1%)	2(11,1%)	11(2,8%)	<0,01

Table 4.
The frequency of early postoperative complications

Complications	Basic	Control I	Control II	p
Bleeding	1(0,3%)	3(4,1%)	2 (11,1%)	<0,01
Edema	0	8(10,8%)	4(22,2%)	

Table 5.
The frequency of complications in the late postoperative period

Complication	Basic	Control I	Control II	p
Relapse	0 (0%)	6 (8,1%)	2 (11,1%)	<0,01
Stricture	0 (0%)	12 (16.2%)	2 (11,1%)	

52.2% compared with standard hemorrhoidectomy and 28% less compared with hemorrhoidopexy using the Longo method in the presence of anal prolapse.

Bleeding during surgery was only in 11 (2.8 ± 0.8%) patients out of 400. Of these, in 3 patients (1 ± 0.6%) using a linear stapler, in 6 patients (8.1 ± 3, 2%) during standard hemorrhoidectomy and in 2 patients (11.1 ± 7.4%) during Longo surgery. (table 2). As can be seen from the results of the study, the lowest probability of blood loss during surgery was when using a linear stapler – only 1% (p <0.01).

As pain developed, pain relievers were administered to patients. Their purpose depended on the degree of pain (on a 5-point scale depending on the patient). The intensity of pain after surgery using a linear stapler averaged 4.71 ± 0.03 points; 3.05 ± 0.02 points on the first day after surgery; 2.41 ± 0.03 points on the 7th day after the operation and 0.03 ± 0.03 points 40 days after the operation. The intensity of pain after standard hemorrhoidectomy averaged 4.89 ± 0.04 points; 3.39 ± 0.07 points on the first day after surgery; 2.77 ± 0.06 points on the 7th day after the operation and 0.57 ± 0.09 points 40 days after the operation. The intensity of pain after surgery Longo with the use of a circular stapler 4,17 ± 0,19 points; 3.11 ± 0.2 points on the first day after surgery; 2.39 ± 0.18 points on the 7th day and 0.39 ± 09.14 points 40 days after the operation. The differences were statistically significant (p <0.01).

Early postoperative complications (Table 4) were noted in 1 (0.3 ± 0.3%) patients operated on with the use of a linear stapler (bleeding), in 11 (14.9%) who had undergone classical hemorrhoidectomy. Of these, 8 patients (10.8 ± 3.6%) had external edema of interstitial bridges, 3 had bleeding (4.1 ± 1.2%). 6 cases of complications in the early postoperative period in patients undergoing Longo's surgery, of these 4 cases (22.2 ± 9.8%) per edema and 2 cases (11.1 ± 7.4%) of postoperative bleeding (p <0, 01).

Long-term complications (Table 5), such as stricture and relapse in the main group, in no case 0%; in the control group I only in 18 people. Of these, 6 of the disease relapse (8.1 ± 3.2%) and 12 cases of stricture (16.2 ± 4.3%, p <0.01); in the control group II in 4 patients, which is 22.2%. Of these, 2 relapses (11.1 ± 7.4%) and 2 cases of stricture (11.1 ± 7.4%, p <0.01).

Analysis of the quality of patients's life was carried out by the method of questioning. A subjective assessment was considered: the absence of tissue prolapse and at rest and during straining the absence of secretions (mucous, blood), the presence of painless bowel movements. At the same time, a good quality of life was considered in 162 patients (76.4 ± 2.9%) who underwent surgery using a linear stapler, in 26 patients (50 ± 6.6%) who underwent open hemorrhoidectomy, and in 6 patients (46 ± 13, 8%) after surgery Longo (p <0.01).

Thus, when evaluating the immediate results of anal prolapse treatment with surgery using a linear stapler has several advantages over resection of the mucous-submucosal layer with a circular stapler and over classical hemorrhoidectomy, which is also used in the presence of anal prolapse. The advantage is expressed in the relative simplicity of the method (the ability to revise the linear seam and ease of access to it), and the lack of a long-term recurrence period. With the application of UKL, the problems of hemorrhoids and prolapse are solved simultaneously; the connective tissue framework, which forms at the site of the staples, simulates the original ligamentous apparatus, forms a kind of anal framework, which prevents the mucous membrane from sagging again.

When using a circular stapler with a high suture position, it is possible to correct the mucosal prolapse, but hemorrhoropexy cannot be achieved. With a low position of the circular suture, a pronounced pain syndrome is possible, and the problem of prolapse of the anal mucosa is not solved. However, the method is somewhat inferior to the method of Longo in less trauma and, as a result, a more pronounced pain syndrome, provided that the circular mucous-submucous resection is not supplemented by external hemorrhoidectomy. Taking into account all the pros and cons, in the presence of anal prolapse, the use of a stapling apparatus is more appropriate than the use of a circular stapler, and even more so the use of the Milligan-Morgan operation.

Findings

1. Surgical treatment of anal prolapse using a linear stapler is a pathogenetically based, radical method, which allows to achieve good results.
2. The elimination of anal prolapse using a linear stapler allows you to minimize pain, to avoid bleeding during surgery and in the early postoperative period. The use of a linear stapler for hemorrhoidectomy makes it possible to avoid such complications as insufficiency of the anal sphincter and anal stricture in the late postoperative period.
4. Linear mucous-submucous resection prevents the building up of the walls of the anal sac cannula, forming a fibrous linear framework that prevents prolapse recurrence.
5. Technically, the technique of using a mechanical stapler is simple to perform and does not require special skills, which allows to reduce the time of the operation even with pronounced anal prolapse and hyperplastic hemorrhoids.

Practical recommendations

1. Hemorrhoidectomy using a linear stapler is indicated for stage 3-4 hemorrhoidal disease, accompanied by anal prolapse.
2. Perhaps the widespread use of the device in macerated mucous and thick vascular pedicle.
3. After hemorrhoidectomy with the use of a linear stapler, preventive therapy with analgesic drugs is shown, although the pain syndrome with this technique is moderate.
4. Despite the advantages of hemorrhoidectomy with a linear stapler who underwent this operation, it is necessary to comply with all traditional recommendations.

References

1. Milligan E., Morgan G., et al. Surgical anatomy of the anal canal and operative treatment of hemorrhoids. Lancet, 1937, 2:1119-1124
2. Milligan E.T. Surgical anatomy of the anal canal and operative treatment of haemorrhoids. / Milligan E.T., Morgan G.N., Jones
3. Fedorov V.D. Proctology / Fedorov VD, Dultsev Yu.V. // M.: Medicine, 1984.-383 p.
4. Nychkin S.G. Electroradiosurgical hemorrhoidectomy is a new trend in proctology. / Nychkin S.G., Kuzminov A.M. // Problems of Coloproctology .- M., 2000.- P. 153
5. Hoff S.D. Ambulatory surgical haemorrhoidectomy and solution to postoperative urinary retention? / Hoff S.D., Bailey H.R., Butts D.R. // Dis. Colon Rectum.- 1994.- Vol.37, N12.- P.1242-1244. Hoff S.D. Ambulatory surgical haemorrhoidectomy and solution to postoperative urinary retention? / Hoff S.D., Bailey H.R., Butts D.R. // Dis. Colon Rectum .- 1994.- Vol.37, N12.- P.1242-1244.
6. Corno F. Complication of the surgical treatment of haemorrhoids and it's therapy. / Corno F., Muratore A., Mistrangelo M. // Ann-Ital-Chir.- 1995.- Vol.66,N6.-P.813-816.
7. Shalaby R1, Desoky A.//Randomized clinical trial of stapled versus Milligan-Morgan haemorrhoidectomy.// Br J Surg. 2001 Aug;88(8):1049-53.
8. Majeed S, Naqvi SR, Tariq M, Ali MA.//Comparison of open andclosed techniques of hemorrhoidectomy in trms of post-operative complications.// Med Coll Abbottabad. 2015 Oct-Dec;27(4):791-3
9. Longo A. Stapled anopexy and stapled hemorrhoidectomy: two opposite concepts and procedures. // Diseases Colon Rectum, 2002, Vol. 45, №4,-p. 571-572.
10. Longo A. Treatment of hemorroids desease by reduction of mucosa and hemorroidal prolapse with a circular suturing device: a new procedure. // 6 World Congress of Endoscopic Surgery. Rome, 1998, - p. 777-784.
11. (article in Chinese) He P1, Chen H. Meta-analysis of randomized controlled trials comparing procedure for prolapse and hemorrhoids with Milligan-Morgan hemorrhoidectomy in the treatment of prolapsed hemorrhoids. Zhonghua Wei Chang Wai Ke Za Zhi. 2015 Dec;18(12):1224-30.
12. Rondelli F1, Mariani L, Tassi A, Stella P, Mariani PG, Bistoni G, Mariani E.//Closed hemorrhoidectomy with linear stapler: a consecutive series of 300 patients.// In Vivo. 2011 Nov-Dec;25(6):1003-7.
13. Sturiale A1, Fabiani B2, Menconi C2, Cafaro D2, Fusco F2, Bellio G3, Schiano di Visconte M3, Naldini G2.// Long-term results after stapled hemorrhoidopexy: a survey study with mean follow-up of 12 years.// Tech Coloproctol. 2018 Sep;22(9):689-696. doi: 10.1007/s10151-018-1860-8. Epub 2018 Oct 4.
14. Molloy R., Kingsmore D. Life threatening pelvic sepsis after stapled haemorroidectomy. // The Lancet. - 2000. - vol. 355, № 4. - p. 810.
15. Wong L., Jiang J., Chang S., Lin J. Rectal perforation: a life threatening complication of stapled hemorrhoidectomy: report of a case. // Diseases Colon Rectum. - 2003, Vol. 46, № 1. - p. 116-117.
16. Aleksandrov V.B. Original hemorrhoidectomy technique using a mechanical suture. / Aleksandrov VB, Sukhov B.S. et al. // Problems of rehabilitation of proctologic patients. - Minsk, 1998, pp.35-38.
17. Aleksandrov V.B. Closed method of hemorrhoidectomy with the use of a mechanical suture / Aleksandrov VB, Gadzhiev GI, Bogomazov Yu.K., Zorin S.A. // Actual issues of Coloproctology. - Rostov n / a, 2001. -C. 125
18. Dultsev Yu.V. Hemorrhoidectomy using stapling machines. // Dultsev Yu.V., Titov Yu.A., Kalanov R.G. // Surgery.- 1989. №2.-C.115-118
19. Alexandrov V. Original method of hemorroidectomy with stapled suture.//Alexandrov V., Suchov B., Tichonov E., Vinogradov V. // Central European Congress of Coloproctology and Viscerosynthesis 5th.- Brno, 1999/- P. 185.
20. Moskva n/d, 2007. -S. 63-65. Bogomazov Yu.K. Comparative evaluation of the surgical treatment of chronic hemorrhoids using a mechanical suture and a closed standard hemorrhoidectomy –Moskva n / d, 2007. –C. 63-65

THE ROLE OF TRANSARTERIAL CHEMOEMBOLIZATION IN THE TREATMENT OF HEPATOCELLULAR CARCINOMA IN THE STAGE B OF BCLC

ID:2019(59)216
DOI:10.35805/kazsurgeryvhk
2019(59)216
МРНТИ 76.29.49

Tajibayev T.K., Medeubekov U.Sh., Chormanov A.T., Kaniev Sh.A., Issamatov B.K., MD, Baimakhanov B.B.
JSC "National scientific center of surgery named after A.N.Syzganov", Almaty, Kazakhstan

Abstract

Hepatocellular carcinoma is the most common primary tumor pathology of the liver (> 85%), an aggressive course with an unfavorable prognosis. ***Objective:*** *To analyze the results of transarterial chemoembolization in the intermediate stage of hepatocellular carcinoma.* ***Materials and methods:*** *The study was conducted on the basis of the JSC "National Scientific Center of Surgery" named after A.N. Syzganov in the period 2013-2018. Statistical calculations were performed using Excel, SPSS Statistics by estimating the survival rate using the Kaplan-Meier method.* ***Results:*** *The study included 58 patients with HCC in the B stage of BCLC. The average age of the patients was 60.4 years. The follow-up period was 6–64 months. In 42 patients, the test results for viral hepatitis were positive. 58 patients underwent 103 TACE interventions. After chemoembolization, 8 patients subsequently underwent surgery (liver resection). The one-year survival after TACE in the total cohort was 42%, 2-year - 15% and 3-year - 5%, respectively. In patients older than 60 and 70 years, the 3-year and 5-year survival rates were 0%, the one-year survival rate of the subjects studied in the group over 70 years old was 14.3%. The survival rate among patients in stage B on the Chile-Pugh scale was significantly lower to patients in stage A (82% versus 56% for 6 months and 50% versus 31% for the year, respectively). Statistically significant differences were found in the group with a substantial increase in AFP (> 1000 IU / ml), the Kaplan-Meier survival curve showed a survival rate of 0% after 18 months since the first TACE. Six months after TACE contrast enhanced CT was performed on 36 patients, of which 15 patients showed positive dynamics, in the form of a reduction in size or transformation of the formation, in 6 patients a negative dynamics in the form of an increase in the size of the formation.* ***Conclusion:*** *Despite the small number of patients studied, TACE showed good results in the intermediate stage of HCC. Elderly and senile age, a high degree of liver dysfunction, as well as high AFP values are additional factors that dramatically reduce the life expectancy of patients after TACE with HCC in stage B-BCLC.*

ABOUT THE AUTHORS

Tajibayev Talgat Kydyraliyevich *- MD, Department of Hepatopancreatobiliary surgery and liver transplantation, JSC «NSCS named after A.N. Syzganov»*

Baimakhanov Bolatbek Bimendievich *– Doct. of Med. Sciences, Professor, Chairman of the Board JSC «NSCS named after A.N. Syzganov»*

Medeubekov Ulugbek Shalkarovich *– Doct. of Med. Sciences, Professor, Deputy Chairman of the Board of JSC «NSCS named after A.N. Syzganov».*

Kaniev Shokan Ahmedbekovich *– Surgeon, Department of Hepatopancreatobiliary surgery and liver transplantation, JSC «NSCS named after A.N. Syzganov»*

Issamatov Bekzhan Kalibayevich *- researcher of the JSC «NSCS named after A.N. Syzganov»; doctorant of the Department «Visual diagnostics», JSC "National Medical University"*

Keywords
Chemoembolization, Hepatocellular carcinoma, TACE

B-BCLC сатысындағы гепатоцеллюлярлы карциноманың емдеуінде трансартериалды химиоэмболизацияның рөлі

Таджибаев Т.К., Медеубеков У.Ш., Чорманов А.Т., Каниев Ш.А., Исаматов Б.К., Баймаханов Б.Б.
«А.Н. Сызғанов атындағы Ұлттық ғылыми хирургия орталығы» АҚ, Алматы, Қазақстан

Аңдатпа

Гепатоцеллюлярлық карцинома - бұл бауырдың ең негізгі таралған патологиясы (> 85%), қолайсыз болжамды агрессивті курс. ***Мақсаты:*** *гепатоцеллюлярлық карциноманың аралық сатысында трансартериалды химиоэмболиясының нәтижелерін талдау.* ***Материалдар мен әдістер:*** *Зерттеу 2013-2018 жылдардағы А.Н. Сызғанов атындағы «Ұлттық ғылыми хирургия орталығы» базасында өткізілді. Статистикалық есептеулер Excel, SPSS статистикасы бойынша Kaplan-Meier әдісін қолданып өмір сүру жылдамдығын бағалау арқылы орындалды.* ***Нәтижелері:*** *Зерттеуде ГЦК бар 58 науқас BCLC аралық сатысында болды. Пациенттердің орташа жасы 60,4 жасты құрады. Бақылау кезеңі 6-64 ай болды. 58 науқасқа 103 ТАХЭ жасалынды. Химмиэмболизациядан кейін 8 науқас кейін ашық хирургиялық ота (бауырдың резекциясы) жасалынды. ТАХЭ ден кейін бір жылдық өмір сүру көрсеткіші 42%, 2 жыл - 15% және 3 жыл - 5% боллды. 60 жастан 70 жасқа дейінгі жастағы науқастарда 3 жылдық және 5 жылдық өмір сүру көрсеткіші 0% болды, 70 жастан асқан топтағы бір жылдық өмір сүру деңгейі 14,3% құрады. Чайлд-Пью шкаласы бойынша В кезеңіндегі пациенттердің өмір сүру деңгейі А кезеңіндегі науқастардан айтарлықтай төмен болған (82%ға қарсы 56 % 6 ай ішінде, 50%ға қарсы 31% бір жыл ішінде). АФП (> 1000 IU / ml) деңгейіндегі айқын байқалған топта статистикалық тұрғыдан айтарлықтай айырмашылықтар байқалды, бірінші ТАХЭ-ден бастап 18 айдан кейін Каплан-Меердің графиг көрсеткіші 0% көрсетті. ТАХЭ ден кейін КТ алты ай өткен соң 36 науқасқа зерттеу жүргізілді, оның ішінде 15 пациент формацияның мөлшерін азайту немесе түрлендіру түрінде оң динамикасын көрсетті, 6 науқаста теріс динамика болды.* ***Қорытынды:*** *Зерттелген науқастардың аздығына қарамастан, ТАХЭ ГЦК-дің аралық сатысында жақсы нәтижелер көрсетті. Қарт жасы, бауыр дисфункциясының жоғары дәрежесі, сондай-ақ жоғары АФП көрсеткіші ГЦК-ның B-BCLC сатысында өмір сүру ұзақтығын айтарлықтай төмендететін қосымша факторлар болып саналады.*

АВТОРЛАР ТУРАЛЫ

Таджибаев Талғат Қыдыралиұлы *– «А.Н.Сызғанов атындағы Ұлттық ғылыми хирургия орталығы» АҚ ғылыми қызметкері, хирург.*
Баймаханов Болатбек Бимендеұлы *– м.ғ.д. профессор, А.Н.Сызғанов атындағы Ұлттық ғылыми хирургия орталығы» АҚ басқармасының төрағасы.*
Медеубеков Ұлықбек Шалхарұлы *– м.ғ.д. профессор, А.Н.Сызғанов атындағы Ұлттық ғылыми хирургия орталығы» АҚ басқарма төрағасының орынбасары.*
Чорманов Алмат Турсыжанұлы *- м.ғ.к., А.Н.Сызғанов атындағы Ұлттық ғылыми хирургия орталығы» АҚ бас дәрігері*
Қаниев Шоқан Ахмедбекұлы *– «А.Н.Сызғанов атындағы Ұлттық ғылыми хирургия орталығы» АҚ Гепатобилиарлы хирургия және бауыр трансплантациясы бөлімінің хирург-дәрігері.*
Исаматов Бекжан Калибайұлы *– «А.Н.Сызғанов атындағы Ұлттық ғылыми хирургия орталығы» АҚ ғылыми қызметкері, «Ұлттық медицина университеті» АҚ «Визуалды диагностика» кафедрасының докторанты.*

Түйін сөздер
Химиоэмболизация, Гепатоцеллюлярлы карцинома, ТАХЭ.

Роль трансартериальной химиоэмболизации при лечении гепатоцеллюлярной карциномы в стадии B-BCLC

ОБ АВТОРАХ

Таджибаев Талгат Кыдыралиевич – *хирург, научный сотрудник, АО «ННЦХ им.А.Н.Сызганова».*

Баймаханов Болатбек Бимендеевич – *д.м.н., профессор, председатель правления АО «ННЦХ им.А.Н.Сызганова».*

Медеубеков Улугбек Шалхарович – *д.м.н., профессор, зам. председателя правления по научно-клинической работе АО «ННЦХ им.А.Н.Сызганова».*

Чорманов Алмат Турсынжанович – *к.м.н., главный врач АО «ННЦХ им.А.Н.Сызганова».*

Каниев Шокан Ахметбекович – *хирург отдела гепатобилиарной хирургии и трансплантации печени АО «ННЦХ им.А.Н.Сызганова».*

Исаматов Бауржан Калибаевич - *научный сотрудник, АО «ННЦХ им.А.Н.Сызганова».*

Ключевые слова

Химиоэмболизация, Гепатоцеллюлярная карцинома, ТАХЭ.

Таджибаев Т.К., Медеубеков У.Ш., Чорманов А.Т., Каниев Ш.А., Исаматов Б.К., Баймаханов Б.Б.

АО «Национальный научный центр хирургии им. А.Н.Сызганова, Алматы, Казахстан

Аннотация

Гепатоцеллюлярная карцинома - самая частая первичная опухолевая патология печени (>85%), агрессивного течения с неблагоприятным прогнозом. ***Цель:*** *Проанализировать результаты трансартериальной химиоэмболизации в промежуточной стадии гепатоцеллюлярной карциномы.* ***Материалы и методы:*** *Исследование проводилось на базе АО «Национальный научный центр хирургии» им А.Н.Сызганова в периоде 2013-2018 годы. Статистические расчеты проводились с применением программы Excel, SPSS Statistics путем оценки выживаемости методом Каплана-Майера.* ***Результаты:*** *В исследование были включены 58 пациентов с ГЦК в промежуточной стадии по BCLC. Средний возраст пациентов было 60,4 лет. Период наблюдения пациентов составил 6-64 месяца. У 42 пациентов результаты тестов на вирусные гепатиты были положительными. 58 пациентам выполнено 103 вмешательства ТАХЭ. После химиоэмболизации 8 пациентов в последующем перенесли открытые оперативные вмешательства (резекция печени). Годичная выживаемость после ТАХЭ в общей когорте оставил 42%, 2х-годичная – 15 % и 3х-годичная - 5% соответственно. У пациентов старше 60 и 70 лет 3х летняя и 5 летняя выживаемость составила 0%, годичная выживаемость исследуемых в группе старше 70 лет составила 14,3 %. Процент выживаемости среди пациентов в стадии B по шкале Чайл-Пью значительно уступали пациентам в стадии A (82% против 56% в течение 6 месяцев и 50% против 31% в течение года соответственно). Статистически значимые различия выявлены у группы с выраженным повышением АФП (>1000 IU/ml), кривая выживаемости Каплана-Майера показала выживаемость 0% спустя 18 месяцев с момента первого ТАХЭ. Через 6 месяцев после ТАХЭ КТ исследование с контрастным усилением было проведено 36 пациентам, из них у 15 пациентов отмечалась положительная динамика, в виде уменьшения размеров или трансформации образования, у 6 пациентов отрицательная динамика – в виде увеличения размеров образования.* ***Заключение:*** *Несмотря на небольшое количество исследуемых пациентов, ТАХЭ показал хорошие результаты в промежуточной стадии ГЦК. Пожилой и старческий возраст, высокая степень нарушения функции печени, а так же высокие значения АФП являются дополнительными факторами, резко снижающими продолжительность жизни пациентов после ТАХЭ с ГЦК в стадии B-BCLC.*

Introduction

Hepatocellular carcinoma (HCC) is the most common primary tumor pathology of the liver (> 85%), an aggressive course with an unfavorable prognosis - 5 years of survival does not exceed 15% [1]. Among the causes of cancer mortality in the world, HCR ranks 2nd - about 746,000 patients died in 2012 [2], [3].

According to various sources, in patients with hepatocellular cancer, the diagnosis of concomitant cirrhosis varies from 30 to 80% [4]. In the etiology of HCC, the leading theory is the theory of viral carcinogenesis, which is a complex and multi-step process. The risk groups for HCC are patients with cirrhosis of any etiology, chronic viral hepatitis, alcoholic and nonalcoholic steatohepatitis, hemochromatosis [5].

Currently, the generally accepted and widespread classification of HCC is the Barcelona Clinical Liver Classification (BCLC, Barcelona Clinic Liver Cancer), which takes into account the prevalence of the tumor process, the functional state of the liver, the objective state of the patient and the intended effectiveness of the treatment. People with hepatocellular carcinoma in the intermediate (B by BCLC) stage have large, multiple cancer nodules, without severe liver failure and macrovascular invasion [6].

Transcatheter arterial chemoembolization (TACE) is the widely used treatment for unresectable HCC. In early stages it is not recommended as first line therapy because of a effectiveness lower than surgery and percutaneous ablation (7); so it represents the treatment of choice in the intermediate HCC and selected cases of advanced HCC. The main goal of this approach is to a obtain tumor necrosis, local neoplastic control, with preserving as much as possible remainder functional liver.

In the presence of all possible types of surgical intervention (transplantation, liver resection), correct interpretation of the results of local (TACE, ablation) and systemic effects is extremely important. Timely rejection of locoregional exposure with a predicted low efficacy of repeated TACE and timely initiation of systemic therapy increases the life expectancy of patients with HCC BCLC B (8).

For untreated HCC in stage B (the expected median of the agent is 16 months [9], [10] or 49% by 2 years [9]. According to a meta-analysis of clinical studies, chemoembolization increases survival in this group of patients up to 19-210 months [9]. However, here, in the intermediate stage, there is

Table 1.
Features of patients.

		n=58	%
Gender	Male	34	58,6
	Female	24	41,4
Degree of liver damage	Child-Pugh A	38	65,5
	Child-Pugh B	20	34,5
HBV and HCV	HBV +	21	36,2
	HCV +	18	31
	Both positive	3	5,1
	Both negative	16	27,6

HBV, hepatitis B virus; HCV, hepatitis C virus.

Table 2.
Distribution by age of patients.

Age (n=50)	Survival (%)			
	less than 1 year	1-year	3-years	5-years
30-39 y (n=2)	50	50	50	0
40-49 y (n=2)	50	50	0	0
50-59 y (n=29)	65,5	37,9	34,4	3,4
60-69 y (n=10)	100	100	0	0
70-79 y (n=7)	85,7	14,3	0	0

a significant heterogeneity of the median of overall survival - from 36–45 months [11], [12] with a good immediate effect of TACE, up to 11 months with no further treatment (placebo group from the study SHARP for BCLC B patients [13].

This article analyzes the results of TACE and its value at the intermediate stage of HCC.

Purpose

To analyze the results of transarterial chemoembolization in the intermediate stage of hepatocellular carcinoma.

Material and methods

The study was conducted on the basis of the JSC «National Scientific Center of Surgery» named after A.N. Syzganov in the period 2013-2018. All subjects underwent blood sampling for routine laboratory tests; alpha-fetoprotein (AFP) level; the presence of hepatitis B, C; ultrasound examination of the liver and CT. When analyzing survival, patients were divided into the following categories: gender, age, degree of liver function damage according to Child-Pugh, the presence of viral hepatitis B and C, and the level of AFP. It is worth noting that the study did not analyze the survival of patients depending on the number and size of HCC nodes, invasion of tumor in the hepatic or portal vein, as well as the number and combination of chemotherapeutic agents during TACE. Statistical calculations were performed using Excel, SPSS Statistics by estimating the survival rate using the Kaplan-Meier method.

Results

The study included 58 patients with HCC in the intermediate stage of BCLC. The average age of the patients was 60.4 years. The follow-up period was 6–64 months. The average duration of stay in the hospital was 7.2 days.

According to statistics, the study prevailed men over women, 34 to 24, respectively. The patients were also distributed according to the degree of liver damage and the results of viral hepatitis in the blood (Table 1).

The procedure of transarterial chemoembolization was carried out with the use of Doxorubicin in dosages of 50 mg in combination with Lipiodol or embolizing microspheres of different diameters. In many cases, TACE was conducted with an intercourse interval of 1.5-2 months. Thus, only 58 patients underwent 103 TACE interventions in isolation, of which 18 patients underwent 2 courses of TACE, 10 patients – 3 courses, 5 patients – 4 courses, 3 patients – 5 courses and in 1 case 6 courses, respectively.

The study period of survival was 6-64 months, the overall survival of the entire cohort of patients correlated with world literature data (Figure 1).

One-year survival after TACE in the total cohort left 42%, 2-years- 15% and 3-years - 5%, respectively. It is worth noting that the patient's comorbid background, as well as complications such as portal vein thrombosis, were not considered here.

The study revealed the following statistically significant differences: the influence of old age (> 60 years old) is directly proportional to the decrease in survival, so in patients over 60 and 70 years old, 3 years and 5 years survival rate was 0%, moreover, the 1-year survival rate of the studied people in the group over 70 years old amounted to 14.3% (Table 2). After chemoembolization, 8 patients subsequently underwent open surgery (liver resection).

Fig 1.
Overall survival in total cohort (n=58).

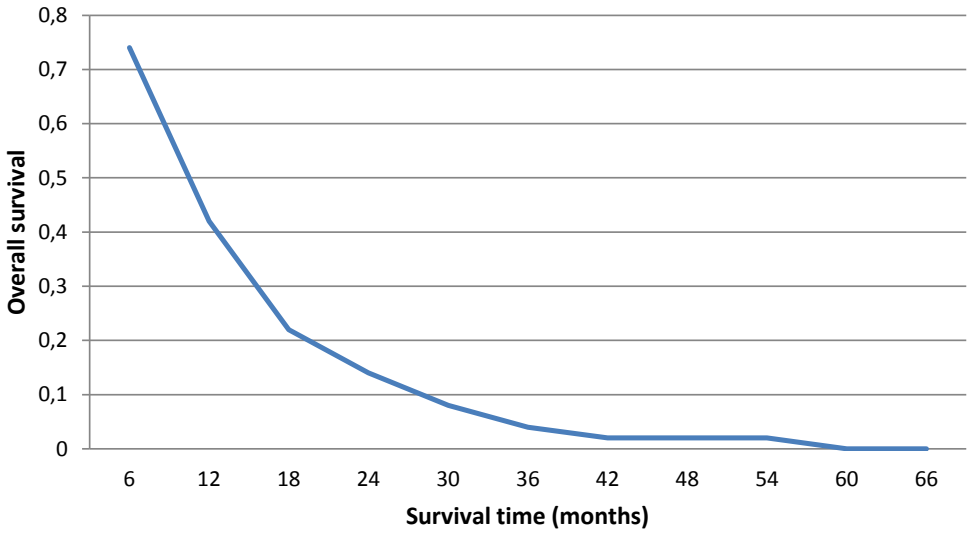

Fig 2.
Distribution by degree of liver function damage.

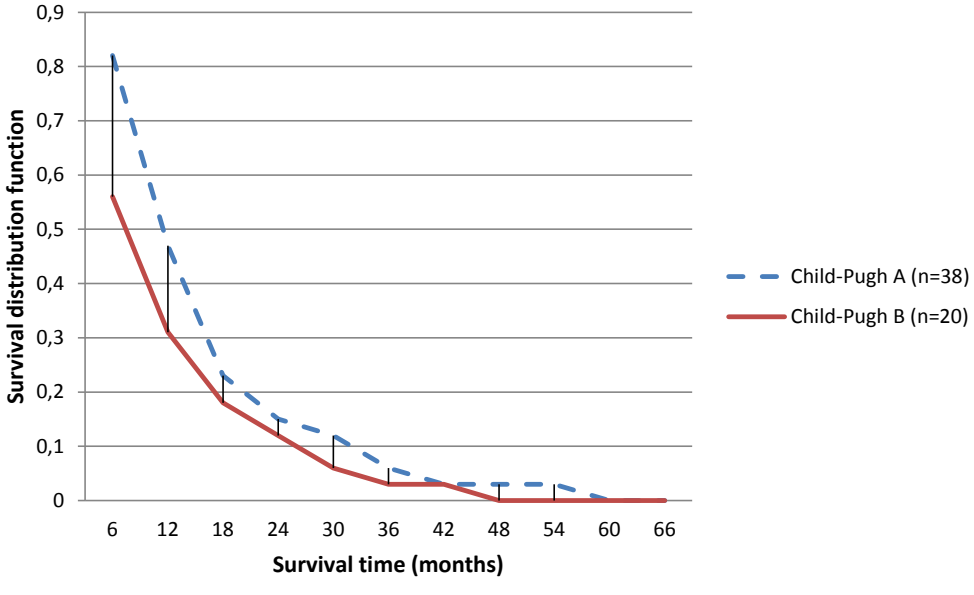

In the distribution of groups according to the degree of liver tissue damage, we used the Child-Pugh standard scale (Figure 2).

Taking into account the impaired liver function, a comparative analysis of patient survival showed the following changes: there were statistically significant differences of 6 month and one year survival, so the percentage of survival among patients in stage B on the Chile-Pugh scale was significantly low in patients with stage A (82% vs. 56% within 6 months and 50% vs. 31% during the one year, respectively). Moreover, one patient from the group with a violation of the liver function of stage A according to Child-Pugh lived up to 5 years.

The average AFP value was 399 IU/ml (12.7-60500 IU/ml), while the median rate was 63.8 IU/ml (Figure 3.). 34 patients were tested to determine the level of AFP in the blood, according to these data, the subjects were divided into 3 groups: group 1 - patients with normal values or with a slight increase of AFP (0-99 IU / ml), group 2d - 100-999 IU/ml and 3th group with a marked increase >1000 IU / ml.

In this category, patients with statistically significant differences were found in the group with a pronounced increase in AFP (> 1000 IU / ml), the Kaplan-Meier survival curve shows a survival rate of 0% after 18 months since the first TACE. Thus, it can be assumed that the level of AFP, in particular, a pronounced increase in its value correlates with a low survival rate.

Six months after the TACE contrast enhanced CT was conducted in 36 patients (Figure 4), of which changes were observed in 21 patients. In 15 patients, there was a positive trend, in the form of a reduction in size or transformation of the formation, in 6 patients, a negative trend was observed in the form of an increase in the size of the formation.

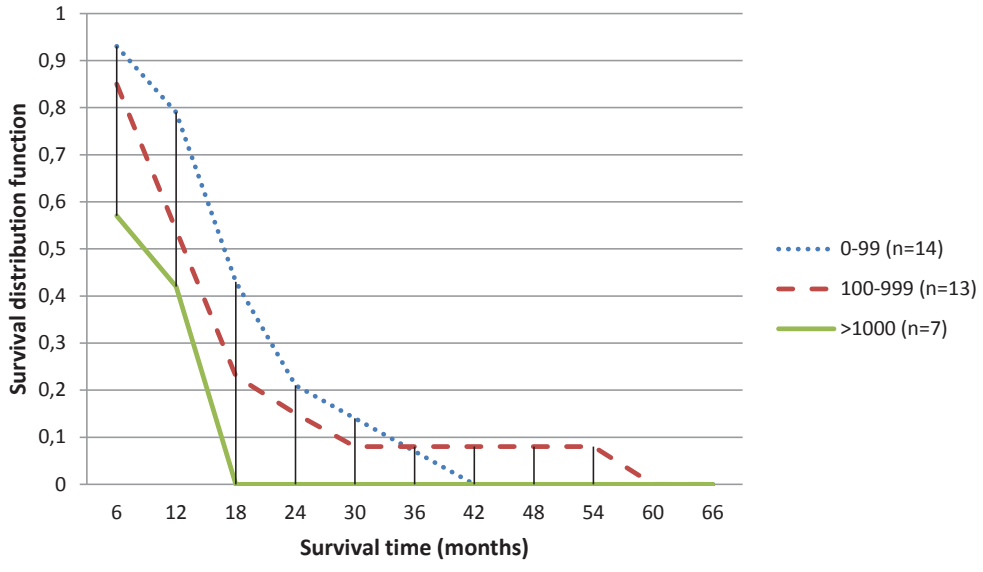

Fig 3.
Distribution by degree of alpha-fetoprotein (IU/ml).

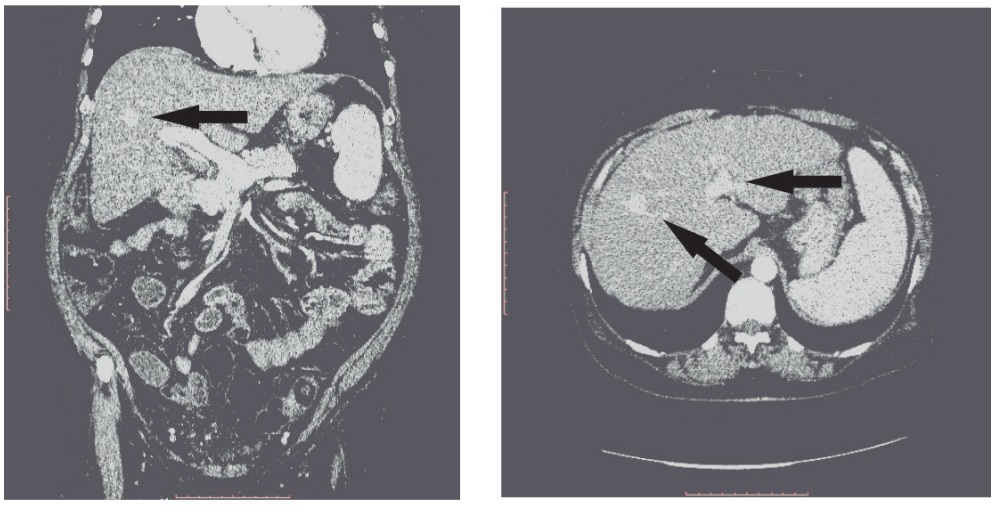

Fig 4.
62 y.o. patient (female). Multinodular form of HCC in SVIII of liver, intensively, unevenly accumulating a contrast agent in the arterial phase.

We would like to note that in this study, the number and size of nodes, the presence of concomitant pathology and the cause of death of the patient were not taken into account, which requires additional observation.

Conclusion

Summarizing the above results, we concluded that, despite the small number of patients studied, TACE showed good results in the intermediate stage of HCC.

Elderly and senile age, a high degree of liver dysfunction, as well as high AFP values are additional factors that dramatically reduce the life expectancy of patients after TACE with HCC in stage B-BCLC.

Active discussions continue between surgeons, interventionists, therapists regarding the priority treatment options for intermediate stage HCC. Undoubtedly, only as a result of constant productive dialogue within a multidisciplinary group can the effectiveness of medical care be increased.

References

1. Siegel R. et al. Cancer statistics, 2014 // CA. Cancer J. Clin. 2014.Vol. 64, № 1. P. 9–29;
2. Ferlay J. et al. Cancer incidence and mortality worldwide: Sources, methods and major patterns in GLOBOCAN2012 // Int. J. Cancer. 2015. Vol. 136, № 5. P. E359–E386;
3. Bray F. et al. Global estimates of cancer prevalence for 27 sites in the adult population in 2008 // Int. J. Cancer. 2013. Vol. 132, № 5. P. 1133–1145;
4. Jin-Kyoung Oh, Hai-Rim Shin, Min Kyung Lim et al. Multiplicative synergistic risk of hepatocellular carcinoma development among hepatitis B and C co-infected subjects in HBV endemic area: a community-based cohort study. BMC Cancer 2012; 12:452;
5. Aliev, M.A., Sultanaliev, T.A., Seisembaev, M.A et al. The diagnosis and surgical treatment of cavernous hemangiomas of the liver. Vestn Khir Im I I Grek 1997; 156(4):12-16;

6. Roccarina D, Majumdar A, Thorburn D, Davidson BR, Tsochatzis E, Gurusamy KS. Management of people with intermediate-stage hepatocellular carcinoma. Cochrane Database of Systematic Reviews 2017, Issue 3. Art. No.: CD011649;
7. Farinati f et al. Early and very early hepatocellular carcinoma: when and how much do staging and choice of treatment really matter? A multi-center study. BMC Cancer 2009; 9: 33
8. Arizumi T. et al. Effectiveness of Sorafenib in Patients with Transcatheter Arterial Chemoembolization (TACE) Refractory and Intermediate-Stage Hepatocellular Carcinoma // Liver Cancer TACE Refract. HCC Liver Cancer. 2015. Vol. 44. P. 253–262
9. Llovet J. M., Bruix J. Systematic review of randomized trials for unresectable hepatocellular carcinoma: Chemoembolization improves survival. // Hepatology. 2003. Vol. 37, № 2. P. 429–442;
10. Lencioni R. Management of hepatocellular carcinoma with transarterial chemoembolization in the era of systemic targeted therapy // Crit. Rev. Oncol. Hematol. Elsevier Ireland Ltd, 2012. Vol. 83, № 2. P. 216–224;
11. Takayasu K. et al. Prospective cohort study of transarterial chemoembolization for unresectable hepatocellular carcinoma in 8510 patients. // Gastroenterology. 2006. Vol. 131, № 2. P. 461–469;
12. Burrel M. et al. Survival of patients with hepatocellular carcinoma treated by transarterial chemoembolisation (TACE) using Drug Eluting Beads. Implications for clinical practice and trial design. //J. Hepatol. 2012. Vol. 56, № 6. P. 1330–1335;
13. Llovet J. M. et al. Sorafenib in advanced hepatocellular carcinoma. // N. Engl. J. Med. 2008. Vol. 359, № 4. P. 378–390.

DETECTION OF CMV INFECTION BY BIOPSY IN RECIPIENTS WITH KIDNEY GRAFT DYSFUNCTION

МРНТИ 76.29.43

Baimakhanov B.B., Ibragimov R.P., Enin E.A., Madadov I.K., Syrymov Zh.M., Belgibaev E.B., Dabyltaeva K.S.
National Scientific Center of Surgery named after A.N. Syzganov, Almaty, Kazakhstan

Abstract
Kidney transplantation is the most effective and preferable treatment option of terminal stage of chronic kidney disease. Nowadays kidney transplantation is well-developed modality and early graft and patient survival rates overall the world greatly increased. But improvement of graft and patient survival rates in long-term period remains to be problem. Beside the immunologic factors that causes either acute or chronic graft rejection, there are another etiologic factors of graft rejection. Infections, particularly wide-spread in solid organ recipients - cytomegalovirus infection (CMV), appears to be one of this etiologic factors. Mechanism of injury of graft by cytomegalovirus remains to be unclear. Diagnostics of CMV is also a difficult objective. In our institution we conducted an investigation aimed the detection of CMV by graft biopsy in patients with graft dysfunction. The main objective of this investigation is the demonstration of efficacy of biopsy in diagnostics of CMV infection in graft dysfunction.

ABOUT THE AUTHORS

B.B.Baimakhanov *– professor, transplant-surgeon, chairman of Board of JSC «NSCS named after A.N.Syzganov» (info@baimakhanov.kz, 87017223381).*
R.P. Ibragimov *– urologist, transplant-surgeon, head of kidney transplantation, urology and nephrology department, scientific manager. (rava747@mail.ru 87017472070)*
E.A. Enin *– pathomorphologist, head of department of pathomorphology (enin66@mail.ru 87018555666).*
I.K. Madadov *– urologist, kidney transplantation, urology and nephrology department (dominic89@mail.ru 87478397110)*
Zh.M. Syrymov *- urologist, kidney transplantation, urology and nephrology department (syrymov89@mail.ru 87072727002)*
E.B.Belgibaev *- urologist, kidney transplantation, urology and nephrology department (dr_beb@mail.ru87759776773)*
K.S. Dabyltaeva *– nephrologist, kidney transplantation, urology and nephrology department. (d_kuralay_s@mail.ru 87027651566)*

Keywords
cytomegalovirus, graft dysfunction, biopsy, kidney transplantation.

Бүйрек трансплантатының дисфункциясы бар реципиенттерде биопсия арқылы ЦМВ инфекциясын анықтау

Баймаханов Б.Б., Ибрагимов Р.П., Енин Е.А., Мададов И.К., Сырымов Ж.М., Белгибаев Е.Б., Дабылтаева Қ.С.
А.Н. Сызғанов атындағы Ұлттық ғылыми хирургия орталығы, Алматы, Қазақстан

Аңдатпа
Бүйрек трансплантациясы созылмалы бүйрек ауруының терминальді сатысының ең эффективті және тандаулы емдеу методы болып саналады. Қазіргі танда бүйрек трансплантациясы жоғары денгейде дамыған және ерте периодтағы трансплантаттың тірі қалу көрсеткіштері бүкіл дүние бойынша қатты жақсарды. Бірақ ұзақ мерзімдегі трансплантаттыҒ тірі қалу көрсеткіштерін жақсарту қиын мәселе болып табылады. Трансплантатты жедел және созылмалы қабылдамау реакциясына себеп болатын иммунологиялық себептерден баска да себептер бар. Сол себептерге инфекция, әсіресе бұндай науқастар арасында кен таралған, цитомегаловирусты инфекция жатады. Цитомегаловирусты инфекцияның трансплантатты зақымдату механизмі қазіргі танда шешілмеген мәселе болып табылады. Цитомегаловирусты инфекцияның диагностикасы да өте қиын тапсырма болып саналады. Біздің орталығымызда жасалып жатқан зерттеудің мақсаты бүйрек трансплантатының дисфункциясы бар науқастарда биопсия арқылы ЦМВ инфекция анықтау. Бұл зерттеудің басты мақсаты трансплантат биопсиясының ЦМВ инфекциясының анықтаудағы тиімділігін дәлелдеу.

АВТОРЛАР ТУРАЛЫ

Б.Б. Баймаханов *– профессор, трансплантолог дәрігері, А.Н. Сызғанов атындағы «Ұлттық ғылыми хирургия орталығы» АҚ-ның басқарма төарағасы (info@baimakhanov.kz,, 87017223381).*
Р. П. Ибрагимов *– уролог-трансплантолог дәрігері, бүйрек трансплантациясы, урология және нефрология бөлімшесінің меңгерушісі, ғылыми жетекші (rava747@mail.ru 87017472070)*
Е. А. Енин *– паторморфолог дәрігері, патоморфология бөлімшесінің меңгерушісі (enin66@mail.ru 87018555666).*
И.К. Мададов *- уролог дәрігері, бүйрек трансплантациясы, урология және нефрология бөлімшесі, кіші ғылыми қызметкер (dominic89@mail.ru 87478397110)*
Ж.М. Сырымов *- уролог дәрігері, бүйрек трансплантациясы, урология және нефрология бөлімшесі (syrymov89@mail.ru 87072727002)*
Е.Б. Белгибаев *- уролог дәрігері, бүйрек трансплантациясы, урология және нефрология бөлімшесі (dr_beb@mail.ru 87759776773)*
Қ.С. Дабылтаева *- нефролог дәрігері, бүйрек трансплантациясы, урология және нефрология бөлімшесі (d_kuralay_s@mail.ru 87027651566)*

Түйін сөздер
цитомегаловирус, трансплантаттыҒ дисфункциясы, биопсия, бүйрек трансплантациясы.

Выявление инфекции ЦМВ с помощью биопсии у реципиентов с дисфункцией почечного трансплантата

Баймаханов Б.Б., Ибрагимов Р.П., Енин Е.А., Мададов И.К., Сырымов Ж.М., Белгибаев Е.Б., Дабылтаева К.С.
Национальный научный центр хирургии им. А.Н. Сызганова, Алматы, Казахстан

ОБ АВТОРАХ

Б.Б.Баймаханов *– профессор, трансплантолог, председатель правления АО «Национального научного центра хирургии им. А.Н. Сызганова» (info@baimakhanov.kz, 87017223381).*
Р. П. Ибрагимов *– уролог-трансплантолог, заведующий отделением трансплантации почек, урологии и нефрологии, руководитель исследования (rava747@mail.ru 87017472070)*
Е.А. Енин *– патоморфолог, заведующий отделением патоморфологии (enin66@mail.ru 87018555666).*
И.К. Мададов *- уролог, отделение трансплантации почек, урологии и нефрологии, младший научный сотрудник (dominic89@mail.ru 87478397110)*
Ж.М. Сырымов *- уролог, отделение трансплантации почек, урологии и нефрологии, (syrymov89@mail.ru 87072727002)*
Е.Б.Белгибаев *- уролог, отделение трансплантации почек, урологии и нефрологии(dr_beb@mail.ru 87759776773)*
К.С.Дабылтаева *– нефролог, отделение трансплантации почек, урологии и нефрологии, (d_kuralay_s@mail.ru 87027651566)*

Ключевые слова
цитомегаловирус, дисфункция трансплантата, биопсия, трансплантация почки.

Аннотация

Трансплантация почки является наиболее эффективным и предпочитаемым методом лечения терминальной стадии хронической болезни почек. На сегодняшний день трансплантация почек развита на высшем уровне и ранняя выживаемость трансплантата и пациента по всему миру значительно возросла. Однако остается проблемой улучшение показателей выживаемости трансплантата и пациента в отдаленном периоде. Помимо иммунологических факторов, влияющих на развитие как острого, так и хронического отторжения трансплантата, имеются и другие причины развития реакции отторжения. К таким факторам можно отнести инфекцию, и, в частности, наиболее распространенную среди данной категории пациентов, цитомегаловирусная инфекция. Остается нерешенным вопросом механизм повреждения трансплантата цитомегаловирусной инфекцией. Также сложной задачей является диагностика цитомегаловирусной инфекции. На базе нашего центра мы провели исследование, целью которой является выявление ЦМВ инфекции с помощью биопсии почечного трансплантата у пациентов с дисфункцией трансплантата. Главной задачей исследования является доказательство эффективности биопсии трансплантата в диагностике ЦМВ инфекции при дисфункциях трансплантата.

Introduction

Kidney transplantation nowadays is the best therapeutic option for end-stage kidney disease. Allograft survival after transplantation has improved substantially over the past few decades dueto improvedtherapeutic management, more precise follow up and increased awareness of patients about their disease [1,2,3]. On the other hand, prevention of infectious complications are now more potent, despite more intense and efficacious immunosuppressive regimen [4].

Despite advances in short-term outcomes after transplantation, long-term allograft survival has improved only minimally. In a large US transplant registry, the yearly attrition rate for allograft failure at 5–10 years after transplant changed between 1989 and 2008, respectively, from 4.7% to 4.3% for liver, from 10.9% to 10.1% for lung and from 6.4% to 5.1% for kidney transplant recipients [5, 6].

In our experience there is also an improvement in graft and patient survival. For instance, 1-year graft survival increased from 59.4% in 2012 to 94.80 % in 2017. Similar increase was seen in rates of 1-year patient survival, from 75% in 2012 to 100 % in 2017.

Chronic allograft dysfunction has multifactorial etiology: immunological (acute and chronic antibody- and T cell–mediated rejection) and non-immunological factors (delayed allograft function, infections, hypertension and others comorbidities) [7-9].

The great majority of renal transplant recipients have latent cytomegalovirus (CMV) infection [10], which in 20–60% of patients causes CMV disease with clinical signs and symptoms of fever, leucopenia and organ involvement [11].

Material and methods

We conducted a retrospective study of 54 kidney transplant patients with graft dysfunction. All patients presented with elevated creatinine, proteinuria,signs of graft rejection on ultrasound. Of all patients, 33 were male and 21 female patients. Mean age was 33.52ұ10.78 years. We performed graft biopsy with Pro*Mag TM Biopsy Needle 16G. All microslides were evaluated for CMV infection.

Biopsy material was sustained in 10% neutral formalin solution.

Furtherly samples were dehydrated by standard method in automatic tissue processor with closed contour Termo SCIENTIFIC Excelsior AS. 4-5ем thick paraffin-embedded sections were made on rotational microtom SakuraAccu-Cut SRM 200.

For a review study hematoxylin staining was made on Termo SCIENTIFIC Gemini AS staining station. Luminescence: section of material was made on cryostat Leica CM 1950, with reagents from TermoFicher Company. Finished microslides

were reviewed by microscope: ZEISS AXIO Imager Z 2 (Germany) with camera Axiocam 506 color and software ZEISS ZEN Imaging Software. Luminescence was performed by Leica DM 4000 B with dark-field microscopy Leica DFC 310 – FX .

Results

All patients were divided into 4 groups according to the results. First group were patients with acute graft rejection (TCMR) (n = 12), the second group – were patients with chronic graft rejection (n=22), the third group – chronic rejection associated with focuses of acute rejection (n=12) and the fourth group – patients with miscellaneous reasons of graft dysfunction (De novo glomerulonephritis, acute tubular necrosis, interstitial nephritis and etc.)(n=8).

All patients were evaluated for serological matchings as to the IgG status (D=donor and R=recipient): D+/R+=45.3%, D-/R+=24.7%, D+/R-=17.4%, and D-/R-=12.6%.

In first group in 2 cases CMV infection was detected, whereas in second group no CMV infection was seen (Pic. 1-2). However, in third group, in patients with chronic graft rejection + focuses of acute rejection also in 2 cases CMV infection was detected (Pic. 3-4). In forth group no CMV infection was detected. Thus, CMV infection can be estimated as the one of the reasons of acute graft rejection, but not chronic rejection or other factors of graft rejection. The cases of acute graft rejection were T-cell mediated rejection (TCMR), that refers to as CMV infection contributes to T cell activation and further rejection, but it is not completely clear the exact mechanism by which it acts.

Discussion

The serological status is a long-term prognostic marker regardless of the development of the disease. When D+/R- are compared with D-/R-, there is a 28% increase in risk of graft loss, 36% in the risk of death due to all causes, and eight-fold the risk of dying by a viral infection. Serological typing, therefore, is indicated for all donors and recipients [12, 13].

Primo-infection refers to new-onset infection and reactivation is considered as activation previouslypersisting infection.CMV disease is characterized by the clinical syndrome in which there are symptoms, such as fever, asthenia, myalgia, leukopenia, thrombocytopenia, or hepatic enzyme alterations, or by the invasive disease, in which there is evidence of viral inclusion in cells of organs or tissues, such as in the gastrointestinal tract, liver, in the renal graft, lungs, bone marrow and retina. The effects of CMV infection can be classified as direct or indirect. The direct effects are infection and disease, as mentioned above. The indirect effects observed are increased risk of secondary infections, such as pneumocystosis and other herpes viruses, and increased risk of acute rejection and of chronic graft dysfunction [14].

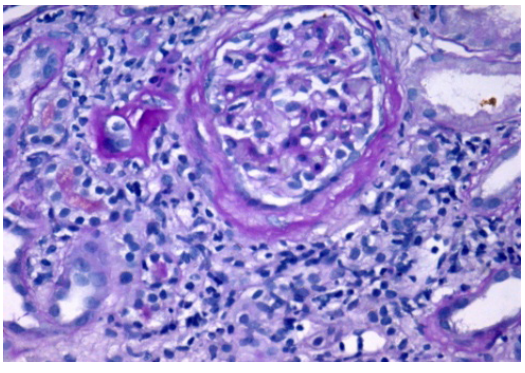

Fig. 1
PAS staining.
Magnification x 200

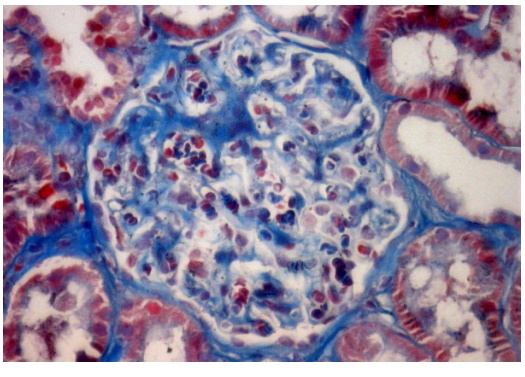

Fig. 2
Azan trichome staining.
Magnification x 200.

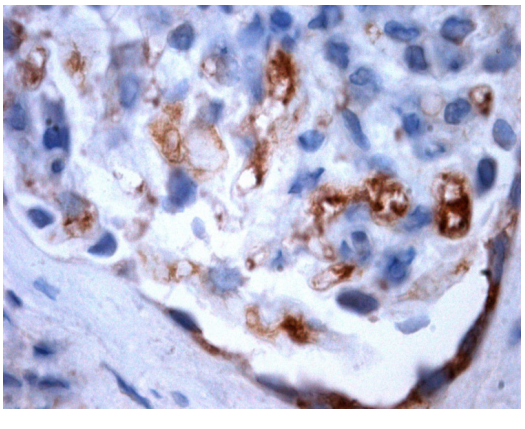

Fig. 3
Immunohistochemistry - C4d. Magnification x 200.

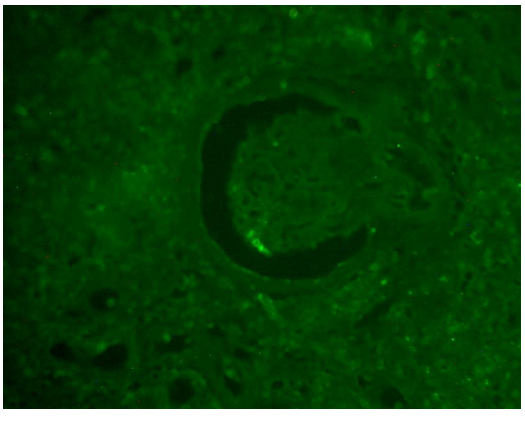

Fig. 4
Immune enzyme assay
CMV g8

Quantitative blood polymerase chain reaction (PCR) for cytomegalovirus (CMV) is used to direct therapy in kidney transplant patients, but cytomegalic inclusions are rarely found in allograft renal biopsies even with an elevated serum creatinine and apparent CMV disease. The relationship between quantitative blood CMV and renal allograft pathology is unknown. Liapis H.et. al. have studied thirteen biopsy samples from patients suspected of CMV disease, who had a buffy coat CMV-PCR drawn within 2-5 days of a renal allograft biopsy for an elevated creatinine. All were evaluated for CMV pathologically, by light microscopy, immunohistochemistry, in situ hybridization and tissue PCR.Qualitative and quantitative buffy coat CMV-PCR were positive in 10/13 (77%) patients. Tissue CMV-PCR was positive in five (50%) biopsies, including two with CMV inclusions and three with no inclusions. Quantitative buffy coat CMV-PCR levels did not correlate with detection of CMV inclusions in renal tissue. Paradoxically, quantitative buffy coat CMV-PCR was low (239 and 538 copies/microg of DNA) when CMV inclusions were detected. All five biopsies with acute rejection were associated with CMV viraemia and two of the five with allograft CMV inclusions. A quantitative buffy coat CMV-PCR of <100 copies/microg of DNA ruled out disease with CMV inclusions [15]. Thus, CMV infection is important predisposing factor for acute allograft rejection after kidney transplantation. The control of CMV infection could decrease episodes of acute kidney rejection [16].

Conclusion

In our experience CMV infection was detected by biopsy only in 20% cases and only in patients with acute graft rejection. It is not completely clear the mechanism of direct effect of CMV in graft tissue but it's obvious that it can be the cause of acute graft rejection. Biopsy proven CMV didn't correlate with PCR results due clinical data but it appears to be essential to perform both graft biopsy and PCR in order to better detect the infection.

References

1. Kim WR, Smith JM, Skeans MA, et al. OPTN/SRTR 2012 annual data report: Liver. Am J Transplant 2014; 14(Suppl 1): 69–96.
2. Matas AJ, Smith JM, Skeans MA, et al. OPTN/SRTR 2012 annual data report: Kidney. Am J Transplant 2014; 14(Suppl 1): 11–44.
3. Pascual M, Theruvath T, Kawai T, Tolkoff-Rubin N, Cosimi AB. Strategies to improve long-term outcomes after renal transplantation. N Engl J Med 2002; 346: 580–590.
4. Fishman JA. Infection in solid-organ transplant recipients. N Engl J Med 2007; 357: 2601–2614.
5. Lodhi SA, Lamb KE, Meier-Kriesche HU. Solid organ allograft survival improvement in the United States: The long-term does not mirror the dramatic short-term success. Am J Transplant 2011; 11: 1226–1235.
6. Lamb KE, Lodhi S, Meier-Kriesche HU. Long-term renal allograft survival in the United States: A critical reappraisal. Am J Transplant 2011; 11: 450–462.
7. Land WG. Chronic allograft dysfunction: A model disorder of innate immunity. Biomed J 2013; 36: 209–228.
8. Razonable RR, Paya CV. Infections and allograft rejection - intertwined complications of organ transplantation. Swiss Med Wkly 2005; 135: 571–573.
9. Shoskes DA. Nonimmunologic renal allograft injury and delayed graft function: Clinical strategies for prevention and treatment. Transplant Proc 2000; 32: 766–768.
10. Ho M. Cytomegalovirus infection and indirect sequelae in the immunocompromised transplant patient. Transplant Proc 2011;23 [Suppl 1]:2–7
11. Hibberd PL, TolkoffŷRubin NE, Cosimi AB et al. Symptomatic cytomegalovirus disease in the cytomegalovirus antibody seropositive renal transplant recipient treated with OKT3. Transplantation,2012;53:68–72.
12. KDIGO clinical practice guideline for the care of kidney transplant recipients: a summary.Kasiske BL, Zeier MG, Chapman JR, Craig JC, Ekberg H, Garvey CA, Green MD, Jha V, Josephson MA, Kiberd BA, Kreis HA, McDonald RA, Newmann JM, Obrador GT, Vincenti FG, Cheung M, Earley A, Raman G, Abariga S, Wagner M, Balk EM, Kidney Disease: Improving Global Outcomes.KidneyInt. 2010 Feb; 77(4):299-311.
13. Prevention of cytomegalovirus disease in recipients of solid-organ transplants.Paya CVClin Infect Dis. 2001 Feb 15; 32(4):596-603.
14. Kotton CN, Fishman JA.Viral infection in the renal transplant recipients. J Am SocNephrol. 2005;16(6):1758–1774. Review.
15. Liapis H1, Storch GA, Hill DA, Rueda J, Brennan DC.CMV infection of the renal allograft is much more common than the pathology indicates: a retrospective analysis of qualitative and quantitative buffy coat CMV-PCR, renal biopsy pathology and tissue CMV-PCR.NephrolDialTransplant. 2003 Feb;18(2):397-402.
16. Boshra Hasanzamani,* Maryam Hami, Vajihe Zolfaghari, Mahtab Torkamani, Mahin Ghorban Sabagh, and Saiideh Ahmadi Simab "The effect of cytomegalovirus infection on acute rejection in kidney transplanted patients" J Renal Inj Prev. 2016; 5(2): 85–88.

CATHETER ABLATION OF THE INCISIONAL TACHYCARDIA AND ATRIAL FIBRILLATION. WHAT ARE THE DIFFICULTIES?

МРНТИ 76.29.30

Bizhanov K.A., Baimbetov A.K.,Yergeshov K.A., Bairamov B.A., Yakupova I.A., Seytbek M.K., Sagatov I.Y.
National Scientific Center of Surgery named after A.N. Syzganov, Almaty, Kazakhstan

Abstract
Mitral valve disease, including dysfunction of the mitral valve, is often accompanied by atrial fibrillation. Among the patients with prosthetic mitral valves, atrial fibrillation occurs in 30-50% cases. Development of atrial arrhythmias and incisional tachycardia in the early and late postoperative periods can significantly influence patients rehabilitation and prognosis. Our clinical case describes a patient with a mechanical mitral valve and incisional tachycardia, which led to progression of heart failure and reduced left ventricular systolic function. The patient underwent a catheter ablation with non-invasive myocardium mapping. The case reveals the potentials of treatment of incisional tachycardia and atrial fibrillation, which do not respond to drug therapy. Modern methods of visualization enable the cardiac surgeons to reduce possible intraoperative risks and development of complications in this group of patients.

ABOUT THE AUTHORS
Bizhanov Kenzhebek Alibekovich *– JSC "NSCS named after A.N. Syzganov", Department of Interventional Cardiology, Arrhythmology and Endovascular Surgery, interventional cardiologist*
Baimbetov Adil Kudaibergenovich *- JSC "NSCS named after A.N. Syzganov", Department of Interventional Cardiology, Arrhythmology and Endovascular Surgery, Head of department, interventional cardiologist*
Yergeshov Kanat Aldabergenuly *- JSC "NSCS named after A.N. Syzganov", Department of Interventional Cardiology, Arrhythmology and Endovascular Surgery, interventional cardiologist*
Bairamov Binali Amrulaevich *- JSC "NSCS named after A.N. Syzganov", Department of Interventional Cardiology, Arrhythmology and Endovascular Surgery, interventional cardiologist*
Yakupova Ilinara Akhmetzhanovna *- JSC "NSCS named after A.N. Syzganov", Department of Interventional Cardiology, Arrhythmology and Endovascular Surgery, cardiologist*
Seitbek Moldir Kudaibergenkyzy *- JSC "NSCS named after A.N. Syzganov", Department of Interventional Cardiology, Arrhythmology and Endovascular Surgery, cardiologist*
7. Sagatov Inkar Yergalievich *– JSC "NSCS named after A.N. Syzganov", Head of Research Management*

Keywords
catheter ablation, chronic rheumatic heart disease, case report; atrial fibrillation; incisional tachycardia; atrial flutter; mitral valve replacement, cardioverter-defibrillator

Инцизиялық тахикардияның және жүрекшелер фибрилляциясының катетерлік аблациясы. Қандай қиындықтар кездеседі?

Бижанов К.Ә., Баимбетов Ә.Қ., Ергешов Қ.А., Байрамов Б.А., Якупова И.А., Сейтбек М.Қ., Сағатов І.Е.
А.Н. Сызғанов атындаы Ұлттық ғылыми хирургия орталығы, Алматы, Қазақстан

Аңдатпа
Қақпақшалық аппараттың патологиясы, оның ішінде митралды қақпақшаның дисфункциясы жиі жүрекшелер фибрилляциямен жүреді. Митральды қақпақшаны алмастыратын науқастар арасында 30-50% жағдайларда жүрекшелер фибрилляциясы болады. Отадан кейінгі ерте және кеш кезеңде жүрекшелік тахиаритмиялар мен инцизиондық тахикардиялардың пайда болуы науқастардың операциядан кейінгі оңалуына мен болжамына елеулі әсер етуі мүмкін. Сол жақ қарынша миокардының систолалық функциясының төмендеуі мен жүрек жеткіліксіздігінің дамуына және декомпенсациясына себеп болған механикалық митралды қақпақша протезі және инцизиондық тахикардиясы бар науқастың клиникалық жағдайын ұсынбақпыз. Науқаста миокардтың инвазивтік емес картасымен катетерлік абляциясы өтті. Бұл клиникалық мысал дәрмекпен емдеуге төзімді инцизиялық тахикардияны және жүрекшелік фибрилляцияны емдеу мүмкіндігін көрсетеді. Интервенциялық визуализациялаудың қазіргі заманғы әдістері ықтимал операциялық қауіптерді және асқыну ықтималдығын барынша азайта алады.

АВТОРЛАР ТУРАЛЫ
Бижанов Кенжебек Әлібекұлы *- А.Н. Сызғанов атындағы ҰҒХО интервенциялық кардиология, аритмология және эндоваскулярлық хирургия бөлімшесінің дәрігері, интервенциялық кардиолог*
Баимбетов Әділ Құдайбергенұлы *- А.Н. Сызғанов атындағы ҰҒХО интервенциялық кардиология, аритмология және эндоваскулярлық хирургия бөлімшесінің меңгерушісі, интервенциялық кардиолог*
Ергешов Қанат Алдабергенұлы *- А.Н. Сызғанов атындағы ҰҒХО интервенциялық кардиология, аритмология және эндоваскулярлық хирургия бөлімшесінің дәрігері, интервенциялық кардиолог*
Байрамов Бинали Амрулаұлы *- А.Н. Сызғанов атындағы ҰҒХО интервенциялық кардиология, аритмология және эндоваскулярлық хирургия бөлімшесінің дәрігері, интервенциялық кардиолог*
Якупова Илинара Ахметжанқызы *- А.Н. Сызғанов атындағы ҰҒХО интервенциялық кардиология, аритмология және эндоваскулярлық хирургия бөлімшесінің дәрігері, кардиолог*
Сейтбек Мөлдір Құдайбергенқызы *- А.Н. Сызғанов атындағы ҰҒХО интервенциялық кардиология, аритмология және эндоваскулярлық хирургия бөлімшесінің дәрігері, кардиолог*
Сағатов Іңкәр Ерғалиұлы *- А.Н. Сызғанов атындағы ҰҒХО ғылыми-зерттеу менеджменті бөлімінің басшысы*

Түйін сөздер
катетерлік аблация, созылмалы ревматикалық жүрек ауруы, клиникалық оқиға; жүрекшелер фибриляциясы; операциядан кейінгі тахикардия; жүрекшелер жыпылықтауы; митралдық қақпақшаны ауыстыру, кардиовертер-дефибриллятор

Катетерная аблация инцизионной тахикардии и фибрилляции предсердий. Какие бывают сложности?

Бижанов К.А., Баимбетов А.К., Ергешов К.А., Байрамов Б.А., Якупова И.А., Сейтбек М.К., Сагатов И.Е.
Национальный научный центр хирургии им. А.Н. Сызганова, Алматы, Казахстан

ОБ АВТОРАХ
Бижанов Кенжебек Алибекович *– отделение интервенционной кардиологии, аритмологии и эндоваскулярной хирургии АО «ННЦХ имени А.Н. Сызганова», интервенционный кардиолог*
Баимбетов Адиль Кудайбергенович *– отделение интервенционной кардиологии, аритмологии и эндоваскулярной хирургии АО «ННЦХ имени А.Н. Сызганова», заведующий отделением, интервенционный кардиолог*
Ергешов Канат Алдабергенович *- отделение интервенционной кардиологии, аритмологии и эндоваскулярной хирургии АО «ННЦХ имени А.Н. Сызганова», интервенционный кардиолог*
Байрамов Бинали Амрулаевич *- отделение интервенционной кардиологии, аритмологии и эндоваскулярной хирургии АО «ННЦХ имени А.Н. Сызганова», интервенционный кардиолог*
Якупова Илинара Ахметжановна *- отделение интервенционной кардиологии, аритмологии и эндоваскулярной хирургии АО «ННЦХ имени А.Н. Сызганова», кардиолог*
Сейтбек Молдир Кудайбергеновна *- отделение интервенционной кардиологии, аритмологии и эндоваскулярной хирургии АО «ННЦХ имени А.Н. Сызганова», кардиолог*
Сагатов Инкар Ергалиевич *– руководитель отдела менеджмента научно-исследовательских работ АО «ННЦХ имени А.Н. Сызганова»*

Ключевые слова
катетерная аблация, хроническая ревматическая болезнь сердца, история болезни; мерцательная аритмия; послеоперационная тахикардия; трепетание предсердий; замена митрального клапана, кардиовертер-дефибриллятор

Аннотация

Патология клапанного аппарата, в том числе дисфункция митрального клапана, часто сопровождается фибрилляцией предсердий. Среди больных с протезированием митрального клапана фибрилляция предсердий встречается в 30-50% случаев. Возникновение предсердных тахиаритмий и инцизионных тахикардий в раннем и отдаленном послеоперационных периодах может существенно влиять на послеоперационную реабилитацию и прогноз больных. Представлен клинический случай пациента с механическим протезом митрального клапана и инцизионной тахикардией, которая явилась причиной прогрессирования и декомпенсации сердечной недостаточности со снижением систолической функции миокарда левого желудочка. Пациенту выполнена катетерная аблация с неинвазивным картированием миокарда. На данном клиническом примере продемонстрированы возможности лечения инцизионной тахикардии и фибрилляции предсердий, резистентных к медикаментозному лечению. Современные методы визуализации вмешательства позволяют минимизировать возможные интраоперационные риски и вероятность развития осложнений.

Introduction

Pathology of the valvular apparatus is one of the most common diseases of the cardiovascular system. According to the Framingham study, the frequency of occurrence of this defect is 19-21% in the population. The failure of the mitral valve (MK) is of the particular interest due to increased prevalence.

Disturbances in the valve lead to electrophysiological and structural changes in the myocardium. Reduction of the refractory period, as well as the appearance of fibrosiscan contribute to the development of cardiac arrhythmias. Thus, in natural course of the disease, atrial fibrillation (AF) develops in 30-84% of patients with mitral valve pathology [1].

The only method that improves the prognosis of such patients is surgical correction of valvular disease, which includes plastic or prosthetic repair of the mitral valve. Surgery can also contribute to increased myocardial trauma. The risk of AF or incisional tachycardia in the postoperative period is not excluded, further worsening the clinical picture and prognosis of patients.

Material and methods

According to the results of a study of 48 patients after mitral valve replacement, patients with a combined mitral valve lesion and sinus rhythm, compared with patients with AF, showed lower diastolic and systolic myocardial stress, which persisted even in a remote period of observation. At the background of sinus rhythm, the processes of reverse myocardial remodeling in patients with prosthetic mitral valve had more favorable course, which is probably due to the recurrent mitral regurgitation [2]. It is also known that the effectiveness of the rehabilitation of patients undergoing plastic surgery or prosthetic repair of the mitral valve is significantly higher in restoring and maintaining sinus rhythm [3].

In case of resistance to drug therapy the radiofrequency ablationis considered to be the possible strategy, which is the most effective treatment for atrial fibrillation.

In recent years, there have been carried out many studies showing the advantage of the surgical approach versus drug therapy. Numerous studies have shown that radiofrequency ablation is much

more effective than antiarrhythmic drugs, and the recently completed CASTLE AF study has only confirmed the need to maintain sinus rhythm, showing not only high efficiency, but also improved prognosis in patients with heart failure and reduced systolic left ventricular function. According to the results of the analysis of 363 (n = 179 / n = 184) patients, the achievement of a combined end point (death or hospitalization for decompensated heart failure) was recorded in 51 patients (28.5%) of the catheter ablation group versus 82 patients (44.6% a) of the group of drug treatment for AF (p = 0.006) [4].

The “Labyrinth-4” procedure in combination with simultaneous correction of mitral valve pathology is indicated as a basic method of treatment in simultaneous diagnosis of mitral valve pathology and AF, however the frequency of using of this technique is small, especially in Kazakhstan [5].

At the same time, there are not so many clinical cases of surgical treatment of AF that occurred in the postoperative period in patients with prosthetic mitral valve [6]. Until recently, such patients were considered to be inoperable: many patients were denied a surgical treatment due to the technical complexity of the procedure and the high risk of complications. While performing the procedure, there is a likelihood of valve lesion, which may require further surgery on the «open» heart.Surgical operations on the «open» heart in the history contribute to the appearance of delayed arrhythmogenic zones that occur most frequently in the cannulation area.Concomitant structural heart disease only contributes to the disruption of rhythm and conduction with changes in the frequency and architectonics of contractions [7].

In our opinion, additional imaging methods are of fundamental importance in the surgical treatment of arrhythmias in patients with mechanical prosthetic mitral valve: intracardiac echocardiography, computer tomography with the possibility of invasive mapping of arrhythmia localization.

The most dangerous complication during the operation is the sticking of the catheter in the mechanical valve, which can lead to adverse and sometimes fatal consequences. In most cases, the probability of this risk is the main reason for the refusal of surgical manipulation.

The purpose of this clinical case is to show the effectiveness of radiofrequency ablation in the treatment of a developed arrhythmia in a patient with a prosthetic mitral valve.

Clinical case

Patient I, 65 years old. In 2010, chronic rheumatic heart disease and mitral valve disease were diagnosed. In 2011, in connection with the development of critical stenosis of mitral valve, he underwent a mitral valve replacement. According to coronary angiography in the same year, the coronary vessels are intact. At the same time, the patient had a gradual decrease in the left ventricular ejection fraction (up to 34%) and dilatation of the cardiac cavities.

In 2016, the patient felt a palpitation and heaviness in the heart area, dyspnea appeared in moderate exertion, edema in the lower extremities. Accord-

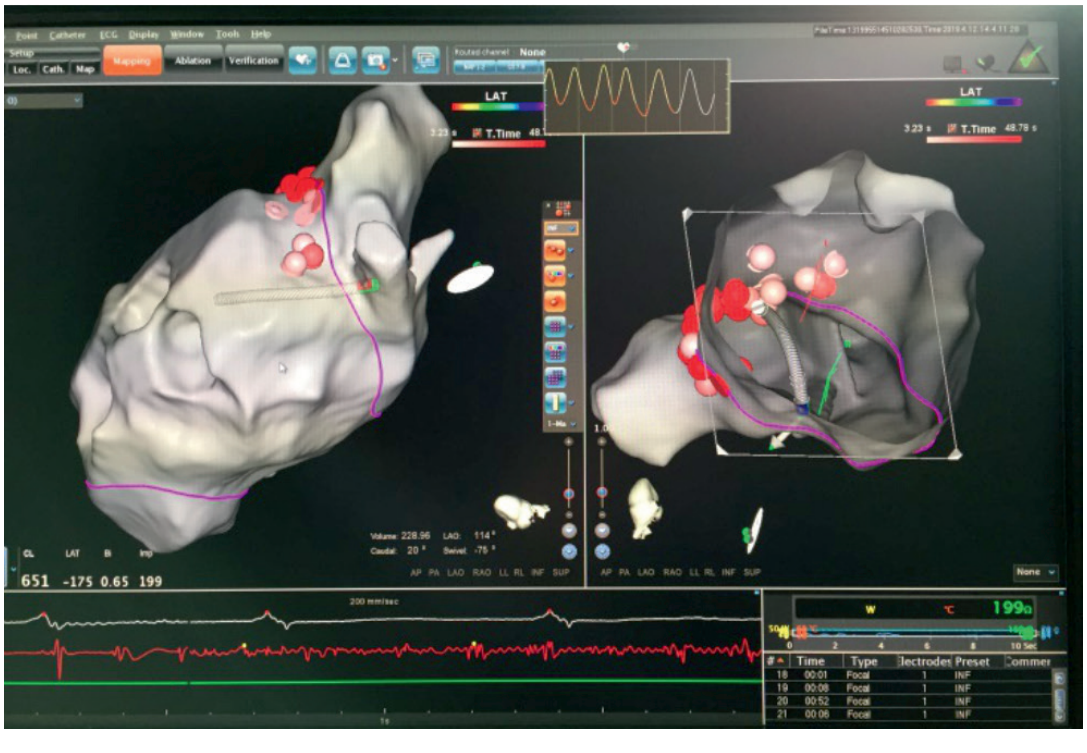

Figure 1.
Ectopic foci according to invasive mapping using the «Carto 3» system

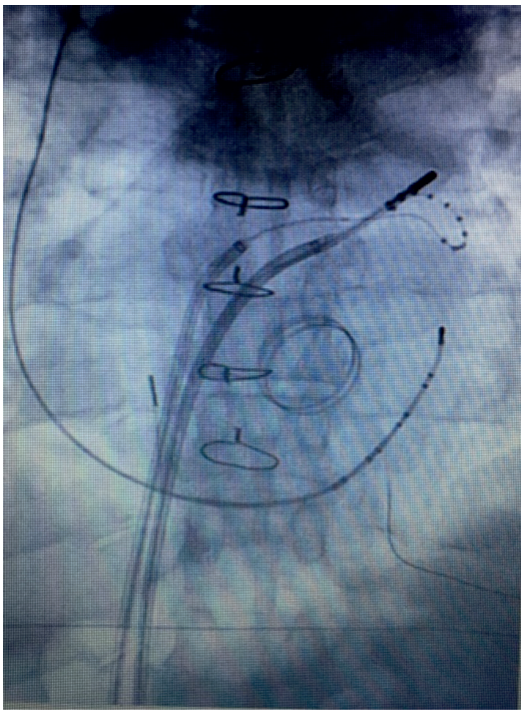

Figure 2. Circular diagnostic 10-pole electrode and ablation electrode at the antrum of the left superior pulmonary vein

ing to ECG, there were atrial flutter, atrial fibrillation, tachysystole. According to EchoCG, the left atrium is 5.6 cm in size, the volume of the left atrium is 134 ml, the ejection fraction is 30%. The average daily heart rate, according to the daily ECG monitoring, is 100 beats/min. Antiarrhythmic therapy had no effect (amiodarone 600 mg / day., further the dose is reduced to 200 mg according to the scheme without any effect; beta-blockers, cardiac glycoside, potassium-sparing and loop diuretics were also added). In connection with the increase of the heart failure, the patient was hospitalized to the hospital and underwent a cardioverter-defibrillator implantation for primary prevention of fatal complications. After implantation, the patient was prepared in a planned order for the next stage of treatment.

Taking into account the signs of decompensation of heart failure that occurred at the background of arrhythmia, and the ineffectiveness of drug treatment, we decided to perform a radiofrequency ablation. Because of sustained episodes of atypical flutter at the background of atrial fibrillation in the first stage, the patient underwent invasive mapping using the «Carto 3» system [11, 12]. There were identified foci of focal activity in the area of the pulmonary veins and right atrium (Fig. 1).

The next step was the isolation of the pulmonary veins, mapping and radiofrequency ablation of atrial flutter. It should be noted that the operation was performed at the background of the target level of the international normalized attitude (INR) of 3.2 at the background of the AVC intake.

After installing a diagnostic electrode in the coronary sinus, an endogram showed the episodes of atrial fibrillation and atrial flutter with the earliest activation point at the distal end of the electrode with a cycle of 365 ms. Under the control of fluoroscopy, the puncture of the interatrial septum was performed; 2 intracardiac introductors were installed into the cavity of the left atrium (Fig. 2). An electropotential map of the left atrium was constructed. A circular 10-pole diagnostic catheter is installed on the pulmonary veins; antral isolation of the pulmonary veins is performed. The next step was the construction of activation maps of the right and left atria. The earliest activation point was detected along the side wall of the right atrium, in the area of the intended cannulation of the superior vena cava. A line through the indicated area is made between the cava veins - a short-term restoration of the sinus rhythm with an instantaneous launch of isthmus-dependent atrial flutter with a cycle of 380 ms. Ablation in the area of the cava-tricuspid isthmus - restoration of sinus rhythm on the impact. This procedure is completed.

The postoperative period was uneventful: the sinus rhythm was maintained, with repeated echocardiography without significant dynamics. The patient was discharged in satisfactory condition. Amiodarone was recommended for 6 months at a dose of 200 mg/day (according to the scheme 5 and 2). At a control visit after 3 months the patient's condition is satisfactory, sinus rhythm, left ventricular ejection fraction of 36%.

During a visit after 6 months, according to ICD and standard ECG, there were atrial fibrillation and blockade of the left leg of the bundle of His. In this connection, the left ventricular electrode was routinely implanted into the patient, the cardioverter-defibrillator was replaced with a cardiac resynchronization device for correcting the heart chronological dissynchrony. According to transthoracic echocardiography, the left ventricular ejection fraction is 37–38%, and heart failure does not progress.

Conclusion

Early diagnosis of AF in mitral valve pathology requiring surgical correction is an important advantage for the patient. According to the literature, intraoperative restoration of sinus rhythm with prosthetic mitral valve demonstrates significant results and the operation «Labyrinth-4» more and more consolidates its position when choosing the appropriate technique [8-10, 13]. Nevertheless, in some cases, atrial fibrillation and incisional tachycardias occur in the postoperative period. The presence of the mechanical mitral valve is the reason for refusing of interventional treatment. Modern possibilities of visual control of invasive operations, such as intracardiac echocardiography, reduce intraop-

erative risks and the likelihood of complications. In maximum control, this technique is most effective. In turn, it should be taken into account that such operations should be carried out in medical institutions, whose specialists perform a large number of catheter interventions per year. The equipment of the operating room and the corresponding experience of the operating team is of equal importance for possible emergency correction in case of development of complications.

References

1. Ivleva O.V., Avdeeva M.V. Influence of mitral valve replacement on functional heart restoration in patients with sinus rhythm and atrial fibrillation. Creative Cardiology = KreativnayaKardiologiya. 2018;12(1):40-9 (in Russ.)
2. Tukusheva E.N., Abdramanov K.A., Urmanbetov K.S.Impact of atrial fibrillation on the evaluation of quality of life following surgical repair of rheumatic mitral valve insufficiency. Novaya nauka: opyt, traditsii, innovatsii. 2016;(10-2):36-43 (in Russ.)
3. Marrouche N.F., Brachmann J., Andresen D., Siebels J., Boersma L., Jordaens L., Merkely B., Pokushalov E., Sanders P., Proff J., Schunkert H., Christ H., Vogt J., Bansch D.; CASTLE-AF Investigators. Catheter ablation for atrial fibrillation with heart failure. N Engl J Med. 2018;378(5):417-427. PMID: 29385358. https://doi.org/10.1056/NEJMoa1707855
4. Abdulianov I.V., Vagizov I.I., Mukharyamov M.N.Efficiency of atrium fibrillation treatment using the method of radiofrequency ablation in the case of patients with surgical treatment of mitral valve.Medicinskijal'manah.2015;(3):54-56. (In Russ.)
5. Wang X., Liu X., Shi H., Gu J., Sun Y., Zhou, L., Hu W. Heart rhythm disorders and pacemakers: Pulmonary vein isolation combined with substrate modification for persistent atrial fibrillation treatment in patients with valvular heart diseases. Heart. 2009;95(21):1773-83. PMID: 19482843. https://doi. org/10.1136/hrt.2007.124594
6. Lang C.C., Santinelli V., Augello G., Ferro A., Gugliotta F., Gulletta S., Vicedomini G., Mesas C., Paglino G., Sala S., Sora N., Mazzone P., Manguso F., Pappone C. Transcatheter radiofrequency ablation of atrial fibrillation in patients with mitral valve prostheses and enlarged atria: safety, feasibility, and efficacy. J Am CollCardiol. 2005;45(6):868-72. PMID: 15766822. https://doi.org/10.1016Zj.jacc.2004.11.057
7. Ad N., Holmes S.D., Massimiano P.S., Rongione A.J., Fornaresio L.M. Long-term outcome following concomitant mitral valve surgery and Cox maze procedure for atrial fibrillation. J Thorac Cardiovasc Surg. 2018;155(3):983-994. PMID: 29246544. PMCID: PMC5933444. https://doi.org/10.1016/j. jtcvs.2017.09.147
8. Ad N., Holmes S.D., Massimiano P.S., Pritchard G., Stone L.E., Henry L. The effect of the Cox-maze procedure for atrial fibrillation concomitant to mitral and tricuspid valve surgery. J Thorac Cardiovasc Surg. 2013;146(6):1426-34. https://doi.org/10.1016/j.jtcvs.2013.08.013
9. Sapelnikov O.V., Cherkashin D.I., Shlevkov N.B., Nikolaeva O.A., Zhambeev A.A., Salami Kh.F., Partigulova A.S., Buldakova N.A., Grishin I.R., Ardus D.F., Stukalova O.V., Uskach T.M., Zhirov I.V., Tereshchenko S.N., Ternovoi S.N., Akchurin R.S. Comparative efficacy of pulmonary vein isolation vs rotor ablation in patients with persistent atrial fibrillation: mid-term results. Kardiologicheskiivestnik. 2017;12(4):38-43. (In Russ.)
10. Baimbetov A., Kuzhukeyev M., Bizhanov K., Yergeshov K., Yakupova I., BozshagulovT., Ismailova G., //Atrial fibrillation ablation using second-generation cryoballoon. Cryoballoon ablation. «The new Armenian medical journal»Vol. 12 (2018), No 1, p. 64-71.
11. Baimbetov A., Bizhanov K., Yergeshov K., Yakupova I., Bozshagulov T. One year continuously monitoring follow up results after single procedure atrial fibrillation ablation using cryoballoon second generation. August 2018, «European Heart Journal» 39 566.P5772

МАСТЕР-КЛАСС В ГОРОДСКОЙ МНОГОПРОФИЛЬНОЙ БОЛЬНИЦЕ Г. ТУРКЕСТАН, ТУРКЕСТАНСКАЯ ОБЛАСТЬ

С 16.05.2019 г. по 17.05.2019 г. сотрудниками Национального научного центра хирургии им. А.Н. Сызганова во главе Председателя правления, д.м.н., профессора Баймаханова Б.Б. прошел мастер-класс в Городской многопрофильной больнице г. Туркестан, Туркестанская область.

В рамках мастер-класса выполнены следующие показательные хирургические операции:

1. Резекция желудка по Бильрот-2;
2. Эксплоративная лапаротомия (Опухоль головки поджелудочной железы с прорастанием в воротную вену);
3. Гепатикоеюностомия на Ру петле;
4. Чрескожная чреспеченочная холангиостомия;
5. Дренирование брюшной полости под УЗИ контролем

В рамках мастер-класса сделаны доклады на следующие актуальные темы:

1. Хирургическое и медикаментозное лечение эхинококкоза печени;
2. Чрескожные декомпресии желчных протоков при механической желтухе;
3. Хирургическая тактика при повреждении желчных протоков после холецистэктомии.

Общее количество участников мастер-класса составило 30 врачей, в основном хирургических специальностей.

МАСТЕР-КЛАСС НА ТЕМУ: «ABLATION INDEX, НОВЫЙ МАРКЕР КАЧЕСТВА И ЭФФЕКТИВНОСТИ АБЛЯЦИОННЫХ ПОРАЖЕНИЙ»

Система CARTO3 – новейшая технология создания изображений, использующая электромагнитное поле для создания 3D-карт сердечно-сосудистой системы пациента в реальном времени. Принцип действия системы Carto – это построение, анализ и выведение на экран монитора электроанатомических карт сердца и совмещение этих карт с местоположением кончика катетера в режиме реального времени и в трехмерном изображении. Высокая точность системы базируется на патентованной технологии, основанной на принципе использования источника магнитного поля, который размещается под столом пациента. В навигационные/лечебные катетеры вмонтирован пассивный сенсор, который дает информацию о местоположении кончика катетера в режиме реального времени. По мере продвижения кончика катетера по миокарду, сенсор собирает местные электрограммы, которые в тот же момент поступают в программный блок CARTO.

Особенность системы в том, что происходит постоянное обновление, а также разработка новых дополнений, для более быстрой и эффективной абляции и картирования. В ННЦХ им. А.Н. Сызганова в течении 2 дней (с 24.05.2019 г. по 25.05.2019 г.) проходил мастер-класс по Радиочастотной абляции устьев легочных вен, с использованием навигационной системы Carto3, с установленным новым модулем Ablation Index.

Индекс абляции - это новый маркер качества повреждения, который использует контактную силу, время и мощность в взвешенной формуле, для получения максимального эффективного поражения в зоне абляции.

Участие в данном мастер-классе приняли представители, а также IT-специалисты компании Biosense Webster, слушатели в лице аритмологов, кардиологов, резидентов ННЦХ им. А.Н. Сызганова и специально приглашенный проктор, к.м.н. Шабанов В.В., заведующий отделением нарушения ритма сердца Национального медицинского исследовательского центра им. Академика Е.Н. Мешалкина (г. Новосибирск, Российская Федерация).

Мастер-класс проходил в формате обучения, поэтому принять участие и собственноручно провести изоляцию устьев легочных вен, под руководством Шабанова В.В., смогли и сотрудники центра. Всего было проведено 6 оперативных вмешательств.

Новый модуль Ablation Index, позволяет нанести достаточное поражение в зоне абляции, при этом снизив время нахождение в данной точке, используя специальную формулу из расчета силы, времени и мощности. Руководствуясь 3 показателями, программа выдает цифру, при которой в данной точке при условии стабильности катетера во время абляции, происходит эффективное повреждение. Данная цифра абсолютно индивидуальна, у каждого специалиста свой индекс абляции, его подбирают после проведения не менее 10 кейсов, программа, учитывая все 10 проведенных абляций, выдает индекс абляции индивидуальный для того или иного специалиста. В рамках данного мастер класса, операции проходили с использованием индекса абляции Шабанова В.В. который составляет 400 при абляции задней стенки и 450 при абляции передней стенки левого предсердия.

По данным исследования “Close” протокол, опубликованном в 2018г., 130 пациентам проведена изоляция устьев легочных вен. Использовался индекса абляции ≥400 при абляции задней стенки и ≥550 при абляции передней стенки. Таким образом, при соблюдении стабильной абляции точка за точкой «point-by-point», сохранении расстояния между точками не более 6 мм и использования данного индекса абляции эффективность оперативного вмешательства была достигнута более 90% через 1 год.

В ННЦХ им. А.Н. Сызганова проводятся все виды аритмологических операций, проводимые в мире, поэтому использование новых технологий является неотъемлемой задачей нашего отделения. В прошедшем мастер-классе приняли участие аритмологи нашего центра, заведующий отделением PhD Баимбетов А.К., Ергешов К.А., Байрамов Б.А., и показали хорошее владение и понимание новейшей технологии картирования и абляции, системы Carto3. С использованием Ablation Index, оперативные вмешательства займут меньше времени и станут более эффективными.

УЧАСТИЕ В КОНФЕРЕНЦИИ INTERNATIONAL DIGESTIVE ENDOSCOPY NETWORK 2019, СЕУЛ, ЮЖНАЯ КОРЕЯ

Врач-эндоскопист АО «ННЦХ им. А.Н. Сызганова» Абдиев Н.М. с 3 по 16 июня 2019 года принял участие в конференции International Digestive Endoscopy Network 2019, Сеул, Южная Корея.

В рамках программы:

1. С 03 по 12 июля Абдиев Н.М. прошел стажировку в Seoul National University Hospital в отделении диагностической и оперативной эндоскопии панкреатобилиарной системы;
2. 13-го июня участвовал в Форуме молодых эндоскопистов с устным докладом «The single-center experience of endoscopic treatment after live-donor liver transplantation».
3. С 14 по 15 июня участвовал в международной конференции International Digestive Endoscopy Network 2019 с постерным докладом «The single-center experience of endoscopic treatment after live-donor liver transplantation».
4. 16 июня на базе Olympus K-TEC прошел практическое обучение навыкам эндоскопической подслизистой диссекции на биомоделях.





МАСТЕР-КЛАСС НА ТЕМУ: «СОВРЕМЕННЫЕ ВОЗМОЖНОСТИ ДИАГНОСТИЧЕСКОЙ И ОПЕРАТИВНОЙ ЭНДОСКОПИИ»

8 июня 2019 г. в АО «ННЦХ имени А.Н. Сызганова» прошел мастер-класс на тему: «Современные возможности диагностической и оперативной эндоскопии»

Менторами выступили:

1. Смирнов А.А., НИИ хирургии и неотложной медицины ПСПБГМУ им. акад. И. П. Павлова, Санкт-Петербург, Россия.
2. Мальков В.А., Санкт-Петербургский государственный университет, клиника медицинских технологий им. Н.И. Пирогова, Санкт-Петербург, Россия.

Более 40 слушателей со всех регионов Казахстана, а также 5 врачей из клиник Кыргызстана и 2 врача из Узбекистана приняли участие в мастер-классе.

В рамках мастер-класса выполнены следующие виды показательных операций:

1. Пероральная эндоскопическая миотомия при ахалазии кардии III степени;
2. Туннельная резекция подслизистого образования пищевода;
3. Эндоскопическая подслизистая диссекция при раннем раке желудка;
4. Пилородуоденальное стентирование при злокачественном стенозе выходного отдела желудка;
5. Стентирование пищевода при злокачественном стенозе пищевода.

А также прошел Hands on training course (отработка практических навыков на тренажерах):

1. Эндоскопическое лигирование и клиппирование;
2. Эндоскопическое стентирование пищевода.

Всем участникам выданы сертификаты.

ПРОФЕССОРУ ЭДИЛЮ АЙДАРХАНОВИЧУ АПСАТАРОВУ 80 ЛЕТ

Глубокоуважаемый Эдиль Айдарханович!

От имени хирургов Казахстана и себя лично с искренней сердечностью поздравляем Вас со славным юбилеем - 80 летием со дня рождения.

Весь Ваш жизненный и трудовой путь - яркий пример преданности выбранной профессии, самоотверженного служения своему народу.

Сейчас Вы занимаете самое высокое и достойное место среди ярких и незаурядных личностей, известных в своей стране и за пределами ее рубежей.

Тому свидетельство множество наград за многолетний безупречный труд. Вы «Заслуженный врач РК», обладатель награды «Золотой скальпель». Вы один из основоположников сосудистой хирургии в Казахстане. Вами организовано первое в Республике сосудистое отделение на базе ЦГКБ, где внедрили 25 восстановительных и реконструктивных сосудистых операции при синдроме Лериша, рентгеноваскулярной гипертензии, аневризмах аорты. Выполнили 150 протезирований абдоминальной аорты при ее осложненных аневризмах.

Всю свою жизнь Вы посвятили хирургии, почти пятьдесят лет подготовке хирургических кадров Республики Казахстан, передавая своим ученикам богатейший практический опыт поливалентного хирурга. Ваши ученики после защиты диссертаций успешно трудятся в учебных заведениях, научно-исследовательских центрах, претворяя в жизнь Ваши идеи и замыслы.

Ваша неутомимая энергия и организаторский талант, высокий профессионализм, умение создать творческую атмосферу в коллективе, принципиальность и требовательность к себе и людям, простота и искренность в общении снискали Вам глубокое уважение среди коллег.

Свой славный юбилей Вы встречаете в окружении своих близких родственников, а также верных своих учеников и друзей из ближнего и дальнего зарубежья.

Желаем Вам человеческого и творческого долголетия.

Председатель правления
РОО «Казахстанское общество хирургов»
профессор
М.А. Сейсембаев

МАМЕДОВ МАГЕРРАМАЛИ МУБАТОВИЧ (К 65-ЛЕТИЮ СО ДНЯ РОЖДЕНИЯ)

Мамедов Магеррамали Мубатович родился 28 июля 1954года в селе Мамаевка, Арысского района, Чимкентской области Республика Казахстан. После ококнчания средней школы, поступил в Ленгерское медицинское училище. В 1973 году поступил Алма-Атинский медицинский институт и 1979 году окончил Алама-Атинский государственный институт Республика Казахстан. В 1979 году прошел интернатуру в Научно-Исследовательском Институте Клинической и Экспериментальной хирургии им.А.Н. Сызганова. С 1979 года по 1982год работал в отделение хирургии печени

В 1982 году поступил в очную аспирантуру во 2 МОЛГМИ им. Н.И. Пирогова на кафедру общей хирургии. В1985 году успешно защитил кандидатскую диссертацию на тему «Использование высокоэнергетических лазеров в хирургии внепеченочных путей». С 1985г по 1987г работал старшим научным сотрудником отделения пищевода, желудка и средостения; С 1986 года по 1988 годы старший научный сотрудник отделения хирургии печени. С 1990-1992 года заведующий отделением лазерной хирургии. В 1992 году по семейным обстоятельствам выехал в другую республику-Азербайджан. С 1992 по 1995 г работал врачом-хирургом в госпитале МВД Азербайджанской Республики, участвовал в военно-боевых действиях в Нагорно-Карабахском конфликте. С 1995 года по 2005 года работал- заведующий отделения гнойно-септической хирургии.

В 2004 году защитил докторскую диссертацию на тему» Комплексное хирургическое лечение полостных образований печени». С 1996 года член лазерной ассоциации России. С 2005 года академик Лазерной Академии Наук Российской Федерации, с 1995 по 2005 работал заведующий отделением гнойно-септической хирургии в Научном центре хирургии им. М.А. Топчибашева. С 2006 года старший научный сотрудник отделения хирургии печени, желчных путей и поджелудочной железы. С 2011 года профессор, заведующий отделом хирургической колопроктологии. Опубликованы в печати 211 научных работ, 6 монографий, 11 патентов и 23 рационализаторских предложений.

Научный руководитель 12 кандидатских и 5докторской диссертаций. Член редакционной коллегии журнала «Центрально-Азиатского медицинского журнала. Бишкек. Киргизстан, член редакционного совета журнала» Вестник Хирургии Казахстана» член редакционного совета журнала» Лазерная медицина» Москва, член редакционного совета журнала Хирургия им. Н.И. Пирогова. Москва до февраля 2012г, член редакционной коллегии журнала «Современные медицинские достижения Азербайджана.

В свой юбилей Магеррамали Мубатович по прежнему является хирургом, педагогом и наставником молодежи, пользуется заслуженным авторитетом среди коллег и уважением пациентов.

Коллектив Журнала «Вестник Хирургии Казахстана» поздравляет проф. Мамедова М.М. с Юбилеем и желает крепкого здоровья, большого счастья, дальнейших творческих удач и совершения задуманных планов.

К 85 ЛЕТИЮ АКАДЕМИКА РАЕН, ПРОФЕССОРА Г.Н. АНДРЕЕВА

Г.Н. Андреев родился 7.01.1934 года, в селе Никольском Оренбургской области, в семье служащих. Отец- Николай Емельянович Андреев, доктор химических наук, известный партийный работник, парторг ЦК Березниковского химического комбината Мордовской АССР (теперь Пермская область). Репрессирован в 1937 году. Мать-Фаина Даниловна Концевая-Андреева – преподаватель истории и географии средней школы, парторг школы. Репрессирована в 1938 году, сослана в Казахстан, в Актюбинскую область.

Г.Н. Андреев закончил среднюю школу в 1951 году с серебрянной медалью в пос. Шубар-Кудук, Актюбинской области. В связи с тем, что был сыном репрессированных родителей Андреев Г.Н. не был допущен к конкурсу для поступления в Военно-медицинскую Морскую Академию. В том же году поступил на лечебный факультет Казахского Государственного медицинского института города Алма-Аты, который закончил с отличием в 1957 году. Был рекомендован в аспирантуру, но по комсомольской путевке уехал работать в Хобдинскую районную больницу Актюбинской области, где проработал 5 лет.

В 1962 году Г.Н.Андреев поступил в клиническую ординатуру на кафедру госпитальной хирургии Алма-Атинского Государственного медицинского института, возглавляемую заслуженным деятелем науки, доктором медицинских наук, профессором М.И.Брякиным. По окончании клинической ординатуры был оставлен на кафедре аспирантом. В 1968 году защитил кандидатскую диссертацию, которая была посвящена экспериментально-клиническому изучению результатов операции Нобля, как метода лечения спаечной кишечной непроходимости. Модификация энтеропликации, предложенная Г.Н. Андреевым, заняла свое место в лечении спаечной кишечной непроходимости.

В 1968 г. прошел по конкурсу ассистентом кафедры госпитальной хирургии, отвечал за лечебную и научную работу

С 1971 года бессменно руководил научным студенческим кружком кафедры, был членом совета НИРС лечебного факультета и института.

В 1981 году на базе БСМП был организован Республиканский центр хирургии портальной гипертензии Казахстана как филиал Всесоюзного центра портальной гипертензии, где продолжались многосторонние клинические исследования различных осложнений портальной гипертензии. Руководимый Г.Н.Андреевым центр был признан лучшим в СССР академиком Б.В.Петровским.

В 1990 году во втором Московском медицинском институте имени И.М. Сеченова Г.Н.Андреевым была защищена докторская диссертация на тему «Диагностика и лечение осложнений портальной гипертензии»

С 1997 года профессор Г.Н.Андреев работал по контракту в институте медицинского образования, НовГу, на кафедре госпитальной хирургии в городе Великий Новгород.

Профессор Г.Н. Андреев автор 524 публикаций, посвященных вопросам ургентной хирургии и портальной гипертензии, в т.ч. 24 монографии. Под его редакцией вышло 2 учебных пособия для студентов старших курсов медицинских институтов, 28 научных и учебно методических рекомендаций, капитальное руководство по гепатологии с курсом клинической биохимии.

Под руководством профессора Г.Н. Андреева было защищено 5 докторских и 24 кандидатских диссертаций, из них 2 докторские, 12 кандидатских посвящены проблеме портальной гипертензии.

В 1998 году профессор Г.Н.Андреев избран академиком Российской Академии естественных наук, с 1996 года действительный член Ассоциации хирургов стран СНГ имени Н.И.Пирогова, Международной Ассоциации хирургов-гепатологов, интернационального клуба гастроэнтерологов-гепатологов.Профессор Г.Н.Андреев дважды награжден почетным знаком «Отличника здравоохранения СССР» (1961 и 1990 годы), медалью ветерана труда СССР(1990 год). В 2007 году Г.Н. Андреев был объявлен «Человеком года.»

В 2009 г. профессору Г.Н. Андрееву присвоено звание «Заслуженный деятель науки РФ»

Работая в Новгородском университете, профессор Г.Н.Андреев готовил научные кадры не только, для северо-запада России, но и для Республики Казахстан. Под его руководством защищены 5 кандидатских диссертаций преподавателями Казахского Национального медицинского университета им.С.Д.Асфендиарова. Профессор Г.Н. Андреев создал школу гепатологов РК и северо-запада России.Всю свою жизнь профессор Геннадий Николаевич посвятил делу спасения человеческих жизней, ибо ему было свойственно глубокое сострадание к пациентам, их боли, человечность и бескорыстие. Он воспитал не одно поколение своих последователей и многочисленных учеников, хирургов, как в России, так и в ближнем зарубежье, которые продолжают дело своего любимого учителя, не нарушая преемственности его дела.

Скоропостижная смерть прервала научно-практическую деятельность академика РАЕН,заслуженного деятеля РФ,доктора медицинских наук,профессора Геннадия Николаевича Андреева, в 2009г. По книгам Г.Н.Андреева учатся врачи, студенты медицинских вузов РФ,республики Казахстана,создают модели портальной гипертензии в эксперименте.

Ученики проф. Г.Н.Андреева успешно выполняют трансплантации печени на уровне мировых стандартов.

Профессор А.С. Ибадильдин
Кмн С.А.Ибадильдина

ПРОФЕССОР ТЛЕУФ БАЗАРКАН ДОСУМБЕКОВИЧ (К 80-ЛЕТИЮ СО ДНЯ РОЖДЕНИЯ)

Исполняется 80 лет со дня рождения известному хирургу, ученому и педагогу, доктору медицинских наук, профессору Базаркану Досумбековичу Тлеуф.

Б.Д.Тлеуф родился 6 августа 1939 г. в д. Пастуханово Челябинской области. После окончания средней школы в 1957 г. по конкурсу поступил в Свердловский государственный медицинский институт, который закончил в 1963г. По направлению ВУЗа до 1967г. работал врачом-хирургом МСЧ в г. Верхняя Салда (РСФСР). Далее в связи с переездом в Алма-Ату, в 1967-принят на должность научного сотрудника КазНИИОиР, где принимал активное участие в разработке проблем эпидемиологии злокачественных опухолей в Казахстане. В 1971г. под руководством проф. С.Н. Нугманова в Онкоцентре г.Москва защитил кандидатскую диссертацию.

С 1972 по1974г.г. по направлению Минздрава СССР он работает врачом-хирургом в Республиканском госпитале г. Аден (НДРЙ), оказывал медицинскую помощь местному населению и дипломатическим работникам.

В 1975 принят по конкурсу на должность ассистента кафедры онкологии АГМИ. В 1976-1982г.г. работал доцентом кафедры хирургии АГИУВ.

С 1982 по1987г.г. Б.Д.Тлеуф работая в должности Главного хирурга Минздрава КазССР внес значительный вклад в организацию и совершенствование хирургической помощи населению республики.

В 1986 по конкурсу принят на должность заведующего кафедрой хирургии АГИУВ. Откуда в 1989 г. направлен в целевую докторантуру во Всесоюзный центр лазерной медицины (г. Москва). Под руководством проф. О.К. Скобелкина в 1991г. защитил докторскую диссертацию на тему: «Лазерный механический шов в желудочно-кишечной хирургии».

В дальнейшем до выхода на пенсию в 2001г. он занимает должность профессора кафедры хирургии АГИУВ.

На счету профессора Б.Д.Тлеуф тысячи сложнейших операций и спасенных жизней. Он пользуется заслуженным признанием коллег и многочисленных пациентов.

В течение 25 лет работы на кафедре хирургии АГИУВ профессор Б.Д.Тлеуф щедро передавал знания и накопленный опыт коллегам: врачам-хирургам Казахстана и других союзных республик.

С 2001 по 2016 г.г. профессор Б.Д.Тлеуф, будучи на пенсии, продолжал активную хирургическую деятельность в условиях частной клиники «Гиппократ» г. Костанай, помогая практическим врачам в освоении последних достижений современной медицинской науки и практики.

Б.Д.Тлеуф – автор более 130 научных работ по различным проблемам онкологии и хирургии . Им опубликованы монографии: «Асқынған бауыр циррозынын кешенді емдеу» (1996г.), «Лазер в желудочно-кишечной хирургии» (1991г.) и три методических рекомендации. Он является автором трех изобретений и 10 рационализаторских предложений. Под его научным руководством защищена одна кандидатская диссертация.

Б.Д.Тлеуф в течение ряда лет состоял членом редколегии журнала «Здравоохранение Казахстана» и был председателем Научного общества хирургов г.Алма-Аты и Алма-Атинской области.

Профессор Б.Д.Тлеуф – действительный член Ассоциации им. Н.И.Пирогова с1992г. и Международной ассоциации хирургов с 2000г.

За заслуги в области хирургии награжден нагрудными знаками Минздрава СССР «Отличнику здравоохранения» (1980г.) и Агентства по здравоохранению РК «Казахстан Республикасы денсаулык сактау ісінін үздігіне (1999г.).

За вклад и заслуги в медицине профессор Б.Д.Тлеуф награжден Золотой медалью А. Н. Сызганова (2017г.); Юбилейной медалью за вклад в развитие АГИУВ (2013г.) и Юбилейной медалью ЦГКБ г. Алматы (2014г.).

В период работы, в практическом здравоохранении Костанайской области награждался грамотами акимата «За многолетний добросовестный труд в системе здравоохранения (2009г.) и « За заслуги в развитии здравоохранения области (2016г.) .

Свой юбилей профессор Б.Д.Тлеуф встречает на заслуженном отдыхе, поддерживая связь с бывшими коллегами и друзьями, в кругу родных и близких, внуков и правнуков.

Профессор Ибадильдин А.С.
кмн. Ибадильдина С.А.

Ассоциация хирургов Казахстана, Редколлегия журнала поздравляют Юбиляра, желают крепкого здоровья, счастливого долголетия и благополучия семье и близким.

КЫЖЫРОВ ЖАНБАЙ НАЛТАЙХАНОВИЧ

Кыжыров Жанбай Налтайханович родился 16 февраля 1959 году в совхозе Красная звезда Жанакорганского района Кызылординской области.

В1964г. пошел в первый класс и закончил школу в 1974 г., в возрасте 15лет. Мечтая о карьере летчика он три года подряд поступал в училище гражданской авиации в г. Актюбинск. Объективные и субъективные факторы помешали реализации мечты. Для поступления в вуз был необходим стаж работы на селе, и он работал плотником в своем совхозе. В 1978 году был призван в армию, через год был направлен в Демократическую республику Афганистан. Участвовал в боевых действиях, имеет боевые награды - орден «За воинскую доблесть», медали России и Республики Казахстан.

По направлению из армии, Кыжыров Ж.Н., в 1982г. поступил на подготовительный курс Алматинского государственного медицинского института, по окончании которого в 1983 г. был зачислен на лечебный факультет АГМИ. В годы учебы он был избран комендантом общежития и навел порядок, дисциплину. В 1989 году закончил АГМИ и поступил в клиническую ординатуру НЦХ им. А.Н. Сызганова. После успешного окончания клинической ординатуры был оставлен в НЦХ им. А.Н. Сызганова заведующим отделения операционного блока. С 1994 г. работал ассистентом кафедры госпитальной хирургии Казахского государственного медицинского университета им. С.Д. Асфендиярова пройдя по конкурсу. В 1995 году, под руководством академика НАН РК, профессора М.А. Алиева, защитил кандидатскую диссертацию на тему «Диагностика и лечение сочетанных повреждений пищевода и желудка».

С 2001 г. ассистент кафедры «Хирургических болезней №2» Казахского Национального медицинского университета им. С.Д. Асфендиярова. В 2009 году защитил докторскую диссертацию на тему «Диагностика и хирургическое лечение заболеваний щитовидной железы». С 2010 году профессор, а с 2011 года, заведующий кафедрой общей хирургии.

В 2015г. назначен, до избрания по конкурсу, заведующим кафедрой госпитальной хирургии с курсом сосудистой хирургии» КазНМУ им. С.Д. Асфендиярова. Научные интересы у профессора Кыжырова Ж.Н. обширны, опубликовано более 150 научных трудов в международных и республиканских изданиях по различным разделам хирургии, издал монографию по хирургии пищевода. Организовывал, выступал с докладами на конгрессах, съездах, Республиканских конференциях и заседаниях хирургического общества г. Алматы и Алматинской области. Лекции он читал и на государственном, и на русском языках, тезисы раздавались студентам. В 2015 году. на конкурсе клинических кафедр КазНМУ,

Кыжыров Жанбай Налтайханович был признан лучшим профессором Университета.

Кыжыров Жанбай Налтайханович прожил 57 лет, наполненную радостью жизни, научного поиска, достижений, общения с друзьями, любимой семьей. Он любил полнокровную жизнь, был всегда активным и доброжелательным. 3 декабря 2017 года скоропостижно его не стало. В сердцах коллег, друзей, родных осталась неизгладимая память о Жанбае Налтайхановиче как о прекрасном специалисте и человеке высокой нравственности.

У профессора Кыжырова Жанбая Налтайхановича прекрасная семья, супруга врач, две дочери и сын. Старшие дети определились с выбором профессии и создали семьи. Младший сын решил продолжить династию врачей и идти по, профессорским, стопам отца.

Профессор Ибадильдин А.С.

ТРЕБОВАНИЯ ДЛЯ АВТОРОВ ЖУРНАЛА «ВЕСТНИК ХИРУРГИИ КАЗАХСТАНА»

Уважаемые авторы!

С 1 апреля 2018 года все статьи на публикацию принимаются на государственном или русском языках с обязательным переводом всей статьи на английский язык. Статьи без версии на английском языке будут отклонены.

Также учитывая требования Консультативной Комиссией (CSAB) Scopus об интернационализации авторов и аудитории редколлегия журналов рекомендуют публиковать статьи в соавторстве с учеными дальнего и ближнего зарубежья.

В журнале публикуются научные статьи и заметки, экспресс-сообщения о результатах исследований в различных областях естественно-технических и общественных наук.

Решение о публикации принимается редакционной коллегией журнала после рецензирования, учитывая научную значимость и актуальность представленных материалов. Статьи, отклоненные редакционной коллегией, повторно не принимаются и не рассматриваются. Рукописи, оформленные не по правилам, возвращаются авторам без рассмотрения.

Рукопись направляется на отзыв члену редколлегии и одному из указанных рецензентов; в спорных случаях по усмотрению редколлегии привлекаются дополнительные рецензенты; на основании экспертных заключений редколлегия определяет дальнейшую судьбу рукописи: принятие к публикации в представленном виде, необходимость доработки или отклонение. В случае необходимости рукопись направляется авторам на доработку по замечаниям рецензентов и редакторов, после чего она повторно рецензируется, и редколлегия вновь решает вопрос о приемлемости рукописи для публикации. Переработанная рукопись должная быть возвращена в редакцию в течение месяца после получения авторами отзывов; в противном случае рукопись рассматривается как вновь поступившая. Рукопись, получившая недостаточно высокие оценки при рецензировании, отклоняется как не соответствующая уровню или профилю публикаций журнала.

Авторы несут ответственность за достоверность и значимость научных результатов и актуальность научного содержания работ. Не допускается **ПЛАГИАТ** – умышленно совершаемое физическим лицом незаконное использование чужого творческого труда, с доведением до других лиц ложных сведений о себе как о действительном авторе.

Редакция принимает на рассмотрение рукописи только на английском языке, присланные через официальный сайт журнала **www.vhk.kz.**

Материал статьи – абстракт на казахском, русском и английском языках, список литературы, рисунки, подписи к рисункам и таблицы, оформляется одним файлом; дополнительно каждый рисунок оформляется в виде отдельного файла. Если пересылаемый материал велик по объему, следует использовать программы для архивирования. Все страницы рукописи, в том числе таблицы, список литературы, рисунки и подписи к ним, следует пронумеровать.

Представленные для опубликования материалы должны удовлетворять следующим требованиям:

1. Содержать результаты оригинальных научных исследований по актуальным проблемам в области физики, математики, механики, информатики, биологии, медицины, геологии, химии, экологии, общественных и гуманитарных наук, ранее не опубликованные и не предназначенные к публикации в других изданиях. Статья сопровождается разрешением на опубликование от учреждения, в котором выполнено исследование.
2. Размер статьи 7-10 страниц (статьи обзорного характера – 15-20 стр.), включая аннотацию в начале статьи перед основным текстом, которая должна отражать цель работы, метод или методологию проведения работы, результаты работы, область применения результатов, выводы (**аннотация** не менее **20** предложений (150»300 слов) - (на английском языке) через 1 компьютерный интервал), таблицы, рисунки, список литературы (через 1 компьютерный интервал, размер шрифта – 14), напечатанных в редакторе Word, шрифтом Times New Roman, поля – верхнее и нижнее – 2 см, левое –3 см, правое –1,5 см. Количество рисунков – 5-10.

Структура должна соответствовать международной формуле IMRAD, где I – introduction (вступление), M – Methods (методы), R – Results (исследование), A – и, D – conclusion+ discussion (заключение, обсуждение результатов и выводы).

Название • Отображает суть работы • Краткое • Без аббревиатур.

Необходимо официально закрепить название организации на английском и сокращение

Резюме • Структурировано • Без аббревиатур • Передает структуру статьи – Зачем (актуальность) – Какими методами? – Что получено – Как это изменило картину знаний. Именно его читают в первую очередь, только хорошее резюме может привлечь внимание!

Вступление • Актуальность работы • Какая задача поставлена • Почему

Методы • Перечисление • Если известные - дать ссылку • Если модифицировали – указать как • Описывать так что б могли повторить • Статистика!

Результаты • Допускается не хронологическое, а логическое повествование • Основные, а не все что были сделаны •

Иллюстрируются минимально необходимыми сводными данными (исходные могут быть в дополнительных материалах)

Обсуждения • Не повторять результаты • Сопоставить полученные данные с имеющимися • Обсудить возможные причины и следствия

Функции списка литературы: • Аргументировать идею • Сопоставить с существующими аналогами • Обозначить место данного исследования • Избежать плагиата • Для журнала и ученого = признание • Часто указаны только собственные работы или очень старые (самоцитирование допускается только 10-15% от общего списка литературы) • Кочующие ошибки

Различайте • Ссылки • Список литературы • Библиография

Что могут цитировать • Книги, (монографии, главы) • Статьи научных журналов • Материалы конференций • Патенты • Диссертации • Неопубликованные данные • СМИ • Веб ресурсы (протоколы, веб странички) Источник должен быть надежным и легко доступным.

Статья начинается на английском языке. В начале, посередине страницы, идет название статьи прописными жирными буквами, название статьи должно быть коротким и емким, согласно проведенного анализа около 30-40 символов на английском языке.

Далее на следующей строчке – инициалы и фамилии авторов обычным жирным шрифтом, затем на следующей строчке – название организации(ий), в которой выполнена работа, город, страна, затем на новой строчке – адреса E-mail авторов. С красной строки идут ключевые слова **(Key words),** а на новой строчке – сама аннотация (**Abstract** – не менее **150** и более **300 слов**).

Далее, после отбивки одной строки, начинается на русском языке. В начале статьи вверху слева следует указать индекс **УДК, МРНТИ.**

Затем, посередине страницы, пишется: 1) название статьи; 2) авторы; 3) название организации; с красной строки – **Ключевые слова,** затем – **Аннотация** (оформление шрифтов, как на английском языке).

Отбиваем одну строку и начинается сама **статья.** Следом за статьей идет список **Литературы.** Ссылки на литературные источники даются цифрами в прямых скобках по мере упоминания (не менее 20).

Для каждой статьи обязателен DOI (Digital Object Identifier) - это цифровой идентификатор документа. DOI выполняет функцию гиперссылки, которая всегда помогает найти нужный документ, даже если сайт, где он находился ранее, был впоследствии изменен. Благодаря этому индексу поиск научной информации в Интернете стал проще и эффективнее. Каждое издание, журнал размещает на своих веб-страницах в интернете, как текущие, так и архивные номера, и материалы. Таким образом, в открытом доступе можно увидеть резюме, которые включают в себя название статьи, фамилию, имя, отчество автора, аннотацию и ключевые слова, место выполнения работы, а также выходные данные опубликованных статей (название журнала, год издания, том, номер, страница).

Список литературы оформляется следующим образом:

В ссылках на книги указывается ISBN (10- или 13-значный). Сокращаются названия только тех журналов, которые указаны: http://images.webofknowledge.com/WOK46/help/WOS/0-9_abrvjt.html.

Для всех ссылок на статьи, опубликованные в международных рецензируемых журналах следует указывать DOI (Digital Object Identifier). DOI указываются в PDF версии статьи и/или на основной интернет-странице статьи, также можно воспользоваться системой поиска CrossRef: http://www.crossref.org/guestquery/. Ниже приводятся примеры оформления ссылок:

Статья в международном журнале:

1. Campry TS, Anders T. (1987) SNAP receptors implicated in vesicle targeting and fusion, Environ Pollut, 43:195-207. DOI: 10.1016/0269-7491(87)90156-4 (in Eng)

Статья в русскоязычном журнале, не имеющая англоязычной версии:

2. Ivanova TV, Samoilova NF (2009) Electrochemical Energetics [Elektrohimicheskaya energetika] 9:188-189. (In Russian)

Книги:

Timrat TA (2008) Soil pollution: origins, monitoring and remediation, second edition. Springer, Germany. ISBN: 978-3-540-70777-6

Материалы конференции:

Monin S.A. (2012) Treatment techniques of oil-contaminated soil and water aquifers. Proceedings of International Conference on Water Resources and Arid Environment, Riyadh, Saudi Arabia. P.123.

Патенты:

Barin AB, Mukamedzhan NT (2000) A method for determination of 1,1-dimethylhydrazine and nitrosodimethylamine [Metodopredeleniya 1,1-dimetilgidrazina initrosodimetilamina]. Preliminary Patent of the Republic of Kazakhstan [Predvaritelnyi patent Respubliki Kazakhstan]. (In Russian)

Стандарты, ГОСТы:

RMG 61-2003. Indexes of accuracy, precision, validity of the methods of quantitative chemical analysis, methods of evaluation [GSI.Pokazatelitochnosti, pravilnosti, retsizionnosti metodik kolichestvennogo himicheskogo analiza. Metodyiotsenki]. Moscow, Russia, 2003. (In Russian)

На сайте http://www.translit.ru/ можно бесплатно воспользоваться программой транслитерации Русского текста в латиницу, используя различные системы. Программа очень простая, ее легко использовать для готовых ссылок. К примеру, выбрав вариант системы Библиотеки Конгресса США (LC), мы получаем изображение всех буквенных соответствий. Вставляем в специальное поле весь текст библиографии на русском языке и нажимаем кнопку «в транслит».

В конце статьи дается резюме на казахском языке. Оформляется аналогично русскому варианту. Посередине страницы пишется: 1) название статьи; 2) авторы; 3) название организации; с красной строки – **Өзекті сөздер,** после – **Аннотация.**

Последняя страница подписывается всеми авторами, ставится дата.

3. Статьи публикуются только на английском языке.

4. В случае переработки статьи по просьбе редакционной коллегии журнала датой поступления считается дата получения редакцией окончательного варианта. Если статья отклонена, редакция сохраняет за собой право не вести дискуссию по мотивам отклонения.

Официальный сайт журнала «Вестник хирургии Казахстана»: **www.vhk.kz**
E-mail: **kaz.vestnik@mail.ru**