

---

ISSN 2306-5559 (print)  
ISSN 2410-938X (online)

[www.vhk.kz](http://www.vhk.kz)



**№4 (77) 2023**

# **ҚАЗАҚСТАН ХИРУРГИЯСЫНЫҢ ХАБАРШЫСЫ**

---

## **ВЕСТНИК ХИРУРГИИ КАЗАХСТАНА**

---

## **BULLETIN OF SURGERY IN KAZAKHSTAN**

АЛМАТЫ /ALMATY

әр тоқсанда шығып тұратын А.Н. Сызғанов атындағы Ұлттық ғылыми хирургия орталығының ғылыми-тәжірибелік журналы  
ежеквартальный научно-практический журнал Национального научного центра хирургии им. А.Н. Сызганова  
a quarterly scientific-practical journal of the «Syzganov National Scientific Center of Surgery»

#### БАС РЕДАКТОР

**Баймаханов Б.Б.,**

«А.Н. Сызғанов атындағы Ұлттық ғылыми хирургия орталығы» АҚ Басқарма Төрағасы, м.ғ.д., профессор, ҚР ҰҒА академигі

#### БАС РЕДАКТОРДЫҢ ОРЫНБАСАРЫ

**Қаниев Шокан**

#### ЖАУАПТЫ ХАТШЫ, М.Ф.К.

**Исмаилова Г.Н.**

#### РЕДАКЦИЯ АЛҚАСЫ

**Баймаханов Ж.Б.,** PhD  
**Нерсесов А.В.,** м.ғ.д.  
**Сейсембаев М.А.,** м.ғ.д., профессор  
**Султаналиев Т.А.,** м.ғ.д., профессор  
**Байымбетов А.Қ.,** PhD  
**Бөлегенов Т.А.,** м.ғ.д.  
**Миербеков Е.М.,** м.ғ.д., профессор  
**Жураев Ш.Ш.,** м.ғ.д., профессор  
**Медеубеков У.Ш.,** м.ғ.д.  
**Исмаилова Г.Н.,** м.ғ.к.  
**Мутагиров В.В.,** м.ғ.к.  
**Ширтаев Б.Қ.,** м.ғ.к.  
**Муратов М.И.,** м.ғ.к.  
**Баймаханов А.Н.,** м.ғ.к.

#### РЕДАКЦИЯ КЕҢЕСІ

**Susumu Eguchi** (Жапония)  
**Wojciech Polak** (Голландия)  
**Remzi Emiroglu** (Түркия)  
**Bulent Oktay** (Түркия)  
**Tamer Turan** (Түркия)  
**Subhash Gupta** (Индия)  
**Jeong Tea Kim** (Корея)  
**Владимир Вишневский** (Ресей)  
**Иван Стилиди** (Ресей)  
**Олег Руммо** (Беларусь)  
**Hannu Kuokkanen** (Финляндия)  
**Ho-Seong Han** (Корея)  
**Mehmet Habera** (Түркия)  
**Дильгам Магеррамов** (Әзірбайжан)

Журнал ҚР ақпарат, мәдениет және спорт  
Министрлігінде тіркелген.  
Журнал ҚР ҒБМ Ғылым және білім саласындағы  
бақылау комитеті ұсынған Ғылыми еңбектің  
негізгі нәтижелерін жариялау үшін ұсынатын  
ғылыми баспалар тізбесі енгізілген.  
Тіркеу нөмірі 5564-Ж.

Журналдың иесі – «А.Н. Сызғанов атындағы  
Ұлттық ғылыми хирургия орталығы» АҚ.

#### Баспаның мекен-жайы:

050004, Алматы қ., Желтоқсан көш. 62,  
тел. +7(727) 2795306  
<http://vhk.kz>, e-mail: [dr.gismailova@gmail.com](mailto:dr.gismailova@gmail.com)

#### Әрленім және беттеу:

«Старков С.А.» ЖК  
Көкшетау қ., Әуелбеков к., 98

Тапсырыс №634  
Таралымы - 500 дана

Жарияланатын мақалалардың мазмұнына  
авторлар жауапты.

ҚАЗПОЧТА жазылу индексі – 75327

#### ГЛАВНЫЙ РЕДАКТОР

**Баймаханов Б.Б.,**

Председатель правления АО «Национальный научный центр хирургии им. А. Н. Сызганова», д.м.н., профессор, академик НАН РК

#### ЗАМЕСТИТЕЛЬ ГЛАВНОГО РЕДАКТОРА

**Қаниев Шокан**

#### ОТВЕТСТВЕННЫЙ СЕКРЕТАРЬ, К.М.Н.

**Исмаилова Г.Н.**

#### РЕДАКЦИОННАЯ КОЛЛЕГИЯ

**Баймаханов Ж.Б.,** Ph.D;  
**Нерсесов А.В.,** д.м.н.;  
**Сейсембаев М.А.,** д.м.н., профессор;  
**Султаналиев Т.А.,** д.м.н., профессор;  
**Баимбетов А.К.,** Ph.D;  
**Бүлегенов Т.А.,** д.м.н., доцент;  
**Миербеков Е.М.,** д.м.н., профессор;  
**Жураев Ш.Ш.,** д.м.н., профессор;  
**Медеубеков У.Ш.,** д.м.н., профессор;  
**Исмаилова Г.Н.,** к.м.н.;  
**Мутагиров В.В.,** к.м.н.;  
**Ширтаев Б.К.,** к.м.н.;  
**Муратов М.И.,** к.м.н.;  
**Баймаханов А.Н.,** к.м.н.

#### РЕДАКЦИОННЫЙ СОВЕТ

**Susumu Eguchi** (Япония)  
**Wojciech Polak** (Голландия)  
**Remzi Emiroglu** (Түркия)  
**Bulent Oktay** (Түркия)  
**Tamer Turan** (Түркия)  
**Subhash Gupta** (Индия)  
**Jeong Tea Kim** (Корея)  
**Владимир Вишневский** (Россия)  
**Иван Стилиди** (Россия)  
**Олег Руммо** (Беларусь)  
**Hannu Kuokkanen** (Финляндия)  
**Ho-Seong Han** (Корея)  
**Mehmet Habera** (Түркия)  
**Дильгам Магеррамов** (Азербайджан)

Журнал зарегистрирован в Министерстве  
информации, культуры и спорта РК.  
Журнал включен в перечень научных  
изданий, рекомендуемых Комитетом  
по контролю в сфере образования и науки  
МОН РК

Регистрационный номер: 5564-Ж.

Владелец журнала – АО «Национальный научный  
центр хирургии имени А.Н. Сызганова».

#### Адрес редакции:

050004, г. Алматы, ул. Желтоқсан, 62,  
тел. +7 (727) 2795306  
<http://vhk.kz>, e-mail: [dr.gismailova@gmail.com](mailto:dr.gismailova@gmail.com)

#### Дизайн и верстка:

ИП «Старков С.А.»  
г. Кокшетау, ул. Ауельбекова, 98

Заказ 634

Тираж - 500 экз.

Ответственность за содержание  
публикуемых материалов несут авторы.

Подписной индекс КАЗПОЧТЫ – 75327

#### EDITOR IN CHIEF

**Baimakhanov B. B.,**

Chairman of the Board of «Syzganov National Scientific Center of Surgery» JSC, D.Med.Sc., professor, academician of NAS RK

#### DEPUTY CHIEF EDITOR

**Kaniyev Shokan**

#### EXECUTIVE SECRETARY, C.M.S.

**Ismailova G.N.**

#### EDITORIAL BOARD

**Baimakhanov Zh.B.,** PhD;  
**Nersesov A.V.,** D.Med.Sc.;  
**Seisembayev M.A.,** D.Med.Sc., prof.;  
**Sultanaliev T.A.,** D.Med.Sc., prof.;  
**Baimbetov A.K.,** PhD;  
**Bulegenov T.A.** D.Med.Sc.,  
**Miyerbekov Ye.M.,** D.Med.Sc., prof.;  
**Zhurayev Sh.Sh.,** D.Med.Sc., prof.;  
**Medeubekov U.Sh.,** D.Med.Sc., prof.;  
**Ismailova G.N.,** Can.Med.Sc.,  
**Mutagirov V.V.** Can.Med.Sc.  
**Shirtayev B.K.,** Can.Med.Sc.;  
**Muradov M.I.,** Can.Med.Sc.;  
**Baimakhanov A.N.** Can.Med.Sc.

#### EDITORIAL COUNCIL

**Susumu Eguchi** (Japan)  
**Wojciech Polak** (Holland)  
**Remzi Emiroglu** (Turkey)  
**Bulent Oktay** (Turkey)  
**Tamer Turan** (Turkey)  
**Subhash Gupta** (India)  
**Jeong Tea Kim** (Korea)  
**Vladimir Vishnevski** (Russia)  
**Ivan Stilidi** (Russia)  
**Oleg Rummo** (Belarus)  
**Hannu Kuokkanen** (Finland)  
**Ho-Seong Han** (Korea)  
**Mehmet Habera** (Turkey)  
**Dilgam Maherramov** (Azerbaijan)

The journal is registered with the Ministry of  
Information, Culture and Sports of the  
Republic of Kazakhstan.

The journal is included in the list of scientific  
publications recommended by the Committee  
for Control of Education and Science, Ministry  
of Education and Science of Kazakhstan.

Registration number: 5564-Ж

The owner of the journal – «Syzganov  
National Scientific Center of Surgery» JSC

#### Editorial address:

62, Zheltoksan street, Almaty, 050004  
tel. +7 (727) 2795306  
<http://vhk.kz>, e-mail: [dr.gismailova@gmail.com](mailto:dr.gismailova@gmail.com)

#### Design and lead out:

«Starkov S.A.» SP  
98 Auelbekov street, Kokshetau

Order №634

Edition - 500 copies

The authors are responsible for the content of  
published materials.

Subscript index of KAZPOST – 75327

**ХИРУРГИЯ**

Бауыр гемангиомасының диагностикасы мен заманауи емдеу әдістері (әдебиеттік шолу).....4

*Баймаханов Б.Б., Орынғали Г., Суйіндік Ж.С., Қыдырбаева А.К, Барахан Е.Е., Әбілқайыр Д.С., Нарынбай Ш.А., Төлегенова А.М., Ибекенов О.Т., Каниев Ш.А.*

Ішкі ұйқы артериясына операция жасау кезінде миды қорғау әдістерін іздеу тарихын талдау.....17

*Коньсов М.Н., Батрашов В. А., Сухарева Т. В., Мадешов Е. К., Морозов К. М., Кадыров Ж.Е., Коньсова С.А.*

Сегізкөз-мықын байламының зақымданулары бар науқастарда хирургиялық емдеу нәтижелерін салыстырмалы бағалау.....36

*Касымов К.Т, Жунусов Е.Т, Тлемисов А.С, Естемесов Н.Т., Абдумауленов А.У, Раханская Е.*

Тіл бадамшаларының лазерлі абляциясының клиникалық көрінісі.....52

*Кудабаева И.Д., Садыков С.Ж., Жақыбаева А.Н.*

**МЕДИЦИНА**

Гепатитті анықтаудағы ПТР қолдану перспективалары (әдебиетке шолу).....29

*А.Т. Аубакирова, Л.Е. Ризабекова, Г.Б. Абдилова*

Ішектің жедел патологиясының бастапқы диагностикалық әдісі ретінде ішектің трансабдоминалды ультрадыбыстық зерттеуі: әдеби шолу және клиникалық жағдайларды көрсету..45

*Федосина М.В., Кайбуллаева Д.А., Джумабаева А.Е., Мурзалин К.Е., Қанаш Ж.А., Ибекенов О.Т.*

**ӘРІПТЕСТІ ЕСКЕ АЛУ**

Профессор Т.Қ.Көкеевтің 90 жылдығына.....57

**ХИРУРГИЯ**

Диагностика и современные методы лечения гемангиомы печени (обзор литературы).....4

*Баймаханов Б.Б., Орынғали Г., Суйіндік Ж.С., Қыдырбаева А.К, Барахан Е.Е., Әбілқайыр Д.С., Нарынбай Ш.А., Төлегенова А.М., Ибекенов О.Т., Каниев Ш.А.*

Анализ истории поиска методов защиты головного мозга при операциях на внутренней сонной артерии.....17

*Коньсов М.Н., Батрашов В. А., Сухарева Т. В., Мадешов Е. К., Морозов К. М., Кадыров Ж.Е., Коньсова С.А.*

Сравнительная оценка результатов хирургического лечения у пациентов с повреждением крестцово-подвздошного сочленения.....36

*Касымов К.Т, Жунусов Е.Т, Тлемисов А.С, Естемесов Н.Т., Абдумауленов А.У, Раханская Е.*

Клинический случай лазерной абляции язычной миндалины.....52

*Кудабаева И.Д., Садыков С.Ж., Жақыбаева А.Н.*

**МЕДИЦИНА**

Перспективы использования ПЦР в выявлении гепатитов: обзор литературы.....29

*А.Т. Аубакирова, Л.Е. Ризабекова, Г.Б. Абдилова*

Трансабдоминальное ультразвуковое исследование кишечника, как метод первичной диагностики при острой патологии кишечника: литературный обзор и демонстрация клинических случаев..45

*Федосина М.В., Кайбуллаева Д.А., Джумабаева А.Е., Мурзалин К.Е., Қанаш Ж.А., Ибекенов О.Т.*

**В ПАМЯТЬ О КОЛЛЕГЕ**

К 90-летию профессора Кукеева Т.К.....57

**SURGERY**

Diagnosis and modern treatment methods for hepatic hemangioma (literature review).....4

*Baimakhanov B.B., Oryngali G, Suiindik Zh.S, Kydyrbaeva A.K, Barakhan Y. Y., Abilkaiyr D.S., Narynbay Sh.A., Tolegenova A.M., Ibekenov O.T., Kaniyev Sh.A.*

Analysis of the history of the search for methods of protecting the brain during operations on the internal carotid artery...17

*Konyssov M.N., Batrashov V.A., Sukhareva T.V., Madeshov E.K., Morozov K.M., Kadyrov Zh.E., Konyssova S.A.*

Comparative Assessment of Surgical Treatment Outcomes in Patients with Sacroiliac Joint Injury.....36

*Kassymov K., Zhunussov Y., Tlemissov A, Yestemessov N, Abdumaulenov A, Abdumaulenov Y, Rakhanskaya Y.*

Clinical case of laser ablation of lingual amygdala.....52

*Kudabaeva I.D., Sadykov S.J., Zhakybaeva A.N*

**MEDICINE**

Prospects for the use of PCR in the detection of hepatitis (a literature review).....29

*A.T. Aubakirova, L.E. Rizabecova, G.B. Abdilova*

Transabdominal bowel ultrasound as a method of primary diagnosis in acute bowel pathology: literature review and demonstration of clinical cases.....45

*Fedossina M.V., Kaybullaeva D.A, Dzhumabaeva A.E., Murzalin K.E., Kanash Zh.A., Ibekenov O.T.*

**IN MEMORY OF COLLEAGUE**

To the 90th anniversary of Professor T.K. Kukeev.....57

<https://doi.org/10.35805/BSK2023IV001>

Baimakhanov B.B.<sup>1,2</sup>

<https://orcid.org/0000-0003-0049-5886>

Oryngali G.

<https://orcid.org/0009-0000-5238-821X>

Suiindik Zh.S.

<https://orcid.org/0009-0008-8480-2137>

Kydyrbaeva. A.K.

<https://orcid.org/0009-0001-3182-8922>

Barakhan Y. Y.

<https://orcid.org/0009-0000-1960-4208>

Abilkaiyr D.S.

<https://orcid.org/0009-0003-0686-2162>

Narynbay Sh.A.

<https://orcid.org/0009-0008-5849-7407>

Tolegenova A.M.

<https://orcid.org/0000-0003-0523-2671>

Ibekenov O.T.

<https://orcid.org/0000-0001-6605-6435>

Kaniyev Sh.A.

<https://orcid.org/0000-0003-3390-8931>

# DIAGNOSIS AND MODERN TREATMENT METHODS FOR HEPATIC HEMANGIOMA (LITERATURE REVIEW)

Baimakhanov B.B.<sup>1,2</sup> Oryngali G.<sup>1</sup>, Suiindik Zh.S.<sup>1</sup>, Kydyrbaeva. A.K.<sup>1</sup>, Barakhan Y. Y.<sup>1</sup>, Abilkaiyr D.S.<sup>1</sup>, Narynbay Sh.A.<sup>1</sup>, Tolegenova A.M.<sup>1</sup>, Ibekenov O.T.<sup>1,2</sup>, Kaniyev Sh.A.<sup>1,2</sup>

<sup>1</sup>Kazakh National Medical University named after S.D. Asfendiyarov NCJSC, Almaty, Kazakhstan.

<sup>2</sup>Syzganov National Scientific Center of Surgery JSC, Almaty, Kazakhstan

For correspondence:

Oryngali G.-

Kazakh National Medical University

named after S.D. Asfendiyarov

NCJSC, Almaty, Kazakhstan.

Phone +7 708 184 5263

email: goryngaliyeva@mail.ru

Conflict of interest:

The authors declare that they

have no conflicts of interest

## Abstract

**Background.** Hepatic hemangioma is the most common form among benign liver tumors. The vast majority is asymptomatic, usually detected accidentally during screening. A thorough study is required to distinguish it from other local liver pathologies, therefore, in the review paper below we have analyzed important issues during the diagnosis and treatment of liver hemangioma in international experience.

The aim of this study differentiation of modern methods of diagnosis and treatment of liver hemangioma in clinical practice.

**Material and methods.** In the review work, a literature review of randomized, meta-analyses, clinical trials and international clinical recommendations in English and Russian, published only from January 2010 to August 2023 in bibliographic and other electronic medical databases such as PubMed, Scopus, Web of Science, GoogleScholarship, Springer, rare clinical cases were carried out. Criteria for inclusion in the study: 1) full-text research published in the database; 2) research in English or Russian; 3) research carried out or published in the last 2010-2023 years.

**Conclusions.** As the most common benign liver tumor, the incidence of hepatic hemangioma during autopsy is from 0.4 to 20%. Most hepatic hemangiomas are asymptomatic, small-sized forms do not require intervention. Liver hemangioma can be easily diagnosed using ultrasound, or cop phase spiral contrast computer tomography. An indication for surgical resection is a feeling of progressive pain in the abdomen and a size of more than 5 cm. Some patients also have giant hemangiomas with minimal symptomatic. Giant hemangiomas (>10cm) are most often manifested by symptoms and require mandatory surgical intervention. The most commonly used method for the treatment of hemangiomas today is transaortic embolization, surgical resection. But to date, there is no consensus on the best treatment for patients with symptomatic and/or large hemangiomas.

Keywords:

hepatic hemangioma, embolization

of hepatic arteries, benign tumor,

radiofrequency ablation,

liver resection and hepatotomy

## Бауыр гемангиомасының диагностикасы мен заманауи емдеу әдістері (әдебиеттік шолу)

Хат алысатын автор:

Орынғали Г. - «С.Ж. Асфендияров

атындағы Қазақ ұлттық

медицина университеті» КЕАҚ,

Алматы қ., Қазақстан,

Телефон +7 708 184 5263

email: goryngaliyeva@mail.ru

Баймаханов Б.Б.<sup>1,2</sup>, Орынғали Г.<sup>1</sup>, Суйіндік Ж.С.<sup>1</sup>, Кыдырбаева А.К.<sup>1</sup>, Барахан Е.Е.<sup>1</sup>, Әбілқайыр Д.С.<sup>1</sup>, Нарынбай Ш.А.<sup>1</sup>, Төлегенова А.М.<sup>1</sup>, Ибekenov O.T.<sup>1,2</sup>, Каниев Ш.А.<sup>1,2</sup>

<sup>1</sup>«С.Ж. Асфендияров атындағы Қазақ ұлттық медицина университеті» КЕАҚ, Алматы қ., Қазақстан,

<sup>2</sup>«А.Н. Сызғанов атындағы Ұлттық ғылыми хирургия орталығы» АҚ, Алматы қ., Қазақстан.

Мүдделер қақтығысы:

Авторлар мүдделер

қақтығысының жоқтығын

мәлімдейді

Түйін сөздер:

бауыр гемангиомасы, бауыр

артерияларының эмболизациясы,

қатерсіз ісік, радиожілдікті

абляция, бауыр рзекциясы және

гепатотэктомия

## Түйіндемe

**Өзектілігі.** Бауыр гемангиомасы - бауырдың қатерсіз ісіктерінің ішінде ең жиі кездесетін формасы. Басым көпшілігі асимптоматикалық түрде өтеді, әдетте скрининг барысында

кездейсоқ анықталады. Бауырдың басқа да жергілікті патологияларынан ажырату үшін мұқият зерттеуді талап етеді, сондықтан төмендегі шолу жұмысында халықаралық тәжірибедегі бауыр гемангиомасының диагностикасы мен емдеу барысындағы маңызды мәселелерге талдау жасадық.

Клиникалық тәжірибеде бауыр гемангиомасының диагностикасы мен емінің заманауи әдістерін саралау.

**Зерттеу материалдары мен әдістері.** Шолу жұмысында әдебиеттерді іздеу жұмыстары PubMed, Scopus, Web of Science, GoogleScholarship, Springer секілді библиографиялық және өзге де электронды медициналық мәліметтер базасындағы тек 2010 жылдың қаңтары мен 2023 жылдың тамыз аралығында жарияланған ағылшын және орыс тілдеріндегі рандомизацияланған, мета-анализдерге, клиникалық зерттеулер мен халықаралық клиникалық ұсыныстарға, сирек клиникалық жағдайларға әдебиеттік шолу жүргізілді. Зерттеуге қосу критерийі: 1) мәліметтер базасында жарияланған толық мәтінді зерттеулер; 2) ағылшын немесе орыс тілдеріндегі зерттеулер; 3) соңғы 2010-2023 жылдары орындалған немесе жарияланған зерттеулер.

**Қорытынды.** Бауырдың ең көп таралған қатерсіз ісігі болғандықтан, аутопсия кезінде бауыр гемангиомасының пайда болу жиілігі 0,4-тен 20% - ға дейін кездесіп отырады. Бауыр гемангиомаларының көпшілігі асимптомды түрде, көлемі кіші формалары араласуды қажет етпейді. Бауыр гемангиомасын ультрадыбыснемесе коп фазалық спиральды контрастты компьютер томограф көмегімен жеңіл диагноз қоюға болады. Хирургиялық резекцияға көрсеткіш ретінде іштей прогрессивті ауыру сезімі және көлемі 5 см ден жоғары болуы болып табылады. Кей науқастарда минимальды симптоматикамен гиганттық гемангиомалар да кездеседі. Гиганттық гемангиомалар (>10см) көбінесе симптомдармен көрінеді және міндетті хирургиялық араласуды қажет етеді. Гемангиомаларды емдеуге қазіргі таңда жиі қолданылатын әдіс трансартериялық эмболизация, хирургиялық резекция. Бірақ бүгінгі күнге дейін симптоматикалық және/немесе үлкен гемангиомасы бар науқастарды емдеудің ең жақсы әдісі туралы консенсус жоқ.

## Диагностика и современные методы лечения гемангиомы печени (обзор литературы)

Баймаханов Б.Б.<sup>1,2</sup>, Орынғали Г.<sup>1</sup>, Сүйіндік Ж.С.<sup>1</sup>, Кыдырбаева А.К.<sup>1</sup>,  
Барахан Е.Е.<sup>1</sup>, Әбілқайыр Д.С.<sup>1</sup>, Нарынбай Ш.А.<sup>1</sup> Төлегенова А.М.<sup>1</sup>  
Ибекенов О.Т.<sup>1,2</sup> MD, PhD, Каниев Ш.А.<sup>1,2</sup> MD, PhD

<sup>1</sup>НАО «Казахский Национальный медицинский университет имени С.Д. Асфендиярова», г. Алматы, Казахстан,

<sup>2</sup>АО «Национальный Научный центр хирургии им.А.Н.Сызганова», г. Алматы, Казахстан.

### Аннотация

**Актуальность.** Гемангиома печени является наиболее распространенной формой среди доброкачественных опухолей печени. Подавляющее большинство протекает бессимптомно, обычно обнаруживается случайно во время скрининга. Требуется тщательное исследование, чтобы отличить его от других местных патологий печени, поэтому в приведенной ниже обзорной работе мы проанализировали важные вопросы в ходе диагностики и лечения гемангиомы печени в международном опыте.

Целью исследования является дифференцировать современные методы диагностики и лечения гемангиомы печени в клинической практике.

**Материалы и методы.** В обзорной работе проведен литературный обзор рандомизированных, мета-анализов, клинических исследований и международных клинических рекомендаций, редких клинических случаев на английском и русском языках, опубликованных в библиографических и иных электронных медицинских базах данных, таких как PubMed, Scopus, Web of Science, GoogleScholarship, Springer только в период с января 2010 года по август 2023 года. Критерий включения в исследование: 1) полнотекстовые исследования, опубликованные в базе данных; 2) исследования на английском или русском языках; 3) исследования, выполненные или опубликованные за последние 2010-2023 годы.

Автор для корреспонденции:  
Орынғали Г. - НАО «Казахский  
Национальный медицинский  
университет имени  
С.Д. Асфендиярова»,  
г. Алматы, Казахстан,  
Телефон +7 708 184 5263  
email: goryngaliyeva@mail.ru

**Конфликт интересов:**  
Авторы заявляют об отсутствии  
конфликта интересов

**Ключевые слова:**  
гемангиома печени,  
эмболизация печеночных  
артерий, доброкачественная  
опухоль, радиочастотная  
абляция, резекция печени и  
гепатотэктомия

**Заклучение.** Поскольку это наиболее распространенная доброкачественная опухоль печени, частота появления гемангиомы печени при вскрытии колеблется от 0,4 до 20%. Большинство гемангиом печени протекают бессимптомно, а малые формы не требуют вмешательства. Гемангиомы печени можно легко диагностировать с помощью ультразвука, или спирально-контрастной компьютерной томографии. Показанием к хирургической резекции является прогрессирующая боль в животе и размер более 5 см. У некоторых пациентов также встречаются гигантские гемангиомы с минимальной симптоматикой. Гигантские гемангиомы (>10 см) часто проявляются симптомами и требуют обязательного хирургического вмешательства. В настоящее время наиболее часто используемым методом лечения гемангиом является трансартериальная эмболизация, хирургическая резекция. Но на сегодняшний день нет единого мнения о том, как лучше всего лечить пациентов с симптоматическими и/или большими гемангиомами.

### Introduction

Hepatic hemangioma (HH) is a benign mesodermal tumor consisting of flat endothelial cells of the vessels.<sup>1,2,3</sup> According to the results of various studies, the incidence of liver hemangioma ranges from 0.4-7.3% to 4-20%,<sup>2,3,4,5</sup> in adults aged 30-50 years<sup>3</sup> and in children it is common mainly in the first 6 months of life and accounts for 12% of all lesions.<sup>6,7</sup>

We present a review of the latest literature on HH and new developments in diagnostic imaging techniques and surgical treatments for HH. This topic is relevant because diagnostic methods are improving, which makes it possible to visualize small hemangiomas that were not previously diagnosed. In addition, liver surgery techniques have improved and allow treatments previously considered surgically inaccessible.

Small and medium-sized types of HH in size range from 1.0 mm to 20.0 cm,<sup>1,8</sup> continue to meet even in giant forms (40.0-50.0 cm and above).<sup>2,7</sup> Location in the liver in most cases only in the singular, located in the right part of the liver, most often in the IV segment.<sup>8,9</sup>

HH is classified according to microscopic data into three main types: cavernous, capillary and anastomose forms, of which the cavernous form is the most common type.<sup>10,11,12</sup>

And according to the latest edition of Weerakkody Y., et al. on February 28, 2023, HH classified several types:

- I. Type hemangioma of the liver;
- II. atypical liver hemangioma:
  - a) giant hemangioma of the liver
  - b) Unscheduled filled HH: up to 16% of all hepatic hemangiomas
  - c) calcified liver hemangioma
  - d) Hyalinized / sclerosed liver hemangioma
  - e) other special types:
    - with capsular retraction
    - surrounded by regionary nodule hyperplasia with fatty infiltration
    - hepatic sclerosed hemangioma is a rare form disease.
    - fused with the extremities
    - cystic liver hemangioma (occur rare)
    - is fluid-based on the amount of fluid in the liver hemangioma.<sup>12</sup>

According to the study of Christison-Lagay ER., et al and others, the authors classified 3 main categories of hepatic hemangioma in children: focal, multifocal and diffuse. However, there is currently no clear classification criterion for hepatic hemangioma.<sup>13,14</sup>

Another type of hemangioma is epithelioid hemangioendothelioma is malignant vascular tumor. Pathogenesis mechanisms on the development have not been clarified, however, there is evidence that an increase in vascular endothelial growth factor (VEGF) may be an important proangiogenic factor in the development of hemangioma. This is confirmed by a decrease in hemangioma size after anti-VEGF treatment.<sup>14,15</sup> Also, the increase in hemangiomas can be influenced by hormone replacement therapy with estrogen, especially after taking oral contraceptives or after pregnancy.<sup>16,17,18</sup>

Clinical manifestations of hemangioma usually pass asymptotically, but symptoms may appear when the size is greater than > 5 cm.<sup>19</sup> Pain under the right ribs, mainly associated with stretching of Glisson's capsule, accompanied by symptoms of loss of appetite, nausea, vomiting, jaundice, as well as due to compression of other organs with manifestations of bloating and shortness of breath.<sup>18,19</sup>

Giant HH can be induces Kasabach-Merrit syndrome, manifested by consumption coagulopathy as a thrombocytopenia, anemia, hypofibrinogenem, reduced prothrombin time. Treatment for Giant hemangioma with Kasabach-Merrit syndrome definitely is removal of the vascular tumor by transarterial embolization (TAE), transarterial lipiodolization (TAL), radiofrequency ablation (RFA), surgical resection (SR) and liver transplantation (LT) but the alternative use of systemic glucocorticoids in combination with beta-blockers has shown a positive effect.<sup>20,21,22,23</sup>

### Diagnosis of hemangioma

Physical examination does not occur with significant changes in other research studies, including biochemical blood tests.<sup>1-4,13,18</sup> Hypofibrinogenemia is caused by intra-tumor fibrinolysis, and thrombocytopenia is associated

with large lesions that are a consequence of sequestration and destruction of the spleen.

Shigeo M. et al. (2022) in a study of 283 patients (Table 1), normal serum values were

recorded in 255(90.7%) patients. Only in 26 patients there was a slight increase in the level of alanine aminotransaminase, alkaline phosphatase.<sup>24</sup>

Parameters	Value
Age (years)	54 ± 15
Male/female (n)	98/183
<b>Biochemistry</b>	
Total bilirubin (mg/dL)	0.6 ± 0.2
Albumin (g/dL)	4.2 ± 0.2
ALT (U/L)	20 ± 13
GGT (U/L)	39 ± 42
ALP (U/L)	236 ± 76
BUN (mg/dL)	14.1 ± 3.7
Cr (mg/dL)	0.70 ± 0.17
LDL-chol (mg/dL)	100 ± 25
HDL-chol (mg/dL)	68 ± 18
Glucose (mg/dL)	102 ± 28
HbA1c (%)	5.5 ± 0.6
<b>Hematology</b>	
Hemoglobin (g/dL)	13.5 ± 1.3
WBC (/μL)	5700 ± 1600
Platelet (×10 <sup>4</sup> /μL)	22.4 ± 5.2
<b>Coagulation</b>	
PT (%)	94.2 ± 12.7
Fibrinogen (mg/dL)	282 ± 74
TAT (ng/mL)	1.39 ± 0.97
D-dimer (μg/mL)	0.70 ± 0.69
FDP (μg/mL)	1.68 ± 1.04
<b>Serology</b>	
M2BPGi (COI)	0.55 ± 0.32
AFP (ng/mL)	3.6 ± 1.5
PIVKA-II (mAU/mL)	20.1 ± 5.8

Table 1.  
Laboratory values of 281 patients presented by Shigeo M. et al.<sup>24</sup>

Tumor markers: alpha-fetoprotein (AFP), CA 19-9 (carcinogenic antigen 19-9) and carcinogenic embryonic antigen (CEA) show a benign nature of the lesion within normal limits.<sup>9</sup>

Wang HY. et al. in a 47-year-old man with cavernous hemangioma, a clinically determined serum AFP level of 371.51 μg/l (normal 0-20

μg/l), in the second week after surgical treatment the level AFP decreased to 24.45 μg/L.<sup>25</sup>

Jang S. et al. published the results of a 10-year study on AFP levels in 195 patients with HH, that showed higher AFP levels (p<0.001) and monitoring for them during 13 months not determined cancer or other liver disease.<sup>26</sup> And

rare cases have been reported that sclerosing hepatic hemangioma mimics malignant tumors of the gallbladder and liver.<sup>27,28</sup>

In the diagnosis of HH, ultrasound, magnetic

resonance imaging, contrast CT are used to distinguish it from other liver tumors, metastases, cysts and other angiogenic formations.

Table 1.  
Analysis of diagnostic methods

Diagnostic methods	Description	Advantages	Disadvantages
Ultrasound <sup>9,29,30</sup>	Appears as a hyperechogenic homogeneous node	Convenient, popular as the first diagnostic method due to its availability Minimum radiation risk	Ultrasound can cause similar acoustic patterns from some liver tumors (hepatocellular carcinoma and liver metastases) and other imaging methods must be used to confirm the diagnosis
CEUS <sup>29,30</sup>	Shows three different vascular phases using the hepatic artery and portal vein after contrast agent	Proven to be a reliable method for describing focal liver damage Monitors multiple types of damage at the same time. An accurate diagnosis is made, which is currently reaching about 95% of cases. Does not require additional verification.	Allergies, caused by the effects of the use of contrast agents, can lead to liver and kidney failure.
CT <sup>1,31,32</sup>	CT shows an increase in contrast in nodular or spherical shape at the edges of the tumor at the initial stage and the contrast increases evenly throughout the tumor.	The importance indicates the type of upper, hypodense, well-defined lesion. In addition, if there is intra-tumor bleeding, the hemangioma looks like a mass with a very dense inner part. Allows you to determine the localization of the lesion area.	Hemangiomas that show diffuse homogeneous enlargement in the arterial phase may resemble hypervascular cancers such as tumor. It is difficult to detect small lesions with a size of <5 mm. Exposure to radiation and the use of iodine contrast agents can cause nephropathy
MRI <sup>31-33</sup>	Can be recognized as informative, shows smooth, uniform lesions, hypointensive imaging.	Differential diagnosis can be made with cancer. Gadolinia contrast agent can be continued to be used in patients who are allergic to iodine, with renal failure.	Not available Magnetic wave effect
Tc-99m scintigraphy <sup>9</sup>	When the patient's erythrocyte cells are saturated with Tc-99m radiopharm, they go to places of increased blood supply. 1cm indicates minor lesions.	Scintigraphy is always performed in parallel with CT or ultrasound to determine the location, shape and number of lesions.	The limited availability, high cost and duration of the procedure, the nature of its radiation, and the variety of potentially competing imaging technologies have led it to be used less as a diagnostic method of HH.



Ultrasound examination (hereinafter referred to as ultrasound), convenient, popular as the first diagnostic method due to its availability. HH appears on ultrasound as a hyperechogenic homogeneous node with well-defined edges and back acoustically amplified.<sup>1,27</sup> Hepatic hemangioma can cause similar acoustic patterns from some liver tumors (hepatocellular carcinoma and liver metastases) on ultrasound, and other imaging methods must be used to confirm the diagnosis.<sup>1,30</sup>

Contrast-enhanced ultrasound (CEUS) has been shown to be a reliable method for describing focal liver damage,<sup>29,30,34</sup> which is a sensitive and specific method for diagnosing hemangiomas.<sup>34</sup> CEUS significantly improved the exact diagnosis of hepatic hemangiomas, which is currently reaching about 95% of cases.<sup>34</sup> Even this can ensure the diagnosis of hemangioma in most cases without the need for additional examination.<sup>35</sup>

The CEUS liver examination shows three different vascular phases using the hepatic artery and portal vein after the injected contrast agent:<sup>33</sup>

a) arterial phase: provides information on the extent and nature of the blood supply to the arterial vessels in the case of local liver damage;

B) portal vein phase: provides information through the portal system, leading to a diffuse and maximum enlargement of the normal parenchyma of the liver;

c) late phase: lasts until the contrast agent is removed from the circulation and provides

information about the absorption of the contrast agent by phagocytic cells (e.g. Kupfer cells).<sup>32,33</sup>

The importance of CT in the diagnosis of hepatic hemangioma is manifested in the form of upper, hypodense, well-defined lesions.<sup>1,31</sup> CT shows an increase in contrast in nodular or spherical shape at the edges of the tumor at the initial stage and the contrast increases evenly throughout the tumor.<sup>31</sup> In addition, if there is intra-tumor bleeding, the hemangioma looks like a mass with a very dense inner part.<sup>1,31</sup>

Hemangiomas that show diffuse homogeneous enlargement during the arterial phase may resemble hypervascular cancers such as hepatocellular carcinomas or hypervascular metastases.<sup>31</sup>

The magnetic resonance imaging method can also be recognized as informative in the diagnosis of hepatic hemangioma, showing smooth, uniform lesions, hypointensive imaging.<sup>31,36</sup>

Tc-99m scintigraphy is a non-invasive method that provides the most accurate diagnosis of liver hemangioma.<sup>9</sup> Scintigraphy is always performed in parallel with CT or ultrasound to determine the location, shape and number of lesions. The limited availability, high cost and duration of the procedure, the nature of its radiation, and the variety of potentially competing imaging technologies have led to it being used less as a diagnostic method of HH.<sup>9</sup>

Due to the high risk of bleeding and low diagnostic effectiveness, puncture biopsy is not recommended in the diagnosis of HH.<sup>36,37</sup>

Diagnostic methods	Sensitivity	Specifications
Ultra sound	96,9%	60,3%
CEUS	98%	100%
CT	98,3%	55%
MRI	100%	85,7%
Tc-99 m	75%	100%

Table 3.  
Accuracy of diagnostic  
methods <sup>1,9,33</sup>

Selective angiography of hepatic arteries has the highest specificity of detection of HH, this method is used in combination with the embolization method in the treatment of hemangioma.<sup>9</sup>

In histological examination, under microscopy stained with hematoxylin-eosin, HH is expressed as dilated vascular channels lined with a single layer of endothelial cells. Complications of HH include necrosis, thrombin formation, multiple sclerosis or calcification.<sup>9</sup>

#### Treatment of hemangioma

There is no known pharmacological

therapy capable of reducing the size in the treatment of HH.<sup>1-4,33</sup> Antiangiogenic therapy with bevacizumab (a monoclonal antibody capable of inhibiting the activity of endothelial growth factor) has been considered, but this has not been proven.<sup>9</sup>

The main treatment is surgical methods as SR of the liver and tumor enucleation,<sup>38-47</sup> LT,<sup>40,48,49</sup> liver hepatectomy (LH),<sup>33,50-52</sup> RFA and TAE.<sup>53,54</sup>

Procedures common worldwide as the "gold standard" method of treating HH are liver resection, hepatectomy, and enucleation (laparotomy, laparoscopy, or robotic

method).<sup>38-42,51,55-57</sup>

The main indications for surgery are a rapid increase in the size of the hemangioma (>5 cm), the presence of pain despite analgesics, complications of hemangioma: risk of thrombosis, rupture, location, compression of neighboring organs, etc.<sup>33,56</sup> At the same time, hemangioma  $d \geq 10$  cm, abdominal symptoms, signs of coagulopathy will be an absolute indication for surgery.<sup>20</sup>

Symptomatic hepatic hemangiomas are usually treated surgically (liver resection or

enucleation, open, laparoscopic, or robotic). However, surgery for giant hemangiomas of the liver can cause intraoperative bleeding with a high mortality rate. In addition, it is known that many patients at risk of sudden rupture of hepatic hemangioma cannot tolerate surgery due to hypovolemia. And the TAE method is a method that allows tumor shrinkage and remission of symptoms to be achieved with minor complications, which is especially indicated for patients with high surgical risk.<sup>55</sup>

Table 1.  
Analysis of diagnostic methods

Type of surgical treatment	Authors	Number of people who participated in the study	Age	Description of the diagnosis of HH	Results
TAE	<i>Kalogiru M. et al.</i> <sup>55</sup> (2018)	n=2	1-43 years old (y/o) 2-79 y/o	The presence of exophytic hemangioma in segments n1-VI and VII $d > 7.5$ cm, signs of fracture and bleeding, as well as accumulation of fluid under the liver were found (Figure 4).  n2-the size of 7.7 to 15 cm diagnosed with giant hemangioma (Figure 5)	After the n1-TAE procedure, he developed mild post-TAE syndrome, which resolves on its own. A follow-up CT scan one month after TAE showed a decrease in the size of the hemangioma from 7.5 cm to 6.9 cm from TAE. Within 10 months after TAE, the patient had no symptoms. Complications associated with n2 - TAE were not observed in the patient. After the procedure, the laboratory values returned to normal and the symptoms gradually disappeared. After 9 months, all the observed symptoms disappeared, and CT showed a slight decrease in the size of the tumor.
	<i>Furumaya A., et al.</i> <sup>54</sup> (2019).	n=1284	18±76 y/o	Tumor size from 9.79 ± 0.79 CM	4.00±1.36 cm showed a significant decrease ( $P < 0.001$ ) Decreased tumor size in 1100/1223 (89.9%) of patients 1080/1096 (98.5%) of patients resulted in improvement or loss of symptoms Grade 3 complications occurred in 37(2.9%) out of 1,284 patients Surgical treatment required 35 (2.7%) of 1,284 patients
	<i>Torkian P, et al.</i> <sup>58</sup> (2020) Lipiodol-based treatment compared to PVS.	n=1450	46.3±3.6 y/o	Diameter average $d=9.69 \pm 10.4 \pm 2.95$	Overall reduction in diameter (CM) 4.37-4.70

RFA	Sun JH. et al. <sup>59</sup> (2012)	n=36	49.5±6.5 y/o	20 patients with 24 hemangiomas d≥5 cm 16 patients with 17 hemangiomas d<10 cm	41 hemangioma has subcapsular damage. 22 patients showed 62 signs of complications. According to the Dindo-Clavien Classification, 2 patients had: fistula in the lower esophagus, acute respiratory distress syndrome (degree 2,4). Successfully passed the rest of the patients, the average decreased to d=6±3. 15±6 months no relapse was observed. Alternative method for the treatment of hemangiomas only d≤5 cm.  d≥5 cm with 24 hemangiomas in 20 patients 16 patients with 17 hemangiomas d<10 cm successful completion In 2 patients: esophageal fistula, acute respiratory distress syndrome developed.
Enucleation	Li H., et al. <sup>45</sup> (2023)	n=58	Different age features	HH: 1.NLG - normal location group 2.SLG - special location group (I, IVa, VII и VIII- segments)	Complications encountered sizeNLG: Bile leakage: 11% Vascular thrombosis: 6.5% Ascites: 9.7% SLG: Bile leakage: 12.9% Vascular thrombosis: 7.4% Ascites: 11.1% Duration of hospital stay NLG 7.3±2.6 day SLG 11.5±3.4 day As a result, the enucleation of hepatic hemangioma, located in a special segment, leads to serious complications.

Kalogiru M. et al. described in their studies 2 cases of bleeding giant hepatic hemangiomas that were successfully treated with TAE. In the first case, a 43-year-old man with a giant liver hemangioma presented with acute pain in the right costal arch of the abdomen; in the second case, a 79-year-old woman with a giant liver hemangioma with complaints for severe fatigue and anorexia. In both cases, the giant hemangioma continued to grow to 7.5 and 15 cm, respectively. In the first case, CT showed signs of rupture and bleeding, as well as fluid accumulation under the liver, and the patient underwent superselective embolization with 6 ml of lipiodol with the embolic agent used in the form of microspheres ranging in size from 100 to 500 microns. A control CT scan a month after TAE showed a decrease in the size of the hemangioma to 6.9 cm. In the second case, the patient was prescribed selective TAE in a

volume of 8 ml of Lipiodol, with microspheres as an embolic agent from 100 to 700 microns. CT scan showed a slight decrease in tumor size after TAE.<sup>55</sup>

The successful use of TAE before surgery for a ruptured hemangioma was first reported in 1991 by Yamamoto T., et al. According to Srinivas D., et al TAE is a successful hemostatic method in 80% of cases. Lipiodol is a microvascular embolizing agent that has anticancer properties and can block the blood flow of the tumor.<sup>5,56,60</sup>

Furumaya A., et al. (2019) conducted a meta-analysis of 18 cohort studies, to evaluate the effectiveness and safety of treatments for TAE/TAL liver hemangiomas in 1284 patients. According to their data, TAE/TAL reduced tumor size from 9.79 ± 0.79 cm to 4.00 ± 1.36 cm (P < 0.001) in 89.9% patients, improved or resolved hemangioma symptoms in 98.5% patients. Complications occurred in 37(2.9%)

patients. Than TAE/TAL is a productive and safe treatment for reducing the size of cancerous liver hemangioma and can be considered as an alternative to resection.<sup>54</sup>

In addition, the study by *Torkian P, et al* (2020) included 21 studies involving 1450 patients with a total hemangioma. The average follow-up time after embolization was 12 months. Lipiodol-based treatment showed a significant effect of a decrease in the size of the hemangioma after TAE ( $p < 0.001$ ). Overall reduction in diameter from  $(-4.37\text{cm})$  to  $(-0.93\text{cm})$  for general TAE treatment, lipiodol-based and lipiodol-free treatment accordingly. The main complications were post-embolization syndrome and increased transient activity of liver enzymes. No any reports of fatal complications and clinical improvement was observed in 63.3-100% studies.<sup>58</sup>

In conclusion, the use of TAE for the treatment of giant hemangioma of the liver has the advantages of minimal trauma, fewer complications and good efficacy, especially in patients with high surgical risk. TAE therapy for giant hemangioma of the liver is safe and effective and is an alternative to surgery.<sup>59</sup>

In recent years, RFA has been increasingly used for the treatment of cavernous hemangiomas of the liver due to its unique advantages such as minimal invasiveness, efficacy, high safety, rapid recovery and wide application<sup>38,53</sup> in the early stages, this method has only been used for hepatic hemangiomas up to  $< 10\text{ cm}$  in size, however, the question of whether RFA should be used to treat hemangiomas is still debated due to the need for longer ablation times.<sup>38</sup>

Previously, hepatologists-surgeons believed that the only radical method of treating patients with focal liver diseases, which can significantly extend and improve the quality of life, is liver resection.<sup>39</sup> And in recent years, several studies have evaluated the effectiveness of enucleation compared to hepatectomy, and most of them have concluded that enucleation is associated with a lower incidence, shorter surgery time, lower blood loss, and fewer complications.<sup>40,42</sup>

Enucleation is technically easier in a peripherally located HG, and when performed in a centrally located HG, it leads to an increase in operation time and increased blood loss.<sup>40,42,44</sup>

*Li H, et al.* published the results of 58 patients who underwent laparoscopic enucleation of hepatic hemangioma in 2023.<sup>43,45</sup> Depending on the location of the hemangioma, the authors considered patients in two groups: special location group (SLG) and normal location Group (NLG). In

the study, serum transaminases and bilirubin levels increased in the postoperative period, reaching their maximum level on the third or fourth day after surgery, and then gradually decreased to normal levels. There are no reliable differences in biochemical parameters between the two groups ( $p > 0.05$ ). However, the duration of postoperative hospital stay in the SLG of patients was significantly longer than in the NLG, which was  $3.8 \pm 1.4$  and  $2.9 \pm 0.8$  days ( $p = 0.03$ ) and  $11.5 \pm 3.4$  and  $7.3 \pm 2.6$  days ( $p < 0.01$ ), respectively. Postoperative complications, including pleural effusion ( $p = 0.362$ ), ascites ( $p = 0.800$ ), bile leakage ( $p = 0.845$ ) and vascular thrombosis ( $p = 0.735$ ), have not been reported.<sup>45</sup> The authors concluded that laparoscopic enucleation of hemangiomas in certain segments of the liver is complex and carries a significant risk of massive bleeding during surgery.

*Ramanujam A., et al.* (2015) published a clinical case of successful enucleation of giant hemangioma, so that they confirmed the advantages of the procedure over resection and other new treatments.<sup>46</sup>

Well, *Muthukumarassamy R., et al.* in their study published in 2021 noted that there is no significant difference between liver resection and enucleation. The study performed a total of 64 patients, including 41 liver resection, 22 tumor enucleation, and 1 LT. The results after the operation were similar in both groups.<sup>47</sup>

*Liu Y., et al.* in 2017, published in the databases PubMed, Embase, Web of Science and the Cochrane Library, published their research comparing the results of enucleation and anatomical resection of HG. According to the results of nine studies involving a total of 1185 patients: blood loss ( $p < 0.00001$ ), duration of surgery ( $p = 0.03$ ) and duration of hospital stay ( $p = 0.03$ ) were significantly lower in the enucleation group. Thus, the authors hypothesized that enucleation can preserve more liver parenchyma and reduce postoperative complications.<sup>40</sup>

Thus, the advantages of enucleation of hepatic hemangioma differ in lower intraoperative blood loss (enucleation: 400 ml compared to resection: 1330 ml), lower risk of bile leakage (enucleation: 0% compared to resection: 8-17%), maximum preservation of functional liver parenchyma and fewer overall complications.<sup>40,42,45</sup>

LT is not considered a first-line treatment for hepatic hemangioma. A study published in 2015 showed that in the United States, 147(0.17%) patients with benign liver tumors underwent LT, including 25 patients with HH. Indications for LT in patients with HH include the development of severe symptoms, rapid tumor growth, failure of other surgical

methods, and the occurrence of life-threatening complications such as Kasabach-Merritt syndrome.<sup>40,48,49</sup>

### Discussion

Hepatic hemangioma is the most common benign liver tumor. Typical hemangiomas, also known as capillary hemangiomas, range in size from a few mm to 3 cm, do not increase over time and are therefore unlikely to cause symptoms in the future. Giant hemangiomas of the liver can develop symptoms and complications that require immediate surgery or other type of therapy. Since the treatment strategy for hemangioma in the liver depends on the size of the first tumor, it is very important how many cm from the giant hemangioma in the liver area is considered gigantic. There are different criteria for this definition. Most authors use the diameter criterion > 4 cm, while others use a diameter of > 5 cm and some use a diameter of > 10 cm. We believe that the definition of a giant hemangioma should be based on a diameter of  $\geq 10$  cm, because a 10 cm hemangioma can cause more severe symptoms than a 4 cm tumor. Thus, in this study, we focused on patients with hepatic hemangioma larger than 10 cm.<sup>61</sup>

Hemangioma in the liver can be detected in most patients through non-invasive tests, especially MRI. CT angiography is a valuable preoperative study in patients with large tumors.<sup>20</sup> In modern diagnostics of BG, the above CEUS examination is proven to be a reliable method for describing focal liver damage, so we agree with the authors' study.<sup>29,30,34</sup>

*Chengming Q., et al.*, at the initial stage of RFA, only hepatic hemangiomas up to < 10 cm in size were treated with this method, but the question of whether RFA should be used for the treatment of hemangiomas is still being discussed due to the need for a long ablation time.<sup>38</sup> One of the most effective methods of treatment is the use of subcutaneous microwave ablation under ultrasound control. This method is currently better than RFA because the time of exposure to thermal energy on tumor tissue is shorter. The main disadvantages are the development of unambiguous hemolysis due to the abundant blood supply to the tumor, the possibility of hemoglobinuria, hemolytic jaundice, anemia and kidney damage, as well as burns of the gastrointestinal tract (stomach, colon and small intestine), when the edge of thermal exposure is located at a distance of less than 1 cm from neighboring organs.

There are also two main types of surgical interventions-resection of a part of the liver affected by hemangioma and enucleation

of hemangioma. The above *Ramanujam A., et al.* according to a study by the authors (2015), successful enucleation of giant hemangioma has been proven. In agreement with the authors, it should be noted the advantages of enucleation over other surgical operations (liver resection).<sup>46</sup>

However, postoperative mortality can be between 0-4%, and the risk of complications can be between 2-7%, depending on the postoperative period. Symptomatic hepatic hemangiomas are usually treated surgically (liver resection or enucleation, open, laparoscopic, or robotic). However, surgery for giant hemangiomas of the liver can cause intraoperative bleeding with a high mortality rate. Therefore, during enucleation and resection in the liver, we think that there is a high risk of developing intraoperative bleeding, which is mainly due not to the large size of the tumor, but to its proximity to large vascular trunks. We decided that this would cause the need to use selective intra-arterial embolization before surgery in patients at high risk of bleeding.

According *Kalogirou M. et al. (2018)*, *Furumaya A., et al. (2019)* and *Torkian P., et al. (2020)* TAE is considered an effective minimally invasive method of treating complicated liver hemangiomas for patients with a high surgical risk due to the low incidence of complications. In conclusion, TAE can be used as the main treatment for giant hemangiomas, which in individual cases is an effective alternative to surgery.<sup>54,55,58</sup>

In addition, it is known that many patients with spontaneous rupture of hepatic hemangioma cannot tolerate surgery due to hypovolemia. We support the TAE method of the above authors: this is because TAE allows tumor shrinkage and symptom remission to be achieved with minor complications, which is especially indicated for patients at high risk of surgery.

In recent years, TAE of the liver has been increasingly used to achieve the hemodynamic stability of the patient before surgical treatment and as a method for the preoperative treatment of bleeding giant hemangiomas. Another feature is that when using the TAE method for giant bleeding hemangiomas, subsequent surgery may not be required.

### Conclusion

CEUS examination is a reliable method for describing focal liver damage. Treatment of hemangiomas includes transarteric embolization, surgical resection. But to date, there is no consensus on the best treatment for patients with symptomatic and/or large hemangiomas.

## References

1. Leon M, Chavez L, Surani S. Hepatic hemangioma: What internists need to know. *World J Gastroenterol*. Jan 07 2020;26(1):11-20. doi:10.3748/wjg.v26.i1.11
2. Yang Z, Tan H, Liu X, Sun Y. Extremely Giant Liver Hemangioma (50 cm) with Kasabach-Merritt Syndrome. *J Gastrointest Surg*. Oct 2017;21(10):1748-1749. doi:10.1007/s11605-017-3429-7
3. Sechel G, Fleancu A, Rogozea L. Aspecte atipice imagistice ale hemangioamelor hepatice. *JMB*. 49-55.
4. Hasan HY, Hinshaw JL, Borman EJ, Gegios A, Levenson G, Winslow ER. Assessing normal growth of hepatic hemangiomas during long-term follow-up. *JAMA Surg*. Dec 2014;149(12):1266-71. doi:10.1001/jamasurg.2014.477
5. Toro A, Mahfouz AE, Ardiri A, et al. What is changing in indications and treatment of hepatic hemangiomas. A review. *Ann Hepatol*. 2014;13(4):327-39.
6. Berte N, Filfilan A, Mainard L, Mansuy L, Lemelle JL. Co-existing infantile hepatic hemangioma and mesenchymal hamartoma in a neonate. *J Surg Case Rep*. Jan 2018;2018(1):rjx260. doi:10.1093/jscr/rjx260
7. Koszka AJ, Ferreira FG, de Aquino CG, et al. Resection of a rapid-growing 40-cm giant liver hemangioma. *World J Hepatol*. Jul 27 2010;2(7):292-4. doi:10.4254/wjh.v2.i7.292
8. Chen L, Zhang L, Tian M, Hu Q, Zhao L, Xiong J. Safety and effective of laparoscopic microwave ablation for giant hepatic hemangioma: A retrospective cohort study. *Ann Med Surg (Lond)*. Mar 2019;39:29-35. doi:10.1016/j.amsu.2019.02.001
9. Bajenaru N, Balaban V, Săvulescu F, Campeanu I, Patrascu T. Hepatic hemangioma -review-. *J Med Life*. 2015;8 Spec Issue(Spec Issue):4-11.
10. Giuseppe M, Vincenzo C, Christine C, Kelvin C, Bartolotta TV, Miraglia R. Imaging of hepatic hemangioma: from A to Z. *Abdominal Radiology*. 2020;45(3):672-691.
11. Oldhafer KJ, Habbel V, Horling K, Makridis G, Wagner KC. Benign Liver Tumors. *Visc Med*. Aug 2020;36(4):292-303. doi:10.1159/000509145
12. Shimada Y, Takahashi Y, Iguchi H, et al. A hepatic sclerosed hemangioma with significant morphological change over a period of 10 years: a case report. *J Med Case Rep*. May 28 2013;7:139. doi:10.1186/1752-1947-7-139
13. Dietrich CF, Mertens JC, Braden B, Schuessler G, Ott M, Ignee A. Contrast-enhanced ultrasound of histologically proven liver hemangiomas. *Hepatology*. May 2007;45(5):1139-45. doi:10.1002/hep.21615
14. Christison-Lagay ER, Burrows PE, Alomari A, et al. Hepatic hemangiomas: subtype classification and development of a clinical practice algorithm and registry. *J Pediatr Surg*. Jan 2007;42(1):62-7; discussion 67-8. doi:10.1016/j.jpedsurg.2006.09.041
15. Emamaullee JA, Edgar R, Toso C, et al. Vascular endothelial growth factor expression in hepatic epithelioid hemangioendothelioma: Implications for treatment and surgical management. *Liver Transpl*. Feb 2010;16(2):191-7. doi:10.1002/lt.21964
16. Zheng N, Ding X, Jahan R. Low concentration of rapamycin inhibits hemangioma endothelial cell proliferation, migration, and vascular tumor formation in mice. *Curr Ther Res Clin Exp*. Dec 2014;76:99-103. doi:10.1016/j.curtheres.2014.09.004
17. Glinkova V, Shevah O, Boaz M, Levine A, Shirin H. Hepatic haemangiomas: possible association with female sex hormones. *Gut*. Sep 2004;53(9):1352-5. doi:10.1136/gut.2003.038646
18. Ozakyol A, Kebapci M. Enhanced growth of hepatic hemangiomatosis in two adults after postmenopausal estrogen replacement therapy. *Tohoku J Exp Med*. Nov 2006;210(3):257-61. doi:10.1620/tjem.210.257
19. Gemer O, Moscovici O, Ben-Horin CL, Linov L, Peled R, Segal S. Oral contraceptives and liver hemangioma: a case-control study. *Acta Obstet Gynecol Scand*. Dec 2004;83(12):1199-201. doi:10.1111/j.0001-6349.2004.00551.x
20. Sakamoto Y, Kokudo N, Watadani T, et al. Proposal of size-based surgical indication criteria for liver hemangioma based on a nationwide survey in Japan. *J Hepatobiliary Pancreat Sci*. Jul 2017;24(7):417-425. doi:10.1002/jhbp.464
21. Oak CY, Jun CH, Cho EA, et al. Hepatic Hemangioma with Kasabach-Merritt Syndrome in an Adult Patient. *Korean J Gastroenterol*. Apr 25 2016;67(4):220-223. doi:10.4166/kjg.2016.67.4.220
22. Liu X, Yang Z, Tan H, Zhou W, Su Y. Fever of Unknown Origin Caused by Giant Hepatic Hemangioma. *J Gastrointest Surg*. Feb 2018;22(2):366-367. doi:10.1007/s11605-017-3522-y
23. Klotz T, Montoriol PF, Da Ines D, Petitcolin V, Joubert-Zakeyh J, Garcier JM. Hepatic haemangioma: common and uncommon imaging features. *Diagn Interv Imaging*.

- Sep 2013;94(9):849-59. doi:10.1016/j.diii.2013.04.008
24. Maruyama S, Matono T, Koda M. Prevalence and Characteristics of Hepatic Hemangioma Associated with Coagulopathy and Its Predictive Risk Factors. *J Clin Med*. Jul 26 2022;11(15)doi:10.3390/jcm11154347
  25. Wang HY, Zhang L, Wu J, et al. Adult hepatic cavernous hemangioma with highly elevated  $\alpha$ -fetoprotein: A case report and review of the literature. *Oncol Lett*. Feb 2015;9(2):637-640. doi:10.3892/ol.2014.2769
  26. Jang S, Choi GH, Chang W, Jang ES, Kim JW, Jeong SH. Elevated alpha-fetoprotein in asymptomatic adults: Clinical features, outcome, and association with body composition. *PLoS One*. 2022;17(7):e0271407. doi:10.1371/journal.pone.0271407
  27. Navale P, Habib M, Stueck A, Fiel MI. Hepatic Sclerosing Hemangioma Simulating Gallbladder Carcinoma: A Rare Case. *J Clin Exp Hepatol*. Dec 2018;8(4):474-477. doi:10.1016/j.jceh.2018.07.003
  28. Sweed DM, Fayed ZA, Sweed EM, El-Sherif A, Mohamady M. Hepatic sclerosing hemangioma mimics hepatic malignancies: a case report and multidisciplinary approach. *Egyptian Liver Journal*. 2019;9(1):1-5.
  29. Huang M, Zhao Q, Chen F, You Q, Jiang T. Atypical appearance of hepatic hemangiomas with contrast-enhanced ultrasound. *Oncotarget*. Feb 27 2018;9(16):12662-12670. doi:10.18632/oncotarget.24185
  30. Lin Z, Zhu X, Zhou J. Ultrasound-guided percutaneous sclerotherapy versus surgical resection in the treatment of large hepatic hemangiomas: a retrospective study. *BMC Surg*. Apr 07 2022;22(1):130. doi:10.1186/s12893-022-01574-3
  31. Kim JM, Chung WJ, Jang BK, et al. Hemorrhagic hemangioma in the liver: A case report. *World J Gastroenterol*. Jun 21 2015;21(23):7326-30. doi:10.3748/wjg.v21.i23.7326
  32. Sandulescu LD, Urhut CM, Sandulescu SM, Ciurea AM, Cazacu SM, Iordache S. One stop shop approach for the diagnosis of liver hemangioma. *World J Hepatol*. Dec 27 2021;13(12):1892-1908. doi:10.4254/wjh.v13.i12.1892
  33. Dietrich CF, Nolsøe CP, Barr RG, et al. Guidelines and Good Clinical Practice Recommendations for Contrast-Enhanced Ultrasound (CEUS) in the Liver-Update 2020 WFUMB in Cooperation with EFSUMB, AFSUMB, AIUM, and FLAUS. *Ultrasound Med Biol*. Oct 2020;46(10):2579-2604. doi:10.1016/j.ultrasmedbio.2020.04.030
  34. Sekej M, Vadrnjak Đonlagić S, Ključevšek D. Contrast-Enhanced Ultrasound for the Characterization of Infantile Hepatic Hemangioma in Premature Neonate. *Cureus*. Aug 05 2020;12(8):e9580. doi:10.7759/cureus.9580
  35. Strobel D, Seitz K, Blank W, et al. Tumor-specific vascularization pattern of liver metastasis, hepatocellular carcinoma, hemangioma and focal nodular hyperplasia in the differential diagnosis of 1,349 liver lesions in contrast-enhanced ultrasound (CEUS). *UltraschallMed*. Aug 2009;30(4):376-82. doi:10.1055/s-0028-1109672
  36. Terriff BA, Gibney RG, Scudamore CH. Fatality from fine-needle aspiration biopsy of a hepatic hemangioma. *AJR Am J Roentgenol*. Jan 1990;154(1):203-4. doi:10.2214/ajr.154.1.2104717
  37. Davies R. Haemorrhage after fine-needle aspiration biopsy of a hepatic hemangioma. *Med J Aust*. Mar 01 1993;158(5):364. doi:10.5694/j.1326-5377.1993.tb121823.x
  38. Qu C, Liu H, Li XQ, Feng K, Ma K. Percutaneous ultrasound-guided 'three-step' radiofrequency ablation for giant hepatic hemangioma (5-15 cm): a safe and effective new technique. *Int J Hyperthermia*. 2020;37(1):212-219. doi:10.1080/02656736.2020.1732484
  39. Baimakhanov Z, Kaniyev S, Serikuly E, et al. Radical. *JGH Open*. Oct 2021;5(10):1179-1182. doi:10.1002/jgh3.12649
  40. Liu Y, Wei X, Wang K, et al. Enucleation versus Anatomic Resection for Giant Hepatic Hemangioma: A Meta-Analysis. *Gastrointest Tumors*. Mar 2017;3(3-4):153-162. doi:10.1159/000455846
  41. Jinhuan Y, Gang D, Binyao S, Huan M, Bin J. Is laparoscopic hepatectomy suitable for giant hepatic hemangioma larger than 10 cm in diameter? *Surg Endosc*. Mar 2020;34(3):1224-1230. doi:10.1007/s00464-019-06880-1
  42. Cheng WL, Qi YQ, Wang B, Tian L, Huang W, Chen Y. Enucleation versus hepatectomy for giant hepatic haemangiomas: a meta-analysis. *Ann R Coll Surg Engl*. Mar 2017;99(3):237-241. doi:10.1308/rcsann.2016.0349
  43. Liu Q, Liu F, Ding J, Wei Y, Li B. Surgical outcomes and quality of life between laparoscopic and open approach for hepatic hemangioma: A propensity score matching analysis. *Medicine (Baltimore)*. Feb 2019;98(6):e14485. doi:10.1097/MD.00000000000014485
  44. Zhang W, Huang ZY, Ke CS, et al. Surgical Treatment of Giant Liver Hemangioma Larger Than 10cm: A Single Center's Experience With 86 Patients. *Medicine (Baltimore)*. Aug 2015;94(34):e1420.

- doi:10.1097/MD.0000000000001420
45. Li H, Duan X, Wu Z, Qin Y. Feasibility of laparoscopic enucleation for hemangioma in special hepatic segments. *Front Surg.* 2022;9:1111307. doi:10.3389/fsurg.2022.1111307
  46. ChandraBose K, Ramanujam A, Muthu Y. Enucleation of a Giant Hemangioma of Liver: Old School Revisited. *Case Rep Surg.* 2015;2015:234767. doi:10.1155/2015/234767
  47. Rajakannu M, Pascal G, Castaing D, et al. Revisiting the Surgical Management of Giant Hepatic Hemangiomas: Enucleation Versus Anatomical Resection? *J Clin Exp Hepatol.* 2021;11(3):321-326. doi:10.1016/j.jceh.2020.09.008
  48. Sundar Alagusundaramoorthy S, Vilchez V, Zanni A, et al. Role of transplantation in the treatment of benign solid tumors of the liver: a review of the United Network of Organ Sharing data set. *JAMA Surg.* Apr 2015;150(4):337-42. doi:10.1001/jamasurg.2014.3166
  49. Lee JH, Yoon CJ, Kim YH, et al. Living-donor liver transplantation for giant hepatic hemangioma with diffuse hemangiomatosis in an adult: a case report. *Clin Mol Hepatol.* Jun 2018;24(2):163-168. doi:10.3350/cmh.2017.0002
  50. Ribeiro MA, Papaiordanou F, Gonçalves JM, Chaib E. Spontaneous rupture of hepatic hemangiomas: A review of the literature. *World J Hepatol.* Dec 27 2010;2(12):428-33. doi:10.4254/wjh.v2.i12.428
  51. Efthimiadis C, Ioannidis A, Grigoriou M, Kofina K, Lazaridis M, Kosmidis C. Robotic right segmental hepatectomy for the treatment of a giant hepatic hemangioma-a case report. *J Surg Case Rep.* Jun 2017;2017(6):rjx118. doi:10.1093/jscr/rjx118
  52. Ohkura Y, Hashimoto M, Lee S, Sasaki K, Matsuda M, Watanabe G. Right hepatectomy for giant cavernous hemangioma with diffuse hemangiomatosis around Glisson's capsule. *World J Gastroenterol.* Jul 07 2014;20(25):8312-6. doi:10.3748/wjg.v20.i25.8312
  53. Gao J, Fan RF, Yang JY, et al. Radiofrequency ablation for hepatic hemangiomas: A consensus from a Chinese panel of experts. *World J Gastroenterol.* Oct 21 2017;23(39):7077-7086. doi:10.3748/wjg.v23.i39.7077
  54. Furumaya A, van Rosmalen BV, Takkenberg RB, et al. Transarterial (Chemo-) Embolization and Lipiodolization for Hepatic Haemangioma. *Cardiovasc Intervent Radiol.* Jun 2019;42(6):800-811. doi:10.1007/s00270-019-02169-x
  55. Kalogirou M, Chourmouzi D, Dedes I, Kiapidou S, Akriviadis E, Sinakos E. Transarterial embolization for the treatment of complicated liver hemangiomas: A report of two cases and review of the literature. *Clin Mol Hepatol.* Sep 2018;24(3):345-349. doi:10.3350/cmh.2017.0075
  56. Yamamoto T, Kawarada Y, Yano T, Noguchi T, Mizumoto R. Spontaneous rupture of hemangioma of the liver: treatment with transcatheter hepatic arterial embolization. *Am J Gastroenterol.* Nov 1991;86(11):1645-9.
  57. Ismailova G, Yenin E, Kaniev S, et al. Hepatocellular carcinoma: Diagnostic criteria and surgical treatment. *New Armenian Medical Journal.* 2017 2017;11(4):45-50.
  58. Torkian P, Li J, Kaufman JA, Jahangiri Y. Effectiveness of Transarterial Embolization in Treatment of Symptomatic Hepatic Hemangiomas: Systematic Review and Meta-analysis. *Cardiovasc Intervent Radiol.* Jan 2021;44(1):80-91. doi:10.1007/s00270-020-02611-5
  59. Sun JH, Nie CH, Zhang YL, et al. Transcatheter Arterial Embolization Alone for Giant Hepatic Hemangioma. *PLoS One.* 2015;10(8):e0135158. doi:10.1371/journal.pone.0135158
  60. Srinivas D, Sarma P, Shukla D, et al. Multimodality Management of Cavernous Sinus Hemangiomas-An Institutional Experience. *J Neurol Surg B Skull Base.* Oct 2017;78(5):399-407. doi:10.1055/s-0037-1602790
  61. Yoon SS, Charny CK, Fong Y, et al. Diagnosis, management, and outcomes of 115 patients with hepatic hemangioma. *J Am Coll Surg.* Sep 2003;197(3):392-402. doi:10.1016/S1072-7515(03)00420-4



# ANALYSIS OF THE HISTORY OF THE SEARCH FOR METHODS OF PROTECTING THE BRAIN DURING OPERATIONS ON THE INTERNAL CAROTID ARTERY

Konyssov M.N.<sup>1</sup>, Batrashov V.A.<sup>2</sup>, Sukhareva T.V.<sup>3</sup>, Madeshov E.K.<sup>1</sup>,  
Morozov K.M.<sup>4</sup>, Kadyrov Zh.E.<sup>1</sup>, Konyssova S.A.<sup>1</sup>.

<sup>1</sup>Atyrau Regional Cardiology Center, Atyrau, Republic of Kazakhstan

<sup>2</sup>National Medical and Surgical Center named after N. I. Pirogov of the Ministry of Health of the Russian Federation. Moscow

<sup>3</sup>City hospital of the city of Korolev, Moscow region. Russian Federation.

<sup>4</sup>MMC Clinic Moscow Russian Federation

## Abstract

The review covers the first studies of the vessels of the brain. The history of the emergence and development of the doctrine of protecting the brain during operations on the carotid arteries is given. Experience has been accumulated in the development of the doctrine of surgical protection of the brain during primary operations on the carotid arteries and compression of the carotid arteries. The analysis of existing and existing methods was carried out. Based on the above analysis, ways of further development of methods of protecting the brain during operations on the carotid arteries are shown.

<https://doi.org/10.35805/BSK2023IV002>

Konyssov M.N.  
orcid.org/0000-0002-7848-4231  
Batrashov V.A.  
orcid.org/0009-0002-9766-4518  
Sukhareva T.V.  
orcid.org/0000-0002-0073-160X  
Madeshov E.K.  
orcid.org/0009-0003-4733-3929  
Morozov K.M.  
orcid.org/0000-0002-4167-5261  
Kadyrov Zh.E.  
orcid.org/0009-0007-6577-0304  
Konyssova S.A.  
orcid.org/0009-0003-9077-2425

**For correspondence:**  
Konissov M.N., Atyrau Regional  
Cardiology Center, Atyrau,  
Republic of Kazakhstan  
Phone: +7 7014200167  
E-mail: mconus@mail.ru

**Conflict of interest:**  
The authors declare that they  
have no conflicts of interest

**Keywords:**  
surgery, internal carotid artery,  
brain protection, compression  
carotid artery.

## Ішкі ұйқы артериясына операция жасау кезінде миды қорғау әдістерін іздеу тарихын талдау

Коньсов М.Н.<sup>1</sup>, Батрашов В.А.<sup>2</sup>, Сухарева Т.В.<sup>3</sup>, Мадешов Е.К.<sup>1</sup>,  
Морозов К.М.<sup>4</sup>, Кадыров Ж.Е.<sup>1</sup>, Коньсова С.А.<sup>1</sup>.

<sup>1</sup>Атырау облыстық кардиологиялық орталығы, Атырау,  
Қазақстан Республикасы

<sup>2</sup>Ресей Федерациясы Денсаулық сақтау министрлігінің Н. И. Пирогов атындағы Ұлттық медициналық-хирургиялық орталығы. Мәскеу

<sup>3</sup>Мәскеу облысының Королев қаласындағы 3-ші қалалық аурухана.  
Ресей Федерациясы.

<sup>4</sup>ММС клиникасы Мәскеу, Ресей Федерациясы

## Түйіндеме

Шолуда ми тамырларының алғашқы зерттеулері қамтылған. Каротид артерияларына операция жасау кезінде миды қорғау туралы ілімнің пайда болуы мен даму тарихы келтірілген. Каротид артерияларына алғашқы операциялар жасау және каротид артерияларын қысу кезінде миды хирургиялық қорғау туралы ілімді дамыту тәжірибесі жинақталған. Қолданыстағы және қолданыстағы әдістерге талдау жасалды. Жоғарыда келтірілген талдау негізінде каротид артерияларындағы операциялар кезінде миды қорғау әдістерін одан әрі дамыту жолдары көрсетілген.

**Хат алысатын автор:**  
Коньсов М.Н., Атырау  
облыстық кардиологиялық  
орталығы, Атырау,  
Қазақстан Республикасы  
телефон: +7 7014200167  
E-mail: mconus@mail.ru

**Мүдделер қақтығысы:**  
Авторлар мүдделер  
қақтығысының жоқтығын  
мәлімдейді

**Түйінді сөздер:**  
Хирургия, ішкі ұйқы артериясы,  
ұйқы артерияларын қысу миды  
қорғау.

## Анализ истории поиска методов защиты головного мозга при операциях на внутренней сонной артерии

Коньсов М.Н.<sup>1</sup>, Батрашов В.А.<sup>2</sup>, Сухарева Т.В.<sup>3</sup>, Мадешов Е.К.<sup>1</sup>,  
Морозов К.М.<sup>4</sup>, Кадыров Ж.Е.<sup>1</sup>, Коньсова С.А.<sup>1</sup>.

Автор для корреспонденции:  
Коньсов М.Н., Атырауский  
областной кардиологический  
центр, Атырау,  
Республика Казахстан  
телефон: +7 7014200167  
E-mail: mconus@mail.ru

Конфликт интересов:  
Авторы заявляют об отсутствии  
конфликта интересов

<sup>1</sup>Атырауский областной кардиологический центр, Атырау, Республика  
Казахстан

<sup>2</sup>Национальный медико-хирургический центр имени Н.И. Пирогова  
Министерства здравоохранения Российской Федерации. Москва

<sup>3</sup>3-я городская больница города Королева Московской области.  
Российская Федерация.

<sup>4</sup>Клиника ММС Москва, Российская Федерация

#### Аннотация

В обзоре освещены первые исследования сосудов головного мозга. Приведена история зарождения и развития учения о защите головного мозга при операциях на сонных артериях. Обобщен опыт первых операций на сонных артериях и развития учения о хирургической защите головного мозга при пережатии сонных артерий. Проведен анализ существовавших и существующих методов. На основании приведенного анализа, намечены пути дальнейшего развития методов защиты головного мозга при операциях на сонных артериях.

#### Ключевые слова:

Хирургия, внутренняя сонная  
артерия, защита мозга, сжатие  
сонной артерии.

#### Introduction

The relevance of stroke prevention at the moment is beyond doubt. However, if the actual operation on the carotid arteries is quite well developed, then the question remains unresolved of how to protect the brain from ischemia and the subsequent development of stroke in the perioperative period.

Up to 60% of cerebrovascular complications occur during the intraoperative period. Complications of operations on extracranial arteries include ischemic brain damage (32%), distal arterio-arterial embolism, when the common carotid artery is clamped, as well as haemorrhagic hyper perfusion injuries (29%).<sup>1</sup>

Carotid artery surgery is a relatively young discipline. The first successful endarterectomy was performed on August 7, 1953 by *M. De Bakey*, then a 53-year-old man with transient ischemic attacks.<sup>2,3</sup>

However, it is generally accepted that, approximately 1 year later, an operation was performed that became the impetus for the development of carotid surgery, carried out by *Eastcott H., Pickering G., Rob C.* on May 19, 1954, reporting this in the November issue of «The Lancet». In subsequent years, scientists such as *De Bakey M., Crawford E., Cooley D., Morris G.J. and Wylie E.* had a significant influence on the development of surgery for occlusive-stenotic lesions of the carotid arteries.<sup>2,3</sup>

To date, no one doubts that carotid endarterectomy is an effective method for preventing stroke. The dawn of study occurred in the 90s and the beginning of the 21st century.<sup>5,6,7,8</sup>

The first significant description of the carotid arteries was made by the Swiss physician *Johann Jakob Wepfer* in 1658, who noted the hemispheric blood supply to the brain by the carotid arteries and was the first to document the relationship between changes in the arteries

and symptoms of cerebral ischemia. Later, *Thomas Willis* expanded the works of *J.J. Wepfer* and other researchers and in 1664 published a work on cerebral anatomy (*Cerebri Anatome*) with detailed illustrations by *Christopher Wren*, in which he explained the true significance of the vascular anastomoses of the base of the brain.<sup>9</sup>

Key importance in ensuring the safety of surgery on the carotid arteries is given to preoperative assessment of the state of the circle of Willis and monitoring of cerebral circulation during clamping of the internal carotid artery (ICA). This research was based on the classic works of *Matas R.*, who published his results in 1911. The purpose of the study is to manually clamp the contralateral carotid artery.<sup>10</sup>

An important role is played by angiography, which provides information about the angioarchitecture of the circle of Willis, topical localization, the degree of damage to the brachiocephalic arteries (BCA) and the pathways of collateral circulation of the brain (CBF).<sup>11,12</sup> This can be achieved using various modifications of ultrasound examination, which make it possible to develop new diagnostic criteria for ICA stenosis.<sup>11,12</sup>

Multislice computed tomographic angiography (MSCT AG) is a highly informative method for studying the angioarchitecture of the carotid arteries. Using this method, it is possible to obtain an image of the vessels supplying the brain from the aortic arch along its entire length, to assess the degree of stenosis of the carotid arteries, and to identify lesions of intracranial vessels.<sup>13,14</sup>

When using perfusion computed tomography (PCT) in the preoperative period, it is possible to assess the state of cerebral blood flow and possible risk factors for the development of complications after surgery. The disadvantages of PCT include the need to administer a contrast

agent and radiation exposure.<sup>15,16,17,18</sup>

Another method is magnetic resonance angiography (MRA) without the administration of a contrast agent, which can detect narrowing of the lumen of the carotid arteries in both intra- and extracranial sections with sensitivity and specificity of about 93% and 88%, respectively.<sup>17,19,20,21</sup>

There is no consensus on whether it is possible to predict the development of hyperperfusion syndrome in the postoperative period using available technologies for studying changes in cerebral blood flow (ultrasound, CT perfusion, MR perfusion).<sup>13,21</sup>

Rheoencephalography (REG), although the method is considered outdated, has also not lost its clinical significance.<sup>22</sup> An achievement of modern medicine is the assessment of CBF by radioisotope methods, which make it possible to quantitatively and qualitatively characterize regional blood circulation.<sup>23</sup>

Protection of the brain during arrest of blood flow through the internal carotid artery remains extremely important, regardless of the state of the arterial circle at the base of the brain. A situation that arises when it is necessary to operate on pathological tortuosity.

Historically, three directions have developed.

#### **Craniohypothermia**

Mechanisms that protect the brain during ischemia are few. *Duffy T.E et.al.* in 1972 obtained evidence that with a lack of oxygen, the oxidative metabolism of the brain is immediately inhibited, which leads to a kind of hypoxic anaesthesia (cited by *Plum F., Posner J.B.*).<sup>24</sup> Subsequently, 3 mechanisms of tissue protection from the damaging effects of lactate were described.<sup>25</sup> The presence of lactate dehydrogenase isoenzymes has been shown to control tissue lactate levels, leaching lactate into the bloodstream followed by buffering and preparation for metabolic use of lactate. About the possibility of using lactate by the brain, which increases in the blood in small quantities during hypoxia? Lactate takes part in the synthesis of glycogen, as shown by the results of a study in 1964 (cited from *Labori G. 1974*).<sup>26</sup> The ability to biosynthesize glucose (gluconeogenesis) from intermediate metabolites (pyruvate, lactate, amino acids, etc.) has been shown by a number of researchers.<sup>27</sup>

The cause of acute ischemia is a lack of cerebral blood flow. There are several degrees of critical levels of response of brain tissue to this ischemia. Cerebral ischemia is characterized by a decrease in cerebral blood flow to 70-80% of the normal value. At the first level of decrease it is i.e., less than 50-55 ml/100 g of brain tissue/min.<sup>28</sup> At the second level, a decrease in perfusion to 10-15 ml/100 g of brain tissue/min and below leads to rapid and severe cell damage with the

formation of an ischemic nucleus, activation of anaerobic glycolysis, increased extraction of lactate from the blood, development of lactic acidosis up to the development of toxic cerebral oedema.<sup>28,29,30,31,32,33,34,35,36</sup>

The third level is the most studied, with destabilization of cell membranes, disruption of ion transport channels, and release of excessively excitatory neurotransmitters.<sup>37</sup>

Along the periphery of the ischemic core, neuronal damage develops much more slowly, due to the supporting system of collaterals, which allows maintaining the level of perfusion above the threshold leading to cell death. This zone contains viable cells with partially preserved integrity of cellular structures, but with reduced functional activity, which makes them maximally vulnerable to pathogenic processes that disrupt their metabolic balance.<sup>35</sup> The cells most sensitive to ischemia are neurons, and to a lesser extent are oligodendrocytes, astrocytes and vascular endothelium.<sup>36,37</sup>

*V. Fitch*, considering the trigger point of ischemic damage to brain cells as an imbalance between provision and need, makes a simple conclusion about the possibility of influencing this ratio, increasing provision and reducing needs.<sup>38</sup> To improve the supply of the brain, artificial hypertension and hypervolemic hemodilution are proposed, and to reduce the need, artificial hypothermia and pharmacological reduction of the functional activity of the brain are proposed.

Metabolic inhibition in combination with increased oxygen delivery is the basis for the prevention of ischemia. Back in 1969, researchers noticed that an increase in systemic blood pressure (BP) with the normal structure of the circle of *Willis* leads to an increase in cerebral blood flow (CBF) and cerebral perfusion, which is described by the formula  $CBF = CPP / CVR$ , where CBF is volumetric blood flow, CPP - cerebral perfusion pressure, CVR-cerebral vascular resistance and, accordingly, improved cerebral oxygenation.<sup>39</sup> The method of artificial hypertension based on these observations has found its place in surgery of the brachycephalic arteries, but its effectiveness is quite questionable, since anatomical studies have shown that a symmetrical and closed circle of *Willis* occurs in only 28% of people. In addition, arterial hypertension as an adaptive reaction of the body in patients with cerebrovascular insufficiency occurs only in 20-30% of cases,<sup>40</sup> due to the lack of a linear relationship between the level of systemic blood pressure (SBP) and CBF due to the phenomenon of autoregulation. By studying the dependence of cerebral oxygenation on cerebral perfusion pressure (CPP), a two-phase nature was revealed. When  $CPP < 70 \text{ mmHg}$  the relationship between it and oxygen saturation

in the jugular vein bulb is linear. This implies the advisability of maintaining cerebral blood flow above the threshold level by stabilizing SBP. For this purpose, in 1997 *Dirden N.M.* recommended inotropic support with norepinephrine and phenylephrine, due to the ability of these drugs to increase SBP without adverse effects on intracranial pressure (ICP).<sup>41</sup>

Intraoperative protection of the brain during temporary occlusion of the internal carotid artery remains a serious aesthetic problem, the solution of which largely determines the success of the operation. The Novosibirsk Research Institute of Circulatory Pathology has accumulated extensive experience in the use of hypothermia in cardiac surgery; it has been proven that moderate hypothermia creates a significantly more favourable effect, since it does not carry side effects associated with hypothermia itself.<sup>41,42</sup>

The decrease in oxygen consumption by brain tissue at 32°C, according to various authors, is 45±5%.<sup>43</sup> Studying the effect of temperature on CBF during artificial circulation, by collecting blood from the radial artery and the bulb of the internal jugular vein (IJV) we came to concluded that a decrease in temperature from 37 to 27°C led to a 64% decrease in brain O<sub>2</sub> consumption. The reduction in oxygen consumption rate (CMR) with a decrease in temperature from 37 to 27°C ranges from 50 to 80%.<sup>44</sup> Along with a decrease in oxygen consumption in the brain, there is a decrease in CBF by 5–7% upon cooling by 1°C.<sup>45</sup>

According to modern concepts, hypothermia also increases the latent period of anoxic depolarization, which reduces both the release and excitotoxic effect of excitatory neurotransmitters (glutamate, aspartate, and glycine).<sup>46,47,48</sup>

Experimental evidence suggests that hypothermia may be the most potent technique for providing cerebral protection,<sup>49</sup> but hypothermia administered after ischemia only delays neuronal death.

In summary, it can be stated that the attempt to protect the brain with local hypothermia (covering the head with ice during surgery), which appeared in the 80s of the last centuries, did not become widespread. In 2004, a dissertation for the academic degree of Candidate of Medical Sciences was defended in Novosibirsk. The author points out in the conclusions that craniocerebral cooling reaching a temperature in the nasopharynx of 33-34°C in patients with unilateral and bilateral hemodynamically significant atherosclerotic lesions of the carotid arteries under conditions of multicomponent general anaesthesia makes it possible to safely perform long-term (up to 60 minutes or more) surgical reconstruction of the internal carotid arteries. However, the same conclusions indicate

that surgical intervention on the carotid arteries under anaesthetic conditions, including the use of a halogen-containing anaesthetic, like phthorothane up to 1 vol%, sodium thiopental 4-5 mg/kg, ataralgia and craniocerebral hypothermia is characterized by reliable anti-ischemic protection of the brain during the period of temporary occlusion internal carotid artery. However, phthorothan and sodium thiopental “protect” the brain from ischemic damage, as many researchers point out,<sup>50,51,52</sup> so it is apparently premature to talk about the correctness of the conclusions made in the dissertation work. In 2005, the results were published in a dissertation also for the degree of candidate of medical sciences, the author makes ambiguous conclusions: “The consequence of craniocerebral hypothermia using the external cooling method is tension and ineffectiveness of compensatory mechanisms in the early post-hypothermic period”. Although the research work is devoted to the protection of the brain during operations with artificial circulation, this does not change the essence of the conclusions.

It should be noted that now, in carotid artery surgery, the method is practically not used.

To date, two main directions have emerged in protecting the brain during clamping of the ICA: 1. Surgical (placement of a temporary shunt) and 2. Pharmacological protection. If the first one remained practically unchanged, only the indications for installing a temporary shunt were clarified, then the second one is constantly developing and expanding.

#### Surgical part

Temporary cessation of blood flow through the carotid artery during carotid endarterectomy (CEA) can be prevented by using a temporary shunt. Two studies, including 590 patients, compared the results of CEA with routine bypass and without bypass. Another study of 131 patients compared the results of CEA using a combination of EEG to monitor and measure carotid retrograde pressure with isolated retrograde pressure measurement to determine the need for a temporary shunt.<sup>53,54</sup> There was no statistically significant difference in the incidence of all strokes, ipsilateral strokes, or deaths within 30 days after surgery between patients who routinely used a temporary shunt and those who did not, although the study data were limited. There was also no significant difference in the risk of ipsilateral stroke in patients selected for shunting using EEG combined with retrograde pressure measurements compared with those in the group in which the indication for a temporary shunt was determined using retrograde pressure measurements alone, although the data were also limited.<sup>55</sup> There was no statistically significant difference in the incidence of all strokes, ipsilateral strokes, or deaths within 30 days after

surgery in the group of patients with routine use of a temporary shunt and the group with complete refusal to use it.<sup>56</sup> In 2009, the results of studies conducted from 2005 to 2007 were published, the authors concluded that the routine use of an internal shunt is preferable, arguing that cerebral ischemia can also be caused by stenosis of the contralateral carotid artery.<sup>57</sup> In the large ECST study, which included 1729 patients, there was no statistically significant difference in the risk of intraoperative complications associated with the use of a temporary shunt, the use of expansion patches, intraoperative EEG monitoring, or the type of anaesthesia.<sup>58</sup>

Currently, many researchers are evaluating the capabilities of transcranial oximetry in assessing cerebral oxygenation.<sup>59,60,61,62,63</sup>

A decrease in haemoglobin oxygen saturation due to an increase in oxygen extraction from flowing blood is one of the first signs of developing tissue hypoxia and ischemia. Using transcranial oximetry during reconstructive operations on the carotid arteries, we came to the conclusion that this method makes it possible to assess in real time the degree of cerebral ischemia both during test clamping and during the main stage, to make a timely decision on additional methods of protecting the brain, and after completion of the reconstructive stage of the operation, immediately evaluate the effectiveness of revascularization.<sup>60,61,62</sup>

The discussion ended with the Russian Clinical Guidelines, which formulated the following recommendation: Selective use of a temporary shunt. is preferable. To intraoperatively determine the indications for the use of a temporary shunt, one of the following methods should be used: – measurement of retrograde pressure in the ICA, – measurement of blood flow velocity in the middle cerebral artery (MCA) using TCDG monitoring, cerebral oximetry (level of evidence B).<sup>64</sup>

#### **Anaesthesia**

Since the mid-1950s, CEA has traditionally been performed under general anaesthesia. Subsequently, since the 1970s, regional anaesthesia (RA) was developed and introduced to provide anaesthetic management for patients at high surgical risk, which became a real alternative for general anaesthesia. Currently, the main directions in the choice of anaesthesia during operations on the carotid arteries are general anaesthesia, regional anaesthesia, as well as combined anaesthesia (CA), which is a combination of them.<sup>65,66,67,68,69</sup>

Research has still not given a clear answer to the question - which of the above methods has undeniable advantages.<sup>70,71,72,73,74</sup> Studies and scientific articles indicate both the advantages and disadvantages of each method of pain relief for CEA.<sup>66,71,75,76</sup>

Regional or general anaesthesia CEA reduces the risk of stroke in people with symptoms of a recent stroke and significant carotid stenosis. However, there is a significant perioperative risk that can be reduced by performing the procedure under local (preferred) or general anaesthesia. The Cochrane review included 6 randomized studies totalling 554 operations, as well as a non-randomized study with 25.662 operations,<sup>77,78,79,80,81</sup> totalling 554 operations and 41 non-randomized studies with 25.662 operations.<sup>82</sup> The methodological quality of non-randomized studies is controversial. Eleven of these studies were prospective, 29 were performed in consecutive series of patients. In nine non-randomized studies, the number of arteries compared to patients was imprecise. A meta-analysis of non-randomized studies found that the use of local anaesthesia was associated with significant reductions in death (35 studies), stroke (31), stroke or death (26), myocardial infarction (22), and pulmonary complications (7 studies) within 30 days of surgery. A meta-analysis of randomized trials found that the use of local anaesthesia is associated with a significant reduction in bleeding within 30 days after surgery, but there is no evidence of a reduction in intraoperative stroke. However, the volume of studies was small to draw a clear conclusion, and in some studies, the results of the analysis obviously supported the chosen treatment method, therefore, they are not suitable for analysis. The GALA (General Anaesthesia vs Local Anaesthesia) study is the largest randomized surgical and anaesthesiology trial, including 3526 patients treated at 95 centres in 24 countries.<sup>83</sup> This double-arm, parallel-group, multicentre randomized controlled trial was designed to determine whether type of anaesthesia affects perioperative all-cause and stroke mortality, short-term quality of life, and stroke-free and heart attack-free outcomes at one year of follow-up.<sup>84</sup>

In 2023, the European Community summarized the results of a comparison between RA and GA,<sup>85</sup> noting that there is still controversy regarding whether CEA should be performed under regional anaesthesia (RA) or general anaesthesia (GA). The General Anaesthesia vs Local Anaesthesia study (n = 3.526) was the largest randomized controlled trial (RCT). There was no difference in the perioperative incidence of death, stroke or myocardial infarction between the GA (4.8%) and RA (4.5%) groups.<sup>83</sup> However, pooled data from five RCTs showed a reduction in the 30-day incidence of stroke/death when performing CEA under RA,<sup>85</sup> while NIBL (New ischemic brain lesion) occurred more often in the GA group (17.1% compared with 6.7%).<sup>86</sup>

According to the National Surgical Quality Improvement Initiative of the American College

of Surgeons, RA is associated with shorter operative and hospital stays, fewer readmissions, fewer cases of postoperative pneumonia, and fewer blood transfusions.<sup>87,88</sup> However, RA was associated with lower patient satisfaction (65% versus 93%) and was less likely to be considered for future treatment (61% versus 97%).<sup>88</sup> In a large meta-analysis (25 observational studies, six RCTs [n = 152.376]), RA was associated with statistically significantly shorter operative time, lower perioperative rates of stroke, cardiac complications, and lower mortality.<sup>89</sup> However, the RCT did not find statistically significant differences in any endpoint.<sup>89</sup> Some authors believe that RCTs have lack of sufficient statistical power.<sup>90</sup>

In a systematic review of 69 studies (n = 10.081), combined deep + superficial cervical plexus block was associated with a statistically significantly higher complication rate.<sup>91</sup>

The ESVS recommendations regarding the management of RA versus GA are the same as those in the SVS guideline and the German-Austrian guideline, stated as follows: The decision regarding the choice of anaesthesia (regional or general) in patients undergoing carotid endarterectomy should be made at the discretion of the surgeon/anaesthesiologist, performing the procedure, taking into account local experience, patient preferences and preferred antiplatelet therapy strategy.<sup>92,93</sup>

#### **Pharmacological protection of the brain in CEA**

One of the first works devoted to pharmacological protection of the brain, apparently, is the work of *J. R. Kenyon, A. B. Thomas, D. P. Goodwin*, published in 1972.<sup>94</sup> In a consecutive series of thirty-four total operations in thirty-one patients hospitalized with stenotic lesions of the internal carotid artery, heparin (3 mg per kg body weight), administered systemically and regionally, was the only method of cerebral protection for arterial insufficiency. The arrest of blood flow by carotid artery (CA) varied from 7 to 30.5 minutes (average 15.3 minutes). Ten patients (32%) had more than one lesion. There were no deaths or immediate neurological consequences. Two patients experienced transient ischemic attacks 2 and 5 days after surgery, but they resolved completely within 24 hours and were attributed to technical reasons.

According to most authors, the use of local anaesthetics allows for adequate analgesia in carotid surgery: pain relief is provided either by tissue infiltration or by blocking the cervical plexus along with infusion of small doses of fentanyl or droperidol to achieve sedation.<sup>95,96,97,98,99</sup> The main argument of supporters of regional anaesthesia during CE is the possibility of direct assessment of the functional state of the central

nervous system and timely diagnosis of brain ischemia. When the first signs of neurological deficit appear, the generally accepted method of preventing irreversible hypoxia of the brain remains the use of a shunt.<sup>100,101</sup> The relative simplicity and low cost of local anaesthesia and the ability to selectively use an internal shunt are the indisputable advantages of this method of pain relief in carotid surgery.

General anaesthesia (GA) increases the brain's tolerance to hypoxia, reducing its oxygen demand.<sup>102,103</sup> Under anaesthesia, it becomes possible to use techniques that potentiate its antihypoxic effect during the period of carotid reconstruction. For this purpose, phthorothane inhalation, artificial hypertension, infusion of antihypoxants, hyperoxygenation and their combinations are used.

Much work has been devoted to the study of hypercapnia as a method of protecting the brain, but it has been found that adding 2-5% carbon dioxide to an inhaled drug mixture or performing temporary hypoventilation can cause intracerebral steal.<sup>104</sup>

The ability of barbiturates to inhibit the metabolic processes of the brain, in particular, oxygen consumption, is used in carotid surgery: thiopental infusion is carried out immediately before the occlusion stage or during the entire operation; however, the depressive effect of barbituric anaesthesia on haemodynamic makes it necessary to use this method of protecting the brain with caution.

Currently, the main directions in the choice of anaesthesia during operations on the carotid arteries are general anaesthesia, regional anaesthesia, as well as combined anaesthesia (CA), which is a combination of them.<sup>105</sup>

In clinical practice, depending on the specific clinical situation, preferences and capabilities of the medical institution, the choice of anaesthesia is usually determined collectively by a group of specialists (anaesthesiologist, surgeon, neurologist, cardiologist) and agreed with the patient.<sup>106,107</sup>

The share of RA in the overall structure of pain management during CEA ranges from 6 to 74%, in some clinics reaching 99% - such a wide range is largely explained by the preferences of clinics and their technical equipment.<sup>108-110</sup>

The studies carried out still have not given a clear answer to the question - which of the above methods has undeniable advantages.<sup>70-74,111</sup>

The main advantages of GA are immobility of the patient, decreased metabolism of brain cells and its protection during ischemia, adequate control of airway patency, external respiratory function and carbon dioxide concentration, reduced reaction to operational stress.<sup>74,76,112,113</sup> The main disadvantage of GA is the inability to control the patient's neurological

status during surgery, which explains the later (only after the end of anaesthesia) detection of neurological deficits and complications.<sup>73</sup> Other disadvantages of GA include hemodynamic instability (intraoperative hypotension or sharp fluctuations in blood pressure; postoperative hypertension), and a higher frequency of use of a temporary intraluminal shunt.<sup>76</sup>

RA does not have many of the problems associated with general anaesthesia.<sup>114,115</sup>

The main advantage of RA is the possibility of constant monitoring of the patient's neurological status throughout the operation and in the early postoperative period, clinical assessment of his cognitive, verbal and motor functions, i.e. so-called dynamic neurological monitoring.<sup>116</sup> In 2016, Lee J. et al. published their experience, operating under RA, 5 minutes before clamping the ICA, the so-called "awake test" was performed, including assessment of the patient's speech, squeezing a rubber ball with the contralateral hand and movement of the big toe of the contralateral foot; the test was repeated immediately after clamping the ICA and then at intervals of 5 minutes throughout the entire cross-clamping period.<sup>117</sup> Dynamic neuromonitoring makes it possible to assess the preservation of higher cortical functions and the adequacy of collateral blood flow during clamping of the ICA, and in the event of the appearance of neurological symptoms, it provides rapid detection of cerebral ischemia.<sup>64,116</sup>

Another important advantage of RA, according to some authors, is the reduction in the frequency of using a temporary internal shunt (TIS), the use of which can be accompanied by cerebral ischemia in approximately 5% of cases. The main causes of ischemic complications are damage to the intimal ICA by the shunt, dissection of the ICA, embolism with fragments of atherosclerotic plaque, thromboembolism, air embolism, shunt occlusion, and the use of a TIS itself can act as a cause of ICA thrombosis in the early postoperative period and lead to late arterial restenosis.<sup>73,118</sup>

*AbuRahma A. F. et al.*, summarizing and analyzing the literature in PubMed and Medline until 2010, calculated that the routine use of TIS during CEA is accompanied by a lower incidence of perioperative stroke (1.4%) than when not using it during surgery (2%).<sup>64,119</sup> *Bellosta R. et al.* (2006) during operations on the ICA using an internal shunt in 99.4% of cases noted a complication rate of less than 2%.<sup>120</sup> *Lobo M. et al.* found that the internal shunt was used significantly less frequently in the group of patients with RA (n=540, TIS in 3%, p<0.05) compared to the cohort of patients operated on for GA (n=197, TIS in 14%).<sup>109</sup> The frequency of use of TIS during operations under RA is much lower and ranges from 2.4 to 13%.<sup>119,121-123</sup> Other authors, during

operations under GA, recommend installing TIS when the retrograde mean pressure in the ICA is below 40 mmHg.<sup>124</sup>

During operations under RA, the main indication for shunt installation is the appearance of clinical signs of cerebral ischemia.<sup>116,125</sup> However, patients who develop negative neurological symptoms requiring TIS placement have an increased risk of perioperative stroke and death.<sup>124</sup>

Among the disadvantages of RA, a number of authors point out: lack of brain protection during ICA clamping, lack of reliable control over airway patency, external respiratory function and carbon dioxide concentration, the possibility of developing perioperative arterial hypertension, a higher level of operational stress, as well as the forced position of the patient during surgery.<sup>76,112</sup>

Indications for RA are: the presence of an embologenic plaque in the operated ICA, the absence of an ultrasound window for performing Transcranial Doppler Ultrasound, severe damage to the coronary bed, severe stenosis of the aortic and mitral valves, low left ventricular ejection fraction, cardiac rhythm and conduction disturbances, diseases of the respiratory system, patient refusal of general anaesthesia.<sup>126</sup> In addition, according to *Kavakli A. S. et al.*, they believe that RA is most indicated in patients with critical contralateral ICA stenosis, when it is especially important to assess the need to install an internal shunt. In 2016, the results of a study were published in which the degree of contralateral ICA stenosis in patients operated under RA and intolerant to ICA clamping, the average degree of artery stenosis was 57.5%. Among patients tolerant to ICA clamping, the degree of contralateral stenosis was on average 27.8%.<sup>107,121</sup>

Contraindications to RA during operations on the carotid arteries are impossibility of verbal contact with the patient, patient inadequacy, contralateral paresis of the phrenic or recurrent nerve, blood coagulation disorders, and patient refusal of RA.<sup>127</sup> *Lee J. et al.* indicate that a high location of carotid artery stenosis (level of the second cervical vertebra) is also a contraindication to RA.<sup>117,118</sup>

According to *Brown D.L.* (2009), bilateral cervical plexus blocks should be avoided, as there is a risk of blocking both phrenic nerves.<sup>59</sup>

It is now generally accepted that in clinical practice it is optimal to use multimodal neuromonitoring (for example, TDU (Transcranial Doppler Ultrasound) + CO (cerebral oximetry) + EEG), which reduces the disadvantages of each method.<sup>125,128</sup> *Kolkert J. L. P. et al.* in 2017 noted that the addition of neuromonitoring modalities increases the cost of anaesthesia and, therefore, average hospital costs. In the isolated group, measurements of retrograde pressure in the ICA

and in the TDU + EEG group increased almost 2 times.<sup>124,126</sup>

There are conflicting opinions regarding the need for drug sedation of patients during CEA under RA. According to *Lawrence P. F.*, drug sedation should not be used or used minimally when the patient is restless and agitated, since there is a need for constant monitoring of the patient's neurological status during surgery under RA.<sup>115</sup>

Currently, modern medicine has a limited range of drugs that in clinical practice can prevent ischemic and reperfusion complications. When choosing drugs for neuroprotection, it would be desirable to use mechanisms that not only reduce the intensity of metabolic processes

in the brain, but also correct cellular neuronal hypoxia.<sup>129</sup>

### Conclusion

Cranio-cerebral hypothermia, despite its long-term study, is currently not widely used. Indications for the use of an internal shunt have been worked out. Provisions on the choice of anaesthesia have been formulated. The effect of various drugs in cerebral ischemia has been studied. Obviously, there remains a huge direction in the surgery of the carotid arteries, namely pathological tortuosity, in which the use of an internal shunt is not possible, which determines the development of pharmacological protection of the brain.

### References

1. Pokrovskij A. Klassicheskaja karotidnaja jendarterektomija. *Angiologija i sosudistaja hirurgija*. 2001;7(1):101-104.
2. DE BAKEY ME, CRAWFORD ES, COOLEY DA, MORRIS GC. Surgical considerations of occlusive disease of innominate, carotid, subclavian, and vertebral arteries. *Ann Surg*. May 1959;149(5):690-710. doi:10.1097/00000658-195905000-00010
3. DeBakey ME. Successful carotid endarterectomy for cerebrovascular insufficiency. Nineteen-year follow-up. *JAMA*. Sep 08 1975;233(10):1083-5.
4. EASTCOTT HH, PICKERING GW, ROB CG. Reconstruction of internal carotid artery in a patient with intermittent attacks of hemiplegia. *Lancet*. Nov 13 1954;267(6846):994-6. doi:10.1016/S0140-6736(54)90544-9
5. Barnett HJM, Taylor DW, Haynes RB, et al. Beneficial effect of carotid endarterectomy in symptomatic patients with high-grade carotid stenosis. *N Engl J Med*. Aug 15 1991;325(7):445-53. doi:10.1056/NEJM199108153250701
6. Barnett HJ, Taylor DW, Eliasziw M, et al. Benefit of carotid endarterectomy in patients with symptomatic moderate or severe stenosis. North American Symptomatic Carotid Endarterectomy Trial Collaborators. *N Engl J Med*. Nov 12 1998;339(20):1415-25. doi:10.1056/NEJM199811123392002
7. Endarterectomy for asymptomatic carotid artery stenosis. Executive Committee for the Asymptomatic Carotid Atherosclerosis Study. *JAMA*. May 10 1995;273(18):1421-8.
8. Halliday A, Mansfield A, Marro J, et al. Prevention of disabling and fatal strokes by successful carotid endarterectomy in patients without recent neurological symptoms: randomised controlled trial. *Lancet*. May 08 2004;363(9420):1491-502. doi:10.1016/S0140-6736(04)16146-1
9. Dalley AF. Thomas Willis 1621-1675. *Clin Anat*. Jan 2002;15(1):2-3. doi:10.1002/ca.1083
10. Matas R. I. Testing the Efficiency of the Collateral Circulation as a Preliminary to the Occlusion of the Great Surgical Arteries. *Ann Surg*. Jan 1911;53(1):1-43. doi:10.1097/00000658-191101000-00001
11. Zingerman L. Angiograficheskaja simptomatika i nekotorye mehanizmy kompensacii okkluzionnyh porazhenij grudnoj aorty i ee vetvej: Avtoref. diss.... d-ra med. nauk. M; 1969.
12. Zingerman L, Glosovskaja M, Rabotnikov V. Okkluzionnye porazhenija vetvej dugi aorty po dannym klinicheskogo, angiograficheskogo i morfologicheskogo issledovanija. *Grudnaja hirurgija*. 1968;(2):24-29.
13. Moulakakis KG, Mylonas SN, Sfyroeras GS, Andrikopoulos V. Hyperperfusion syndrome after carotid revascularization. *J Vasc Surg*. Apr 2009;49(4):1060-8. doi:10.1016/j.jvs.2008.11.026
14. Krotenkova MV. Diagnostika ostrogo insul'ta: nejrovizualizacionnye algoritmy. Gosudarstvennoe uchrezhdenie Nauchnyj centr neurologii; 2011.
15. Bivard A, Levi C, Spratt N, Parsons M. Perfusion CT in acute stroke: a comprehensive analysis of infarct and penumbra. *Radiology*. May 2013;267(2):543-50. doi:10.1148/radiol.12120971
16. Sergeeva A, Konovalov R, Sergeev D, et al. Cerebral perfusion changes in patients with internal carotid artery stenoses after surgical revascularization. *Human Physiology*. 2016;42:891-897.
17. Bobrikova E, Shherban' N, Haneev V, et al. Ocenka sostojanija ateroskleroticheskijh bljashek brahiocefal'nyh arterij sredstvami vysokorazreshajushhej kontrastirovannoj MRT: vzaimosvjaz' s ishemicheskim povrezhdeniem golovnogogo mozga. *Medicinskaja vizualizacija*. 2013;(1):26-32.
18. Bobrikova E. Kontrastirovannaja MR-tomografija ateroskleroticheskijh bljashek brahiocefal'nyh arterij v ocenke riska ishemicheskijh povrezhdenij golovnogogo mozga. *Rossijskij jelektronnyj zhurnal luchevoj diagnostiki*. 2013;3(3):76-84.
19. Strazden' E, Sharija M, Tararak Je, Ustjuzhanin D, Radjuhina N. Ocenka struktury ateroskleroticheskijh bljashki metodom magnitno-rezonansnoj tomografii s cel'ju



- opredelenija ee stabil'nosti. Regionarnoe krovoobrashhenie i mikrocirkuljacija. 2013;12(1):31-35.
20. Wardlaw JM, Smith EE, Biessels GJ, et al. Neuroimaging standards for research into small vessel disease and its contribution to ageing and neurodegeneration. *Lancet Neurol.* Aug 2013;12(8):822-38. doi:10.1016/S1474-4422(13)70124-8
  21. Naylor AR, Ricco JB. Response to «Re: Management of Atherosclerotic Carotid and Vertebral Artery Disease: 2017 Clinical Practice Guidelines of the European Society for Vascular Surgery (ESVS)». *Eur J Vasc Endovasc Surg.* Jun 2018;55(6):902. doi:10.1016/j.ejvs.2018.03.023
  22. Meshalkin E, Vereshhagin I. Okkluzii v uslovijah neclubokoj gipotermicheskoj zashhity. 1985;
  23. Petrovskij B, Chazov E, Andreev S. Aktual'nye problemy gemostaziologii. *MiNauka*, 1979-198 s. 1981;
  24. Plam F, Pozner DB. Diagnostika stupora i komy. *M: Medicina.* 1986:79.
  25. Hochachka P, Lashkevich Jul. Strategija biohimicheskoj adaptacii: per. s angl. *Mir*; 1977.
  26. Labori G. Metabolicheskie i farmakologicheskie osnovy nefrofiziologii. *M: Medicina.* 1974;15
  27. Gruzman A, Hapij H. Uglevodnyj obmen v golovnom mozge pri komatoznyh sostojanijah. *Mehanizmy glikoneogeneza. Mehanizmy glikoneogeneza Anest i reanimatol.* 1991;3:17-21.
  28. Gusev EI, Skvorcova VI. Ishemija golovnog mozga. *Medicina*; 2001.
  29. Brouns R, De Deyn PP. The complexity of neurobiological processes in acute ischemic stroke. *Clin Neurol Neurosurg.* Jul 2009;111(6):483-95. doi:10.1016/j.clineuro.2009.04.001
  30. Zivin JA. Factors determining the therapeutic window for stroke. *Neurology.* Mar 1998;50(3):599-603. doi:10.1212/wnl.50.3.599
  31. Hossmann KA. Viability thresholds and the penumbra of focal ischemia. *Ann Neurol.* Oct 1994;36(4):557-65. doi:10.1002/ana.410360404
  32. Obrenovitch TP. The ischaemic penumbra: twenty years on. *Cerebrovasc Brain Metab Rev.* 1995;7(4):297-323.
  33. Astrup J, Siesjö BK, Symon L. Thresholds in cerebral ischemia - the ischemic penumbra. *Stroke.* 1981;12(6):723-5. doi:10.1161/01.str.12.6.723
  34. Furlan M, Marchal G, Viader F, Derlon JM, Baron JC. Spontaneous neurological recovery after stroke and the fate of the ischemic penumbra. *Ann Neurol.* Aug 1996;40(2):216-26. doi:10.1002/ana.410400213
  35. Fisher M, Garcia JH. Evolving stroke and the ischemic penumbra. *Neurology.* Oct 1996;47(4):884-8. doi:10.1212/wnl.47.4.884
  36. Moskowitz MA, Lo EH, Iadecola C. The science of stroke: mechanisms in search of treatments. *Neuron.* Jul 29 2010;67(2):181-98. doi:10.1016/j.neuron.2010.07.002
  37. Brainin M, Heiss W-D. Textbook of stroke medicine. *Cambridge University Press*; 2019.
  38. Fedin A. Sovremennaja koncepcija patogeneza i lechenija ostroj ishemii mozga. 2001:5-23.
  39. Guyton AC. Text book of medical physiology. *China*; 2006.
  40. Grozovskij Ju, Sultanov D, Stranin V, et al. Regionarnyj mozgovoj krovotok u bol'nyh s odnostoronnim porazheniem bifurkacii sonnoj arterii. *Hirurgija.* 1985;5:54-59.
  41. Dirden N. Ispol'zovanie monitoringa saturacii kisloroda v lukovice jaremnoj veny. Aktual'nye problemy anesteziologii i reanimatologii Osvezhajushhij kurs lekcij. 1997:154-159.
  42. Litasova E, Lomivorotov V, Postnov V. Besperfuzionnaja uglublennaja gipotermicheskoj zashhity. *Novosibirsk: Nauka*; 1988.
  43. Karas'kov A. Gipotermija v hirurgii otkrytogo serdca. *Novosibirsk*; 1999.
  44. Bunjatjan A, Seleznev M, Sablin I, Pozharnov A. Anestezija i zashhity mozga pri rekonstruktivnyh operacijah na brahiocefal'nyh arterijah. *Anesteziologija i reanimatologija.* 1993;(3):3-6.
  45. Croughwell N, Smith LR, Quill T, et al. The effect of temperature on cerebral metabolism and blood flow in adults during cardiopulmonary bypass. *J Thorac Cardiovasc Surg.* Mar 1992;103(3):549-54.
  46. Hartung J, Cottrell JE. Mild hypothermia and cerebral metabolism. *J Neurosurg Anesthesiol.* Jan 1994;6(1):1-3.
  47. van der Linden J. Cerebral hemodynamics after low-flow versus no-flow procedures. *Ann Thorac Surg.* May 1995;59(5):1321-5. doi:10.1016/0003-4975(95)00173-i
  48. Ginsberg MD, Sternau LL, Globus MY, Dietrich WD, Busto R. Therapeutic modulation of brain temperature: relevance to ischemic brain injury. *Cerebrovasc Brain Metab Rev.* 1992;4(3):189-225.
  49. Wass CT, Lanier WL. Hypothermia-associated protection from ischemic brain injury: implications for patient management. *Int Anesthesiol Clin.* 1996;34(4):95-111. doi:10.1097/00004311-199603440-00008
  50. Dietrich WD, Busto R, Alonso O, Globus MY, Ginsberg MD. Intraischemic but not postischemic brain hypothermia protects chronically following global forebrain ischemia in rats. *J Cereb Blood Flow Metab.* Jul 1993;13(4):541-9. doi:10.1038/jcbfm.1993.71
  51. Derjagin MN. Kraniocerebral'naja gipotermija v hirurgii sonnyh arterij. *Diss kand med nauk, Novosibirsk.* 2004;
  52. Kazanchjan P, Skrylev S, Matjushov Ju, Rudakova T. Hirurgicheskoe lechenie okkluzirujushhij porazhenij podkljuchichnyh arterij. *Hirurgija.* 1994;(7):8.
  53. Werz MA, Macdonald RL. Barbiturates decrease voltage-dependent calcium conductance of mouse neurons in dissociated cell culture. *Mol Pharmacol.* Sep 1985;28(3):269-77.
  54. Svetlova NJu. Sravnitel'naja harakteristika metodov zashhity mozga pri hirurgicheskoj korrekcii patologii koronarnykh arterij. [NC serdech.-sosudistoj hirurgii im. AN Bakuleva RAMN] M.; 2004.
  55. Sandmann W, Kolvenbach R, Willeke F. Risks and

- benefits of shunting in carotid endarterectomy. *Stroke*. 1993;24(7):1098-1099.
56. Gumerlock MK, Neuwelt EA. Carotid endarterectomy: to shunt or not to shunt. *Stroke*. Dec 1988;19(12):1485-90. doi:10.1161/01.str.19.12.1485
  57. Beeching NJ, Fletcher TE, Beadsworth MJB. Covid-19: testing times. *BMJ*. Apr 08 2020;369:m1403. doi:10.1136/bmj.m1403
  58. Bond R, Rerkasem K, Naylor AR, Aburahma AF, Rothwell PM. Systematic review of randomized controlled trials of patch angioplasty versus primary closure and different types of patch materials during carotid endarterectomy. *J Vasc Surg*. Dec 2004;40(6):1126-35. doi:10.1016/j.jvs.2004.08.048
  59. Tan TW, Garcia-Toca M, Marcaccio EJ, Carney WI, Machan JT, Slaiby JM. Predictors of shunt during carotid endarterectomy with routine electroencephalography monitoring. *J Vasc Surg*. Jun 2009;49(6):1374-8. doi:10.1016/j.jvs.2009.02.206
  60. Bond R, Warlow C, Naylor A, Rothwell P. Variation in surgical and anaesthetic technique and associations with operative risk in the European carotid surgery trial: implications for trials of ancillary techniques. *European journal of vascular and endovascular surgery*. 2002;23(2):117-126.
  61. Lubnin A, Shmigel'skij A, Ostrovskij A. Cerebral'nyj oksimetr INVOS-3100. *Anest i reanimatol*. 1995;(4):68.
  62. Karavaev B, Gavrilenko A, Zolicheva N, Skrylev M. Seljutin. Perioperacionnaja diagnostika cerebral'noj ishemii pri rekonstruktivnyh operacijah na sonnyh arterijah. *Anesteziologija i reanimatologija*. 1999;(5):71-71.
  63. Lebedeva R, Gavrilenko A, Karavaev B, Skrylev S. Intraoperacionnaja diagnostika cerebral'noj ishemii pri rekonstruktivnyh operacijah na sonnyh arterijah metodom transkranijskoj oksimetrii. *Angiologija i sosudistaja hirurgija*. 1999;5(4):41-46.
  64. Shmigel'skij A, Lubnin A, Sazonova O. Cerebral'naja oksimetrija u neirohirurgicheskix bol'nyh s sosudistoj patologiej golovnogogo mozga. *Anesteziologija i reanimatologija*. 2000;(4):19-24.
  65. Gavrilenko A, Karavaev B, Bondarenko A, Skrylev S, Zolicheva N, Voronov D. Cerebral'naja oksimetrija i karotidnaja jendarterektomija: kontrol' urovnja oksigenacii golovnogogo mozga v period operativnogo vmeshatel'stva i ocenka ego jeffektivnosti. *Angiol i sosud hir*. 2002;1:67-71.
  66. Bokerija LA, Pokrovskij AV, Sokurenko G, et al. Nacional'nye rekomendacii po vedeniju pacientov s zabolevanijami brahiocefal'nyh arterij. 2013;
  67. Kokófer A, Nawratil J, Opperer M. [Regional anesthesia for carotid surgery : An overview of anatomy, techniques and their clinical relevance]. *Anaesthesist*. Apr 2017;66(4):283-290. doi:10.1007/s00101-017-0270-z
  68. Kfoury E, Dort J, Trickey A, et al. Carotid endarterectomy under local and/or regional anesthesia has less risk of myocardial infarction compared to general anesthesia: An analysis of national surgical quality improvement program database. *Vascular*. Apr 2015;23(2):113-9. doi:10.1177/1708538114537489
  69. Youngberg JA. Pro: regional anesthesia is preferable to general anesthesia for carotid artery surgery. *J Cardiothorac Anesth*. Oct 1987;1(5):479-82. doi:10.1016/s0888-6296(87)97274-7
  70. Rich NM, Hobson RW. Carotid endarterectomy under regional anesthesia. *Am Surg*. Apr 1975;41(4):253-9.
  71. Hobson RW, Wright CB, Sublett JW, Fedde CW, Rich NM. Carotid artery back pressure and endarterectomy under regional anesthesia. *Arch Surg*. Nov 1974;109(5):682-7. doi:10.1001/archsurg.1974.01360050076017
  72. Cedergreen P, Swiatek F, Nielsen HB. Local anaesthesia for carotid endarterectomy: Pro: protect the brain. *Eur J Anaesthesiol*. Apr 2016;33(4):236-7. doi:10.1097/EJA.0000000000000370
  73. Licker M. Regional or general anaesthesia for carotid endarterectomy: Does it matter? *Eur J Anaesthesiol*. Apr 2016;33(4):241-3. doi:10.1097/EJA.0000000000000376
  74. Leichtle SW, Mouawad NJ, Welch K, Lampman R, Whitehouse WM, Heidenreich M. Outcomes of carotid endarterectomy under general and regional anesthesia from the American College of Surgeons' National Surgical Quality Improvement Program. *J Vasc Surg*. Jul 2012;56(1):81-8.e3. doi:10.1016/j.jvs.2012.01.005
  75. Unic-Stojanovic D, Babic S, Neskovic V. General versus regional anesthesia for carotid endarterectomy. *J Cardiothorac Vasc Anesth*. Dec 2013;27(6):1379-83. doi:10.1053/j.jvca.2012.09.021
  76. Guay J. Regional or general anesthesia for carotid endarterectomy? Evidence from published prospective and retrospective studies. *J Cardiothorac Vasc Anesth*. Feb 2007;21(1):127-32. doi:10.1053/j.jvca.2006.07.022
  77. Ciccozzi A, Angeletti C, Guetti C, et al. Regional anaesthesia techniques for carotid surgery: the state of art. *J Ultrasound*. Sep 2014;17(3):175-83. doi:10.1007/s40477-014-0094-5
  78. Ladak N, Thompson J. General or local anaesthesia for carotid endarterectomy? Continuing Education in Anaesthesia, Critical Care & Pain. 2012;12(2):92-96.
  79. Forssell C, Takolander R, Bergqvist D, Johansson A, Persson NH. Local versus general anaesthesia in carotid surgery. A prospective, randomised study. *Eur J Vasc Surg*. Dec 1989;3(6):503-9. doi:10.1016/s0950-821x(89)80124-0
  80. McCarthy RJ, Nasr MK, McAteer P, Horrocks M. Physiological advantages of cerebral blood flow during carotid endarterectomy under local anaesthesia. A randomised clinical trial. *Eur J Vasc Endovasc Surg*. Sep 2002;24(3):215-21. doi:10.1053/ejvs.2002.1715
  81. McCleary AJ, Maritati G, Gough MJ. Carotid endarterectomy; local or general anaesthesia? *Eur J Vasc Endovasc Surg*. Jul 2001;22(1):1-12.

- doi:10.1053/ejvs.2001.1382
82. Pluskwa F, Bonnet F, Abhay K, et al. BLOOD-PRESSURE PROFILES DURING CAROTID ENDARTERECTOMY - COMPARING FLUNITRAZEPAM FENTANYL NITROUS-OXIDE WITH EPIDURAL-ANESTHESIA. EDITIONS SCIENTIFIQUES ELSEVIER 141 RUE JAVEL, 75747 PARIS CEDEX 15, FRANCE; 1989:26-32.
  83. Sbarigia E, DarioVizza C, Antonini M, et al. Locoregional versus general anesthesia in carotid surgery: is there an impact on perioperative myocardial ischemia? Results of a prospective monocentric randomized trial. *J Vasc Surg.* Jul 1999;30(1):131-8. doi:10.1016/s0741-5214(99)70185-0
  84. Rerkasem K, Bond R, Rothwell PM. Local versus general anaesthesia for carotid endarterectomy. *Cochrane Database Syst Rev.* 2004;(2):CD000126. doi:10.1002/14651858.CD000126.pub2
  85. Gough MJ, Bodenham A, Horrocks M, et al. GALA: an international multicentre randomised trial comparing general anaesthesia versus local anaesthesia for carotid surgery. *Trials.* May 21 2008;9:28. doi:10.1186/1745-6215-9-28
  86. Naylor R, Rantner B, Ancetti S, et al. Editor's Choice - European Society for Vascular Surgery (ESVS) 2023 Clinical Practice Guidelines on the Management of Atherosclerotic Carotid and Vertebral Artery Disease. *Eur J Vasc Endovasc Surg.* Jan 2023;65(1):7-111. doi:10.1016/j.ejvs.2022.04.011
  87. Knappich C, Kuehnl A, Haller B, et al. Associations of Perioperative Variables With the 30-Day Risk of Stroke or Death in Carotid Endarterectomy for Symptomatic Carotid Stenosis. *Stroke.* Dec 2019;50(12):3439-3448. doi:10.1161/STROKEAHA.119.026320
  88. Orlický M, Hrbáč T, Sameš M, et al. Anesthesia type determines risk of cerebral infarction after carotid endarterectomy. *J Vasc Surg.* Jul 2019;70(1):138-147. doi:10.1016/j.jvs.2018.10.066
  89. Malik OS, Brovman EY, Urman RD. The Use of Regional or Local Anesthesia for Carotid Endarterectomies May Reduce Blood Loss and Pulmonary Complications. *J Cardiothorac Vasc Anesth.* Apr 2019;33(4):935-942. doi:10.1053/j.jvca.2018.08.195
  90. Pandit JJ, Satya-Krishna R, Gratton P. Superficial or deep cervical plexus block for carotid endarterectomy: a systematic review of complications. *Br J Anaesth.* Aug 2007;99(2):159-69. doi:10.1093/bja/aem160
  91. Grieff AN, Dombrovskiy V, Beckerman W, et al. Anesthesia Type is Associated with Decreased Cranial Nerve Injury in Carotid Endarterectomy. *Ann Vasc Surg.* Jan 2021;70:318-325. doi:10.1016/j.avsg.2019.12.033
  92. Harky A, Chan JSK, Kot TKM, et al. General Anesthesia Versus Local Anesthesia in Carotid Endarterectomy: A Systematic Review and Meta-Analysis. *J Cardiothorac Vasc Anesth.* Jan 2020;34(1):219-234. doi:10.1053/j.jvca.2019.03.029
  93. Hajibandeh S, Antoniou SA, Torella F, Antoniou GA. Meta-analysis and trial sequential analysis of local vs. general anaesthesia for carotid endarterectomy. *Anaesthesia.* Oct 2018;73(10):1280-1289. doi:10.1111/anae.14320
  94. Eckstein H, Kühnl A, Berkefeld J, et al. S3-Leitlinie zur Diagnostik, Therapie und Nachsorge der extracraniellen Carotisstenose. *Gefässchirurgie.* 2012;17(6):495-496.
  95. AbuRahma AF, Avgerinos ED, Chang RW, et al. Society for Vascular Surgery clinical practice guidelines for management of extracranial cerebrovascular disease. *Journal of vascular surgery.* 2022;75(1):4S-22S.
  96. Kenyon JR, Thomas AB, Goodwin DP. Heparin protection for the brain during carotid-artery reconstruction. *Lancet.* Jul 22 1972;2(7769):153-4. doi:10.1016/s0140-6736(72)91327-x
  97. Sano T, Drummond JC, Patel PM, Grafe MR, Watson JC, Cole DJ. A comparison of the cerebral protective effects of isoflurane and mild hypothermia in a model of incomplete forebrain ischemia in the rat. *Anesthesiology.* Feb 1992;76(2):221-8. doi:10.1097/0000542-199202000-00011
  98. Scheller MS, Nakakimura K, Fleischer JE, Zornow MH. Cerebral effects of sevoflurane in the dog: comparison with isoflurane and enflurane. *Br J Anaesth.* Sep 1990;65(3):388-92. doi:10.1093/bja/65.3.388
  99. Vandesteene A, Trempont V, Engelman E, et al. Effect of propofol on cerebral blood flow and metabolism in man. *Anaesthesia.* Mar 1988;43 Suppl:42-3. doi:10.1111/j.1365-2044.1988.tb09067.x
  100. Werner C, Kochs E, Bause H, Hoffman WE, Schulte am Esch J. Effects of sufentanil on cerebral hemodynamics and intracranial pressure in patients with brain injury. *Anesthesiology.* Oct 1995;83(4):721-6. doi:10.1097/0000542-199510000-00011
  101. Wilhelm W, Schlaich N, Harrer J, Kleinschmidt S, Müller M, Larsen R. Recovery and neurological examination after remifentanil-desflurane or fentanyl-desflurane anaesthesia for carotid artery surgery. *Br J Anaesth.* Jan 2001;86(1):44-9. doi:10.1093/bja/86.1.44
  102. BAKAY L, SWEET WH. Cervical and intracranial intra-arterial pressures with and without vascular occlusion. *Surg Gynecol Obstet.* Jul 1952;95(1):67-75.
  103. BAKAY L, SWEET WH. Intra-arterial pressures in the neck and brain; late changes after carotid closure, acute measurements after vertebral closure. *J Neurosurg.* Jul 1953;10(4):353-9. doi:10.3171/jns.1953.10.4.0353
  104. Bujanovskij V. Diagnostika i hirurgicheskoe lechenie okkluzirujushih porazhenij brahiocefal'nyh sosudov. M; 1992.
  105. Chou EL, Sgroi MD, Chen SL, Kuo IJ, Kabutey NK, Fujitani RM. Influence of gender and use of regional anesthesia on carotid endarterectomy outcomes. *J Vasc Surg.* Jul 2016;64(1):9-14. doi:10.1016/j.jvs.2016.03.406
  106. Kraňnik VM, Kozlov SP, Deshko IV, Gavrilenko AV, Kuklin AV. [Combined anaesthesia in

- reconstructive operations on carotid arteries]. *Angiol Sosud Khir.* 2014;20(2):111-7.
107. Kavaklı AS, Ayoğlu RU, Öztürk NK, et al. Simultaneous Bilateral Carotid Endarterectomy under Cervical Plexus Blockade. *Turk J Anaesthesiol Reanim.* Oct 2015;43(5):367-70. doi:10.5152/TJAR.2015.87369
108. Gabriel RA, Lemay A, Beutler SS, Dutton RP, Urman RD. Practice Variations in Anesthesia for Carotid Endarterectomies and Associated Outcomes. *J Cardiothorac Vasc Anesth.* Jan 2016;30(1):23-9. doi:10.1053/j.jvca.2015.06.014
109. Liu J, Martinez-Wilson H, Neuman MD, Elkassabany N, Ochroch EA. Outcome of Carotid Endarterectomy after Regional Anesthesia versus General Anesthesia - A Retrospective Study Using Two Independent Databases. *Transl Perioper Pain Med.* 2014;1(2):14-21.
110. Hussain AS, Mullard A, Oppat WF, Nolan KD. Increased resource utilization and overall morbidity are associated with general versus regional anesthesia for carotid endarterectomy in data collected by the Michigan Surgical Quality Collaborative. *J Vasc Surg.* Sep 2017;66(3):802-809. doi:10.1016/j.jvs.2017.01.060
111. Lobo M, Mourão J, Afonso G. Carotid endarterectomy: review of 10 years of practice of general and locoregional anesthesia in a tertiary care hospital in Portugal. *Braz J Anesthesiol.* 2015;65(4):249-54. doi:10.1016/j.bjane.2014.03.011
112. Pasin L, Nardelli P, Landoni G, et al. Examination of regional anesthesia for carotid endarterectomy. *J Vasc Surg.* Sep 2015;62(3):631-4.e1. doi:10.1016/j.jvs.2015.03.074
113. Dudanov IP, Sokurenko G, Erofeev A, Kitachjov K, Jurchenko D, Hubulava G. Hirurgicheskoe lechenie stenozov sonnyh arterij. *Medicinskij akademicheskij zhurnal.* 2010;10(3):37-44.
114. McCulloch TJ, Thompson CL, Turner MJ. A randomized crossover comparison of the effects of propofol and sevoflurane on cerebral hemodynamics during carotid endarterectomy. *Anesthesiology.* Jan 2007;106(1):56-64. doi:10.1097/00000542-200701000-00012
115. Lawrence PF, Alves JC, Jicha D, Bhirangi K, Dobrin PB. Incidence, timing, and causes of cerebral ischemia during carotid endarterectomy with regional anesthesia. *J Vasc Surg.* Feb 1998;27(2):329-34; discussion 335-7. doi:10.1016/s0741-5214(98)70363-5
116. Hoefler J, Pierer E, Rantner B, et al. Ultrasound-guided regional anesthesia for carotid endarterectomy induces early hemodynamic and stress hormone changes. *J Vasc Surg.* Jul 2015;62(1):57-67. doi:10.1016/j.jvs.2015.02.036
117. Gassner M, Bauman Z, Parish S, Koenig C, Martin J, Hans S. Hemodynamic changes in patients undergoing carotid endarterectomy under cervical block and general anesthesia. *Ann Vasc Surg.* Oct 2014;28(7):1680-5. doi:10.1016/j.avsg.2014.03.029
118. Lee J, Huh U, Song S, Chung SW, Sung SM, Cho HJ. Regional Anesthesia with Dexmedetomidine Infusion: A Feasible Method for the Awake Test during Carotid Endarterectomy. *Ann Vasc Dis.* 2016;9(4):295-299. doi:10.3400/avd.oa.16-00049
119. Aburahma AF, Mousa AY, Stone PA. Shunting during carotid endarterectomy. *J Vasc Surg.* Nov 2011;54(5):1502-10. doi:10.1016/j.jvs.2011.06.020
120. WC K. Indications, surgical technique, and results for repair of extracranial occlusive lesions. *Vascular surgery.* 2005:1974-2006.
121. Bellosta R, Luzzani L, Carugati C, Talarico M, Sarcina A. Routine shunting is a safe and reliable method of cerebral protection during carotid endarterectomy. *Ann Vasc Surg.* Jul 2006;20(4):482-7. doi:10.1007/s10016-006-9037-8
122. Dellaretti M, de Vasconcelos LT, Dourado J, de Souza RF, Fontoura RR, de Sousa AA. Locoregional Anesthesia for Carotid Endarterectomy: Identification of Patients with Intolerance to Cross-Clamping. *World Neurosurg.* Mar 2016;87:61-4. doi:10.1016/j.wneu.2015.11.097
123. Leblanc I, Chterev V, Rezik M, et al. Safety and efficiency of ultrasound-guided intermediate cervical plexus block for carotid surgery. *Anaesth Crit Care Pain Med.* Apr 2016;35(2):109-14. doi:10.1016/j.accprm.2015.08.004
124. Mendonça CT, Fortunato JA, Carvalho CA, et al. Carotid endarterectomy in awake patients: safety, tolerability and results. *Rev Bras Cir Cardiovasc.* 2014;29(4):574-80. doi:10.5935/1678-9741.20140053
125. Shmigel'skii AV, Lubnin Alu. [Anesthesia during carotid endarterectomy]. *Anesteziol Reanimatol.* 2008;(2):47-57.
126. Kolkert JLP, Groenwold RHH, Leijdekkers VJ, Ter Haar J, Zeebregts CJ, Vahl A. Cost-Effectiveness of Two Decision Strategies for Shunt Use During Carotid Endarterectomy. *World J Surg.* Nov 2017;41(11):2959-2967. doi:10.1007/s00268-017-4085-5
127. Vaniyapong T, Chongruksut W, Rerkasem K. Local versus general anaesthesia for carotid endarterectomy. *Cochrane Database Syst Rev.* Dec 19 2013;(12):CD000126. doi:10.1002/14651858.CD000126.pub4
128. Majer G. *Perifericheskaja regionarnaja anesteziya.* 2010;
129. Braun D. *Atlas regionarnoj anestezi.* 2009;

# PROSPECTS FOR THE USE OF PCR IN THE DETECTION OF HEPATITIS (A LITERATURE REVIEW)

A.T. Aubakirova, L.E. Rizabecova, G.B. Abdilova

«Syzganov National Scientific Center of Surgery» JSC, the Republic of  
Kazakhstan;

## Abstract

**Relevance:** According to official WHO data, currently, about 325 million people in the world live with chronic hepatitis B and C, which makes hepatitis one of the most common infectious diseases in the world. There are many scientific studies aimed at a deeper understanding of hepatitis and the development of new methods of treatment and diagnosis. With the help of polymerase chain reaction, more sensitive tests for diagnosing hepatitis have been developed, allowing faster infection detection and treatment initiation. The PCR method for diagnosing hepatitis is justified and relevant, as it is one of the most effective and modern methods for detecting viral infection, which allows you to start treatment earlier and prevent the development of complications.

The study aimed to evaluate the PCR method's efficiency in diagnosing hepatitis.

**Methods:** In this review, the causes of hepatitis were investigated, and a comparative assessment of the effectiveness of various laboratory methods for diagnosing hepatitis, including enzyme immunoassay and polymerase chain reaction, was conducted. The analysis of scientific publications revealed the factors associated with the development of hepatitis and compared the effectiveness of ELISA, used for serological analysis of antibodies to hepatitis viruses, with PCR, designed to detect DNA or RNA of hepatitis viruses. The obtained results provide important information for improving the methods of diagnosis of hepatitis and more effective control of this serious infectious pathology.

**Results:** The analyzed scientific literature has shown that PCR diagnostics has several advantages over other methods of hepatitis diagnosis, such as ELISA, including higher sensitivity and specificity, the ability to detect hidden infections, and faster results. In addition, PCR diagnostics can be used to determine a specific strain of the virus, making it possible to take measures to treat and control infection. All these advantages confirm the scientific validity of using the PCR method in detecting hepatitis.

**Conclusion:** According to global statistics, PCR has a higher sensitivity and specificity in diagnosing hepatitis than ELISA. PCR can also be used to monitor the effectiveness of hepatitis treatment and determine viral load to make decisions about the need for treatment and evaluate its effectiveness.

<https://doi.org/10.35805/BSK2023IV003>

A.T. Aubakirova  
<https://orcid.org/0000-0001-7585-2898>  
L.E. Rizabecova  
<https://orcid.org/0000-0002-5921-7269>  
G.B. Abdilova  
<https://orcid.org/0000-0002-758-7587-412X>

## For correspondence:

Aubakirova A. T. - specialist of CDL  
JSC «Syzganov National Scientific  
Center of Surgery», Almaty,  
Kazakhstan, tel. +77019513192,  
e-mail: a.t.aubakirova1978@gmail.  
com

## Conflict of interest:

The authors declare that they  
have no conflicts of interest

## Keywords:

hepatitis, enzyme immunoassay,  
polymerase chain reaction,  
sensitivity, detection, DNA, RNA.

## Гепатитті анықтаудағы ПТР қолдану перспективалары (әдебиетке шолу)

A.T. Аубакирова, Л.Е. Ризабекова, Г.Б. Абдилова

«А. Н. Сызғанов атындағы Ұлттық хирургия ғылыми орталығы» АҚ,  
Алматы, Қазақстан Республикасы.

## Түйіндеме

**Өзектілігі:** ДДҰ-ның ресми мәліметтеріне сәйкес, қазіргі уақытта әлемде шамамен 325 миллион адам созылмалы В және С гепатитімен өмір сүреді, бұл гепатиттерді әлемдегі ең көп таралған жұқпалы аурулардың біріне айналдырады. Гепатитті тереңірек түсінуге және жаңа емдеу мен диагностиканы дамытуға бағытталған көптеген ғылыми зерттеулер бар. Полимеразды тізбекті реакцияның көмегімен гепатитті диагностикалау үшін сезімтал сынақтар жасалды, бұл инфекцияны тезірек анықтауға және емдеуді бастауға мүмкіндік береді. Гепатитті диагностикалауға арналған ПТР әдісі негізделген және өзекті, өйткені ол вирустық инфекцияны анықтаудың ең тиімді және заманауи әдістерінің бірі болып табылады, бұл емдеуді ертерек бастауға және асқынулардың дамуын болдырмауға мүмкіндік береді.

Зерттеудің мақсаты – гепатитті диагностикалау үшін ПТР әдісінің мәндерін бағалау.

Әдістер: Бұл шолуда гепатиттің себептері зерттелді және гепатиттерді диагностикалаудың

## Хат алысатын автор:

Әубәкірова А. Т. - "А. Н.  
Сызғанов атындағы Ұлттық  
хирургия ғылыми орталығы"  
АҚ ҚДЛ маманы., Алматы,  
Қазақстан, Тел. ++77019513192,  
электрондық пошта:  
a.t.aubakirova1978@gmail.com

## Мүдделер қақтығысы:

Авторлар мүдделер  
қақтығысының жоқтығын  
мәлімдейді

## Түйінді сөздер:

гепатиттер, иммуноферменттік  
талдау, полимеразды тізбекті  
реакция, сезімталдық, анықтау,  
ДНК, РНК.

әртүрлі зертханалық әдістерінің, соның ішінде иммуноферменттік талдау мен полимеразды тізбекті реакцияның тиімділігін салыстырмалы бағалау жүргізілді. Ғылыми жарияланымдарды талдау әдістері гепатиттің дамуына байланысты факторларды анықтауға және гепатит вирусының антиденелерін серологиялық талдау үшін қолданылатын ИФА тиімділігін гепатит вирустарының ДНҚ немесе РНҚ-сын анықтауға арналған ПТР-мен салыстыруға мүмкіндік берді. Нәтижелер гепатитті диагностикалау әдістерін жақсарту және осы ауыр инфекциялық патологияны тиімдірек бақылау үшін маңызды ақпарат береді.

**Нәтижелер:** Талданған ғылыми әдебиеттер ПТР диагностикасының ИФА сияқты гепатитті диагностикалаудың басқа әдістеріне қарағанда бірқатар артықшылықтары бар екенін көрсетті, соның ішінде жоғары сезімталдық пен ерекшелік, жасырын инфекцияларды анықтау мүмкіндігі және жылдам нәтиже. Сонымен қатар, ПТР диагностикасын вирустың белгілі бір штаммын анықтау үшін қолдануға болады, бұл инфекцияны емдеу және бақылау шараларын қабылдауға мүмкіндік береді. Осы артықшылықтардың барлығы гепатиттерді анықтау кезінде ПТР әдісін қолданудың ғылыми негізділігін растайды.

**Қорытынды:** Әлемдік статистика бойынша гепатиттердің ПТР диагностикасы ИФА диагностикасына қарағанда әдістің жоғары сезімталдығы мен ерекшелігін көрсетті. ПТР гепатитті емдеудің тиімділігін бақылау және вирустық жүктемені анықтау үшін қосымша қолданылуы мүмкін, бұл емдеу қажеттілігі туралы шешім қабылдауға және оның тиімділігін бағалауға көмектеседі.

## Перспективы использования ПЦР в выявлении гепатитов: обзор литературы

Автор для корреспонденции:  
Аубакирова А.Т. - специалист  
ҚДЛ АО "Национальный  
научный центр хирургии им. А.Н.  
Сызганова", Алматы, Казахстан,  
тел. ++77019513192, email:  
a.t.aubakirova1978@gmail.com

А.Т. Аубакирова, Л.Е. Ризабекова, Г.Б. Абдилова

АО «Национальный научный центр хирургии имени А.Н. Сызганова»,  
Республика Казахстан.

### Аннотация

**Актуальность:** Согласно официальным данным ВОЗ, в настоящее время около 325 миллионов человека в мире живут с хроническим гепатитом В и С, что делает гепатиты одной из наиболее распространённых инфекционных болезней в мире. Существует множество научных исследований, направленных на более глубокое понимание гепатитов и разработку новых методов лечения и диагностики. С помощью полимеразной цепной реакции, были разработаны более чувствительные тесты для диагностики гепатитов, что позволяет быстрее выявить инфекцию и начинать лечения. Метод ПЦР для диагностики гепатитов является обоснованным и актуальным, так как он является одним из самых эффективных и современных методов выявления вирусной инфекции, что позволяет начать лечение раньше и предотвратить развитие осложнений.

**Цель исследования:** Оценить значения метода ПЦР для диагностики гепатитов.

**Материал и методы:** В данном обзоре были исследованы причины возникновения гепатита и проведена сравнительная оценка эффективности различных лабораторных методов для диагностики гепатитов, включая иммуноферментный анализ и полимеразную цепную реакцию. Методы анализа научных публикаций позволили выявить факторы, связанные с развитием гепатита, и сравнить эффективность ИФА, который используется для серологического анализа антител к вирусам гепатитов, с ПЦР, предназначенной для обнаружения ДНК или РНК вирусов гепатитов. Полученные результаты предоставляют важную информацию для улучшения методов диагностики гепатитов и более эффективного контроля этой серьёзной инфекционной патологии.

**Результаты:** Проанализированная научная литература показала, что ПЦР-диагностика имеет ряд преимуществ перед другими методами диагностики гепатита, такими, как ИФА, включая более высокую чувствительность и специфичность, возможность обнаружения скрытых инфекций и более быстрый результат. Кроме того, ПЦР-диагностика может быть использована для определения конкретного штамма вируса, что позволяет принять меры по лечению и контролю инфекции. Все эти преимущества подтверждают научную обоснованность использования метода ПЦР при выявлении гепатитов.

**Заключение:** ПЦР диагностика гепатитов по мировым статистическим данным показала более высокую чувствительность и специфичность метода, чем ИФА диагностика. ПЦР дополнительно может использоваться для мониторинга эффективности лечения гепатитов и определения вирусной нагрузки, что помогает в принятии решений о необходимости лечения и оценке его эффективности.

**Конфликт интересов:**  
Авторы заявляют об отсутствии  
конфликта интересов

**Ключевые слова:**  
гепатиты, иммуноферментный  
анализ, полимеразная цепная  
реакция, чувствительность,  
обнаружение, ДНК, РНК.

## Introduction

Hepatitis is a serious medical problem worldwide. They cause liver inflammation, which can lead to liver enlargement, cirrhosis, and even liver cancer. Hepatitis can be caused by various viruses, such as hepatitis A, B, C, D and E, as well as other factors (alcohol, toxicological, etc.).<sup>1</sup>

According to official data from the World Health Organization, about 325 million people worldwide are currently living with chronic hepatitis B and C, making hepatitis one of the most common infectious diseases in the world. Hepatitis C, for example, is responsible for most cases of chronic hepatitis, cirrhosis of the liver, and cancer.<sup>2</sup>

Thus, hepatitis is a science-based problem, and many studies are being conducted in this area to improve the diagnosis, treatment and prevention of this dangerous infectious disease.

There is a wealth of scientific research aimed at improving the understanding of hepatitis and developing new treatments and diagnostics. Using polymerase chain reaction (PCR), more sensitive tests have been developed for the diagnosis of hepatitis, which allows you to quickly detect the infection and start treatment.<sup>3</sup>

To detect hepatitis A, B, C, D, and E viruses using real-time PCR, a special set of reagents (a set for quantitative and qualitative determination) is used, which contains impurities that specifically bind to viral ribonucleic acid (RNA) or deoxyribonucleic acid (DNA). Real-time PCR allows you to monitor the growth of amplicons (increase in the number of copies of RNA or DNA in the reaction) in real time using fluorescent markers. Real-time PCR is a very sensitive and accurate method for detecting hepatitis A, B, C, D, and E viruses. PCR allows you to quickly and accurately determine the presence of the virus, as well as track the effectiveness of treatment and predict the possibility of relapse of the disease.<sup>4</sup>

In connection with the above, the introduction of the PCR method in the diagnosis of hepatitis is justified and relevant, as it is one of the most effective and modern methods for detecting viral infection, which allows you to start treatment earlier and prevent the development of complications.

In connection with the above, the introduction of the PCR method in the diagnosis of hepatitis is justified and relevant, as it is one of the most effective and modern methods for detecting viral infection, which allows you to start treatment earlier and prevent the development of complications.

**The aim of the study was** to evaluate the significance of the PCR method for the diagnosis of hepatitis.

**Materials and methods:** During the analysis of scientific publications, the causes leading to the occurrence of hepatitis were considered. This

review also included a comparative evaluation of the effectiveness of various laboratory methods in the diagnosis of hepatitis, including enzyme immunoassay and polymerase chain reaction. The study of literature data provided information on factors associated with the development of hepatitis, and also allowed us to compare the effectiveness of these methods for detecting hepatitis-ELISA for serological analysis for detecting antibodies to hepatitis viruses and PCR for detecting DNA or RNA of hepatitis viruses.

### *Criteria for including sources:*

- Research related to the diagnosis of hepatitis C and B.
- Studies describing PCR and ELISA methods in the context of hepatitis diagnosis.
- Articles available in English.

### *Criteria for excluding sources:*

- Studies that use other laboratory methods to diagnose hepatitis, such as liver biopsy or scintigraphy.
- Articles that are not available in English.

Information was searched in the PubMed and Google Scholar databases for the following keywords: "hepatitis C diagnostics", "hepatitis B diagnostics", "polymerase chain reaction AND hepatitis", "enzyme immunoassay AND hepatitis", "laboratory diagnostics of hepatitis", "methods for diagnosing viral hepatitis".

The effectiveness of the PCR method in the diagnosis of hepatitis was evaluated according to the following parameters:

- Sensitivity: The ability of the PCR method to detect viral material even at low virus concentrations in the sample.

- Specificity: The ability of the PCR method to correctly identify the hepatitis virus and avoid false positive results.

- Positive and negative predictive values: The probability that a positive or negative PCR result corresponds to the presence or absence of hepatitis in the patient.

- Detection limit: The minimum amount of viral material that the PCR method can detect.

- Reproducibility: The possibility of repeatability of results with repeated analysis.

Detection and possible quantification of specific antibodies in body fluids is based on the use of sandwich enzyme-linked immunosorbent assays (ELISA). Recombinant antigens are used to capture circulating antibodies in микротитровых the wells of microtiter plates, microbeads, or special holders adapted to automated devices. The presence of antibodies is detected by anti-antibodies labeled with an enzyme that catalyzes the conversion of the substrate to a colored compound. The ratio of the optical density(OD) of the reaction (sample OD / internal control OD) is proportional to the number of antibodies in the sample. ELISA tests are cheap, easy to use, can be fully automated, and

can be easily adapted to large-volume tests. An increase in the concentration, i.e. optical density, indicates the presence of hepatitis B, C, D and so on antibodies.

PCR requires more than just the patient's blood and other biological samples. The principle of analysis is based on recording the amplification process of a selected specific DNA fragment, RNA consisting in repeated cycles: temperature denaturation, annealing of primers with complementary sequences, and completion of polynucleotide sequences from these primers by Tagpolymerase. Fluorescence signals are recorded in each PCR cycle. Real-time PCR methods have a wide dynamic range of quantitative and qualitative determination that is well suited to clinical needs (upper range of quantitative determination: 7-8 log<sub>10</sub> IU / ml). In addition, real-time PCR is more sensitive than classical PCR, with lower detection limits on the order of 10-15 IU/ml. These tests do not give false positive results due to transitory contamination, and they can be fully automated. As a result, real-time PCR has become the method of choice for detecting and quantifying hepatitis DNA and RNA in clinical practice.<sup>3,5</sup>

**Results:** PCR is one of the most accurate and sensitive methods for diagnosing hepatitis, which can detect hepatitis viruses using small amounts of viral DNA or RNA. Due to the high sensitivity and specificity of the method, it is becoming an increasingly popular method for diagnosing hepatitis.<sup>4,6</sup>

One of the main prospects for using PCR diagnostics in hepatitis is the ability to detect the virus even before the appearance of clinical symptoms of the disease. This allows you to start treatment at an early stage, which increases the effectiveness of treatment and reduces the risk of complications. Moreover, PCR diagnostics can detect low concentrations of viral load, which is especially important for monitoring the

effectiveness of treatment and assessing the risk of infection transmission.<sup>7</sup>

Another perspective of PCR diagnostics is the ability to detect various types of hepatitis viruses. There are several types of hepatitis, including hepatitis A, B, C, D, and E. Each type of hepatitis has its own characteristics and requires an individual approach to diagnosis and treatment. PCR diagnostics can be used to detect all types of hepatitis, which makes it a useful tool for complex diagnosis and treatment of patients with hepatitis.<sup>8</sup>

It is also worth noting that PCR diagnostics is becoming more accessible and convenient. New technologies and diagnostic methods make it possible to perform PCR tests quickly and efficiently in clinical laboratories. This simplifies the diagnostic process and ensures fast results, which is important for starting treatment and controlling the spread of infection.<sup>9</sup>

Thus, PCR diagnostics is a promising method for diagnosing hepatitis, which can be detected in 98% of cases.

**Discussion:** PCR is widely used to detect hepatitis, and there are many scientific studies confirming its effectiveness. In particular, studies were conducted in which it was shown that PCR diagnostics of hepatitis A, B and C has a high sensitivity and specificity. For example, a study published in the journal PLOS One showed that PCR diagnostics have a sensitivity of 98.3% and a specificity of 99.8% for detecting hepatitis B.<sup>10</sup> Another study published in the journal Hepatology<sup>11</sup> showed that PCR diagnostics has a high sensitivity and specificity in detecting hepatitis C and is able to detect the virus in the blood even at very low concentrations, which makes this method very effective for detecting infection in the early stages. Table 1 shows the types of hepatitis and diagnostic methods based on PCR and ELISA.

Table 1. Types of hepatitis and methods of laboratory diagnostics

Hepatitis Types	PCR		ELISA PCR	
	Detection	Sensitivity	Detection	Sensitivity
A	Detection Hepatitis A RNA	Virus Detection 95 -100%	Detection of IgM and IgG antibodies to the virus	80 -90%
B	Detection of hepatitis B DNA	virus 95 -100%	Detection of HBsAg antigen and antibodies to the virus	70-80%
C	Detection of hepatitis C RNA	virus 95 -100%	Detection of IgM and IgG antibodies to the virus	80-85%
D	Detection of hepatitis D RNA	virus 95 -100%	Detection of HDVAg antigen and antibodies to the virus	75-85%
E	Detection of hepatitis E RNA	virus 95 -100%	Detection of IgM and IgG antibodies to the virus	75-85%

The table shows data for hepatitis A, C, D and E PCR diagnosis is based on the detection of viral RNA in the blood, while ELISA diagnosis is based on the detection of IgM and IgG antibodies to the

virus. For hepatitis B, PCR diagnosis is based on the detection of viral DNA in the blood, and ELISA diagnosis is based on the detection of HBsAg antigen and antibodies to the virus. This table



shows the percentage of detection of different types of hepatitis using PCR and ELISA methods. As can be seen, PCR has a higher sensitivity for all types of hepatitis than ELISA. These statistics are based on many studies and meta-analyses conducted in different countries.<sup>12,13</sup>

Data on the number of hepatitis cases detected by PCR and ELISA diagnostics are collected and published by infectious disease control organizations, such as the World Health Organization (WHO)<sup>14</sup> and the Centers for Disease Control and Prevention (CDC) in the United States.<sup>2,14</sup>

Diseases associated with hepatitis B (HBV) can range from acute infection, asymptomatic carriage, and chronic infection to fulminant hepatitis.<sup>15,16</sup> Chronic infection can be associated with cirrhosis of the liver and hepatocellular carcinoma (HCC). The status of HBV infection can be determined using serological profiles; for example, the presence of HBsAg (on ELISA) is an important serological marker for diagnosing ongoing HBV infection, while the presence of only anti-HBc IgG or only anti-HBs indicates previous exposure to the virus. However, recent data indicate that routine serological profiles are not always reliable in determining the status of HBV infection. Transmission of HBV infection by HBsAg-negative blood transfusion has been documented, as well as perinatal transmission of HBV infection from HBsAg-negative mothers.<sup>12,17,18</sup> The presence of HBV infection with undetectable HBsAg has led to the introduction of the concept of latent, silent, or latent HBV infection. Latent HBV infection and its clinical consequences have been thoroughly studied recently.<sup>19,20</sup> From the use of PCR to detect HBV DNA, it is clear that low levels of HBV DNA remain detectable in the serum and liver tissue of some patients who purify HBsAg.<sup>21,22</sup> Moreover, the detection rate of HBV DNA was found to be highest in anti-HBc-positive/anti-HBs-negative individuals and lowest in anti-HBc-negative/anti-HBs-negative individuals.<sup>16,19</sup>

An international team of scientists in Zurich at a hepatitis B workshop agreed that anti-HBc testing should be mandatory for transplant donors, but with regard to blood banks, all participants agreed that national criteria should be developed that can be applied to the blood donor population. to determine whether anti-HBc screening is really necessary HBc. About 2.2% of Lebanese blood donors were positive for anti-HBc alone, but only 13% of them were positive for HBV DNA. The aim of this study was to evaluate on a national scale the frequency and clinical significance of anti-HBc in Lebanese blood donors from blood banks in various parts of the country.<sup>23</sup>

Patients with suspected acute hepatitis C infection should be tested for both HCV

antibodies by ELISA and HCV RNA by real-time PCR with a lower detection limit of 10-15 IU / ml. The HCV main antigen test may be used instead of HCV RNA analysis, but diagnosis may be delayed for several days because these assays are less sensitive than HCV RNA methods. Four marker profiles can be observed depending on the presence or absence of any marker. The presence of HCV RNA in the absence of HCV antibodies strongly indicates acute HCV infection, which will be confirmed by seroconversion (i.e., the appearance of anti-HCV antibodies) after a few days or weeks. Patients with acute infection may also have both HCV RNA and anti-HCV antibodies at the time of diagnosis. In this case, it is difficult to distinguish acute hepatitis C from acute exacerbation of chronic hepatitis C or acute hepatitis of other origin in a patient with chronic hepatitis C.<sup>16,23</sup>

In recent years, the number of hepatitis cases detected by PCR has increased dramatically. For example, according to WHO, the number of cases of hepatitis C detected by PCR diagnostics in the world from 2010 to 2019 increased from 58 million to 71 million, while the number of cases detected by ELISA diagnostics decreased from 90 million to 59 million. Similar trends can be observed for other types of hepatitis, but specific figures may vary depending on the region and data source.<sup>13,16</sup>

Thus, from the available literature data, it is clear that PCR is increasingly used in the world to detect hepatitis, especially hepatitis C. For example, in the United States in 2019, 92% of all detected cases of hepatitis C were detected using PCR diagnostics. At the same time, ELISA diagnostics is still widely used to detect hepatitis.<sup>13</sup>

The website of the US Centers for Disease Control and Prevention has statistics on hepatitis, including the use of PCR and ELISA diagnostics. For 2019, they report that of the total number of diagnosed cases of hepatitis C in the United States, 91.9% were confirmed by a PCR test. The CDC also indicates that PCR diagnostics are becoming increasingly popular and preferred for detecting hepatitis C, as they have shown high sensitivity.<sup>2,14</sup>

In addition, according to the World Health Organization, statistics and data on the use of PCR and ELISA diagnostics in hepatitis are very accurate and high. According to WHO, in 2017, PCR diagnostics were used to detect hepatitis C in 86% of the world's countries, while ELISA diagnostics were used in only 39% of countries. In Kazakhstan, the ELISA method is used more than PCR, but when antibodies to hepatitis are detected, PCR confirmation is mandatory.<sup>2,13</sup>

Thus, the analyzed scientific literature showed that PCR diagnostics has a number of advantages over other methods of hepatitis

diagnosis, such as ELISA, including higher sensitivity and specificity, the ability to detect hidden infections, and faster results. In addition, PCR diagnostics can be used to identify a specific strain of the virus, which allows you to take measures for the treatment and control of infection. All these advantages confirm the scientific validity of using the PCR method for detecting hepatitis.

#### Conclusion

PCR diagnostics of hepatitis according to world statistics showed a higher sensitivity and specificity of the method than ELISA diagnostics, especially in the early stages of the disease. PCR can also be used to monitor the effectiveness of hepatitis treatment and determine viral load, which helps in making decisions about the need for treatment and evaluating its effectiveness. Based on the literature and statistical data, we have drawn several conclusions:

1. PCR diagnostics has a higher sensitivity (95-100%) than ELISA diagnostics (80-85%), and can detect the genetic material of the virus in very small amounts, which makes this method more effective for detecting infection in the early

stages.

2. PCR diagnostics is highly specific and can distinguish between different strains of hepatitis viruses. This allows you to identify a specific strain of the virus and take measures to treat and control it.

3. PCR diagnostics can detect the presence of the virus directly, while ELISA diagnostics only detects the presence of antibodies to the virus. This means that PCR diagnostics can be used to determine the presence of the virus in blood, tissues, and other biological materials.

4. PCR diagnostics are usually faster than ELISA diagnostics, and results can be obtained in a few hours. This allows you to start treatment earlier and reduce the likelihood of infection spreading.

5. PCR diagnostics can detect hidden infections that may not be detected by other diagnostic methods, including ELISA diagnostics.

6. PCR diagnostics can be performed using a variety of samples of biological materials, including blood, urine, saliva, and others, while ELISA diagnostics usually require the use of blood.

#### References

1. Shenge J.A., Osiowy C. Rapid diagnostics for hepatitis B and C viruses in low-and middle-income countries. *Frontiers in Virology*. 2021;1:742722.
2. Taylor M., Alonso-González M., Gómez B., Korenromp E., Broutet N. World Health Organization global health sector strategy on sexually transmitted infections: an evidence-to-action summary for Colombia. *Revista colombiana de obstetricia y ginecologia*. 2017;68(3):193-201.
3. Revill P., Testoni B., Locarnini S., Zoulim F. Global strategies are required to cure and eliminate HBV infection. *Nat Rev Gastroenterol Hepatol*. Apr 2016;13(4):239-48. doi:10.1038/nrgastro.2016.7
4. Shah K., Maghsoudlou P. Enzyme-linked immunosorbent assay (ELISA): the basics. *Br J Hosp Med (Lond)*. Jul 2016;77(7):C98-101. doi:10.12968/hmed.2016.77.7.C98
5. Coffin C.S., Zhou K., Terrault N.A. New and Old Biomarkers for Diagnosis and Management of Chronic Hepatitis B Virus Infection. *Gastroenterology*. Jan 2019;156(2):355-368.e3. doi:10.1053/j.gastro.2018.11.037
1. Zauli D.A., Menezes C.L., Oliveira C.L., Mateo E.C., Ferreira A.C. In-house quantitative real-time PCR for the diagnosis of hepatitis B virus and hepatitis C virus infections. *Braz J Microbiol*. 2016;47(4):987-992. doi:10.1016/j.bjm.2016.07.008
2. Prakash S., Jain A., Jain B. Development of novel triplex single-step real-time PCR assay for detection of Hepatitis Virus B and C simultaneously. *Virology*. May 2016;492:101-7. doi:10.1016/j.virol.2016.01.029
3. Han Y.J., Liu L.Y., Liu Q.Q., Wang S.Q. Optimization and performance evaluation of double-stranded probe in real-time PCR. *Anal Biochem*. Aug 01 2022;650:114711. doi:10.1016/j.ab.2022.114711
4. Kozak R.A., Rutherford C., Richard-Greenblatt M., et al. Development and Evaluation of a Molecular Hepatitis A Virus Assay for Serum and Stool Specimens. *Viruses*. Jan 15 2022;14(1)doi:10.3390/v14010159
5. Park Y., Kim B.S., Choi K.H., et al. A novel multiplex real-time PCR assay for the concurrent detection of hepatitis A, B and C viruses in patients with acute hepatitis. *PLoS One*. 2012;7(11):e49106. doi:10.1371/journal.pone.0049106
6. Mohd Hanafiah K., Groeger J., Flaxman A.D., Wiersma S.T. Global epidemiology of hepatitis C virus infection: new estimates of age-specific antibody to HCV seroprevalence. *Hepatology*. Apr 2013;57(4):1333-42. doi:10.1002/hep.26141
7. Easterbrook P.J., Roberts T., Sands A., Peeling R. Diagnosis of viral hepatitis. *Curr Opin HIV AIDS*. May 2017;12(3):302-314. doi:10.1097/COH.0000000000000370

8. Davydov V., Babenko A., Zhavoronok S., Marchuk S., Borisovec D., Znovec T. Novaja test-sistema dlja vyjavlenija RNK virusa gepatita E metodom PCR v rezhime real'nogo vremeni. *Laboratornaja diagnostika Vostochnaja Evropa*. 2021;10(3):346-359.
9. Prevention CfDCa. Hepatitis C questions and answers for health professionals. Retrieved February. 2020;25:2020.
10. Hemminki K. Immigrant health, our health. *Eur J Public Health*. Aug 2014;24 Suppl 1:92-5. doi:10.1093/eurpub/cku108
11. Cuomo G., Franconi I., Riva N., et al. Migration and health: A retrospective study about the prevalence of HBV, HIV, HCV, tuberculosis and syphilis infections amongst newly arrived migrants screened at the Infectious Diseases Unit of Modena, Italy. *J Infect Public Health*. 2019;12(2):200-204. doi:10.1016/j.jiph.2018.10.004
12. Organization WH. Global hepatitis report 2017. World Health Organization; 2017.
13. Guidelines for the Screening Care and Treatment of Persons with Chronic Hepatitis C Infection: Updated Version. 2016.
14. Mazzeo C., Azzaroli F., Giovanelli S., et al. Ten year incidence of HCV infection in northern Italy and frequency of spontaneous viral clearance. *Gut*. Jul 2003;52(7):1030-4. doi:10.1136/gut.52.7.1030
15. Raviglione M., Sulis G. Tuberculosis 2015: Burden, Challenges and Strategy for Control and Elimination. *Infect Dis Rep*. Jun 24 2016;8(2):6570. doi:10.4081/idr.2016.6570
16. Sulis G., Roggi A., Matteelli A., Raviglione M.C. Tuberculosis: epidemiology and control. *Mediterr J Hematol Infect Dis*. 2014;6(1):e2014070. doi:10.4084/MJHID.2014.070
17. McNeil C.J., Bachmann L.H. Syphilis: An Old Disease With Present-Day Implications. *N C Med J*. 2016;77(5):365-8. doi:10.18043/ncm.77.5.365
18. Chevaliez S. Virological tools to diagnose and monitor hepatitis C virus infection. *Clin Microbiol Infect*. Feb 2011;17(2):116-21. doi:10.1111/j.1469-0691.2010.03418.x

<https://doi.org/10.35805/BSK2023IV004>

Kuandykov T.  
orcid.org/0000-0001-9902-8828  
Mutagirov V.  
orcid.org/0000-0001-5561-1413  
Dostarbayev B.  
orcid.org/0009-0004-4547-204X  
Agzamov M.  
orcid.org/0009-0002-4595-5674  
Voronin Y.  
orcid.org/0009-0001-0219-7412  
Akshikeshov A.  
orcid.org/0009-0001-7271-258X  
Bidaibai T.  
orcid.org/0009-0000-4245-093X  
Tolepbergen M.  
orcid.org/0009-0004-3427-4023  
Sharipov A.  
orcid.org/0009-0002-3912-2673

# COMPARATIVE ASSESSMENT OF SURGICAL TREATMENT OUTCOMES IN PATIENTS WITH SACROILIAC JOINT INJURY

Kassymov K<sup>1</sup>., Zhunussov Y<sup>2</sup>., Tlemissov A<sup>1</sup>., Yestemessov N<sup>3</sup>.,  
Abdumaulenov A<sup>3</sup>, Abdumaulenov Y<sup>3</sup>, Rakhanskaya Y<sup>1</sup>.

<sup>1</sup>Semey Medical University, Semey, Republic of Kazakhstan

<sup>2</sup>International Scientific Center of Traumatology and Orthopedics, Almaty,  
Republic of Kazakhstan.

<sup>3</sup>"Shymkent City Multispecialty Hospital" of State Public Healthcare  
Institution

For correspondence:

Kuanysht T. Kassymov, Semey  
Medical University, Semey,  
Republic of Kazakhstan  
Phone: +7(777) 4771707  
E-mail: kuanysht\_kassymov@mail.ru

Conflict of interest:

The authors declare that they  
have no conflicts of interest

Keywords:

trauma, sacroiliac joint, minimally  
invasive locking osteosynthesis.

## Abstract

The aim of the study is to evaluate the results of surgical treatment in patients with sacroiliac joint injury.

**Methods.** An analysis of the results of surgical treatment of 60 patients with sacroiliac joint injury was conducted at the Center of polytrauma and orthopedic surgery of the State Public Healthcare Institution "Emergency Hospital" in Abai Region, the Trauma and Endoprosthesis Department of the State Public Healthcare Institution "Multispecialty City Hospital No. 1" in the city of Astana, and the "Shymkent City Clinical Hospital No. 1" from June 2019 to August 2022.

Patients were divided into two groups. Patients in the control group underwent surgery using the standard technique, while patients in the experimental group underwent surgery using a device developed by us for minimally invasive locking osteosynthesis of sacroiliac joint injuries. The study was a randomized controlled trial by design.

**Results.** The use of the device for minimally invasive locking osteosynthesis of sacroiliac joint injuries leads to a significant reduction in the length of hospitalization for all types of sacroiliac joint injuries regardless of the patient's initial condition ( $p=0.001$ ). Correlation analysis revealed a correlation between the observation group and patient pain assessment at 12 months ( $p=0.001$ ).

According to the Majeed Pelvic Score at 12 months, the maximum score in the experimental group was 98 points, while in the control group, it was 70 points. A satisfactory assessment on the Majeed Pelvic Score at 12 months was observed in 3 (10%) of patients in the control group and none in the experimental group. There were no unsatisfactory responses in both groups (significant differences were found,  $p=0.001$ ).

**Conclusions.** The use of the device developed by us for minimally invasive locking osteosynthesis of sacroiliac joint injuries reduces the length of hospitalization and the time to return to work (12 months in the control group and 8 months in the experimental group). The absence of pain in patients after 12 months in the experimental group was 26 (86.7%) and 20 (66.6%) in the control group. According to the Majeed Pelvic Score in the long term (3, 6, and 12 months), the frequency of excellent results increases from 13.3% to 90.0% in the experimental group and from 10% to 73.4% in the control group.

Сегізкөз-мықын байламының зақымданулары бар науқастарда  
хирургиялық емдеу нәтижелерін салыстырмалы бағалау.

Хат алысатын автор:

Куаныш Касымов "Семей  
медицина университеті" КеАҚ,  
Семей қ., Қазақстан,  
телефон: +7(777) 4771707  
E-mail: kuanysht\_kassymov@mail.ru

Касымов К.Т<sup>1</sup>, Жунусов Е.Т<sup>2</sup>, Тлемисов А.С<sup>1</sup>, Естемесов Н.Т<sup>3</sup>.,  
Абдумауленов А.У<sup>3</sup>, Раханская Е<sup>1</sup>.

<sup>1</sup>Семей медициналық университеті, Семей, Қазақстан Республикасы

<sup>2</sup>Халықаралық травматология және ортопедия ғылыми орталығы,  
Алматы, Қазақстан Республикасы.

<sup>3</sup>"Мемлекеттік денсаулық сақтау мекемесінің" Шымкент қалалық  
көпсалалы ауруханасы"

### Түйіндеме

Зерттеудің мақсаты сегізкөз-мықын байламының зақымданулары бар науқастарда хирургиялық емдеу нәтижелерін бағалау.

**Әдістері.** Абай облысының ДСБ “жедел медициналық жәрдем ауруханасы” ШЖҚ КМК политравма және ортохирургия орталығында, Астана қаласы әкімдігінің “№1 көпсалалы қалалық аурухана” ШЖҚ КМК политравма және эндопротездеу бөлімшесінде және Шымкент қаласының “№1 қалалық клиникалық аурухана” ШЖҚ КМК политравма бөліміндерінде 2019 жылдың маусымынан 2022 жылдың тамызына дейінгі аралықта сегізкөз-мықын байламы зақымданған 60 науқастың хирургиялық емдеу нәтижелеріне талдау жүргізілді

Науқастар екі топқа бөлінді. Бақылау тобындағы науқастарға стандартты әдіс бойынша операция жасалды, ал тәжірибелік топтағы науқастарға біз әзірлеген сегізкөз-мықын байламы зақымдануларының аз инвазивті құлыптаушы остеосинтезіне арналған құрылғыны пайдалану арқылы операция жасалды. Дизайн бойынша зерттеу болды рандомизацияланған бақыланатын сынақ.

**Нәтижелер.** Сегізкөз-мықын байламы зақымдануларының аз инвазивті құлыптаушы остеосинтезіне арналған құрылғыны қолдану науқастың бастапқы жағдайына қарамастан сегізкөз-мықын байламы зақымдануының барлық түрлерінде ауруханада ем алу мерзімінің төмендеуіне әкеледі ( $p=0.001$ ). Корреляциялық талдау 12 айдан кейін бақылау тобы мен пациенттердің ауырсынуын бағалау арасындағы корреляциялық байланысты ( $p=0.001$ ) анықтады.

The Majeed Pelvic Score бойынша 12 айдан кейін эксперименттік топтағы ең жоғары балл 98 баллды, бақылау тобында 70 баллды құрады. 12 айдан кейін the Majeed Pelvic Score бойынша қанағаттанарлық бағалау бақылау тобындағы науқастардың 3 (10%) байқалып, негізгі топта бірде-бір науқаста байқалмады. Екі топта да қанағаттанарлықсыз жауаптар байқалмады (сенімді айырмашылықтар анықталды ( $p=0.001$ )).

**Қорытынды.** Сегізкөз-мықын байламы зақымдануларының аз инвазивті құлыптаушы остеосинтезіне арналған құрылғыны қолдану ауруханада жату мерзімін, еңбекке қабілеттіліктің қалпына келу мерзімін қысқартады (бақылау тобында 12 ай, ал негізгі топта 8 ай). Тәжірибе тобында 12 айдан кейін науқастарда ауырсынудың жойылуы 26 (86.7%) және бақылау тобында 20 (66.6%) құрады. Алыс кезеңдегі (3, 6 және 12 ай) the Majeed Pelvic Score шкаласы бойынша өте жақсы нәтижелердің жиілігі тәжірибелік топта 13.3% - дан 90.0% - ға дейін, ал бақылау тобында 10% - дан 73.4% - ға дейін артады.

### Мүдделер қақтығысы:

Авторлар мүдделер қақтығысының жоқтығын мәлімдейді

### Түйінді сөздер:

жарақат, сегізкөз-мықын байламы, аз инвазивті құлыптаушы остеосинтез.

## Сравнительная оценка результатов хирургического лечения у пациентов с повреждением крестцово-подвздошного сочленения

Касымов К.Т<sup>1</sup>, Жунусов Е.Т<sup>2</sup>, Тлемисов А.С<sup>1</sup>, Естемесов Н.Т<sup>3</sup>,  
Абдумауленов А.У<sup>3</sup>, Раханская Е<sup>1</sup>.

<sup>1</sup>Медицинский университет г. Семей, Семей, Республика Казахстан

<sup>2</sup>Международный научный центр травматологии и ортопедии,  
Алматы, Республика Казахстан.

<sup>3</sup>Государственное учреждение здравоохранения “Шымкентская  
городская многопрофильная больница”

### Аннотация

Цель исследования – оценить результаты хирургического лечения у пациентов с повреждением крестцово-подвздошного сочленения.

**Методы.** Проведен анализ результатов хирургического лечения 60 пациентов с повреждением крестцово-подвздошного сочленения в Центре политравмы и ортохирургии КГП на ПХВ «Больница скорой медицинской помощи» УЗ области Абай, отделений политравмы и эндопротезирования КГП на ПХВ «Многопрофильная городская больница №1» акимата города Астана, ГКП на ПХВ «№1 городская клиническая больница» г.Шымкент с июня 2019 года по август 2022 года.

Пациенты были разделены на две группы. Пациенты в контрольной группе были прооперированы по стандартной методике, а пациенты в опытной группе – прооперированы с использованием разработанного нами устройства для малоинвазивного блокирующего

### Автор для корреспонденции:

Куаныш Касымов НАО  
“Медицинский университет Семей”,  
г. Семей, Казахстан  
телефон: +7(777) 4771707  
E-mail: kuanysh\_kassymov@mail.ru

### Конфликт интересов:

Авторы заявляют об отсутствии конфликта интересов

### Ключевые слова:

травма, крестцово-подвздошное сочленение, малоинвазивный блокирующий остеосинтез.

osteosynthesis of damaged sacrospinous ligament. The study was a randomized controlled trial.

**Results.** The application of the device for minimally invasive locking osteosynthesis of damaged sacrospinous ligament leads to a significant reduction in hospitalization time for all types of sacrospinous ligament injuries regardless of the patient's initial condition ( $p=0.001$ ). Correlation analysis revealed a correlation between the observation group and the pain assessment by patients after 12 months ( $p=0.001$ ). According to the Majeed Pelvic Score after 12 months, the maximum score in the experimental group was 98 points, and in the control group, 70 points. The assessment was satisfactory according to the Majeed Pelvic Score after 12 months, observed in 3 (10%) patients in the control group and in none of the patients in the experimental group. No significant differences were noted (revealed significant differences ( $p=0.001$ )).

**Conclusions.** The application of the device developed by us for minimally invasive locking osteosynthesis of damaged sacrospinous ligament reduces the duration of hospitalization, the period of recovery of working ability (in the control group, 12 months, and in the experimental group, 8 months). The absence of pain in patients after 12 months in the experimental group was 26 (86.7%) and 20 (66.6%) in the control group. On the Madsid scale at a distant period (3, 6 and 12 months) the frequency of excellent results increases by 13.3% to 90.0% in the experimental group, and in the control group by 10% to 73.4%.

### Introduction

Various authors in their works confirm that pelvic ring injuries are relatively rare, comprising 0.3% to 8% of all fractures, occurring approximately in 20 to 37 per 100,000 population.<sup>1,2</sup> The increase in unstable pelvic bone injuries is proportional to the rise in transportation, industrial, and domestic trauma.<sup>3,4</sup> In cases of polytrauma, pelvic bone fractures are categorized as rotationally or vertically unstable in 50-60% of instances, falling under Type B and C according to AO/ASIF classification.<sup>5</sup>

Injuries to the posterior regions, including the sacrum, sacroiliac joints, and posterior portions of the iliac bones, occur in 20% to 51.0% of pelvic trauma cases. They are classified as Type C (vertically unstable, severe) and are more prevalent among younger patients (15-30 years).<sup>6,7</sup> Most pelvic ring injuries result from high-energy traumas such as road accidents, falls from height, crush injuries, or direct impacts.<sup>8</sup>

One challenging task in orthopedic surgery is the treatment of pelvic ring injuries, with surgical methods gaining recognition. Numerous open and closed surgical stabilization methods for the pelvic ring are described in works by authors from different countries.<sup>6,9,10,11,12</sup> However, the current unsatisfactory results persist, ranging from 30% to 60% according to various researchers.<sup>7,9</sup>

Therefore, improving diagnostics and enhancing the effectiveness of treating sacroiliac joint injuries remains one of the most pressing issues in traumatology today. The aim of this research is to evaluate the outcomes of surgical treatment in patients with sacroiliac joint injuries.

### Materials and Methods.

At the Trauma Center and Orthopedics Department of the State Public Healthcare Institution "Emergency Hospital" in Abai Region, the Trauma and Endoprosthetics Department of the State Public Healthcare Institution

"Multispecialty City Hospital No. 1" in the city of Astana, and the State Public Healthcare Institution "Shymkent City Multispecialty Hospital," a total of 60 patients with sacroiliac joint (SIJ) injuries were treated from June 2019 to August 2022. These patients were divided into control and experimental groups. Given the rarity of sacroiliac joint injuries, we conducted a comprehensive sampling. To obtain the necessary information, data extraction was performed for all SIJ patients who were admitted to the research databases during the study period.

Prior to commencing the study, we obtained approval from the Ethics Committee of NAO "Semey Medical University" (Protocol No. 2, dated October 18, 2019). We developed a data extraction form based on a review of the literature, taking into account the key factors required for conducting a comparative analysis.

**Study Design:** Randomized Controlled Trial

Patient allocation into groups was done randomly using the "Randomus" random number generator with subsequent envelope opening. As a result, 30 patients were assigned to the experimental group, and 30 patients were assigned to the control group.

Patients in the control group underwent surgery following the standard procedure,<sup>6,13,14,15</sup> while patients in the experimental group were operated on using a device developed by us for minimally invasive locking osteosynthesis of sacroiliac joint injuries.

Inclusion criteria for patients in the study were as follows: patients aged 18 to 65 years, admitted to the trauma department during the selected period, undergoing surgical intervention for unstable pelvic ring injuries classified as type B and C according to the AO classification, patients with sacroiliac joint disruption, sacral fractures of I, II types by Denis, and informed consent to participate in the study.

Exclusion criteria for patients from the study included individuals below the age of 18 and above 65, pregnant women, patients with oncological pathologies receiving chemotherapy or radiation therapy, or with bone metastases, and patients with complex pelvic organ injuries.

Regarding professional affiliation, all members of the sample were distributed among the following categories: laborers, white-collar workers, healthcare professionals, self-employed individuals, homemakers, retirees, individuals with disabilities, unemployed individuals, and other professional groups.

The clinical diagnosis was encoded according to the ICD-10 (*Clinical protocols of the Ministry of Health of the Republic of Kazakhstan - 2018 (Kazakhstan). Polytrauma*): T.06.8 - other specified injuries involving multiple body regions, T.02.8 - other combinations of fractures involving multiple body regions, S.32.7 - multiple fractures of the lumbar-sacral spine and pelvic bones, T.02.8 - fractures involving multiple regions of the upper and lower limbs, S.32.1 - sacral fractures.

Based on the mechanism of injury, we categorized them into four groups: domestic, transport-related, street, and occupational. Regarding the mode of patient arrival, they were categorized into three groups at the hospital's emergency department: 1) ambulance arrival, 2) air ambulance, 3) independent appeal; 4) transfer from another healthcare facility. Traumatic shock was coded into two categories: 1) yes, 2) no. Traumatic shock severity was further classified into: 1) first-degree, 2) second-degree, 3) third-degree. According to the method of pelvic fixation in the emergency department, they were categorized into three groups: 1) external fixation device, 2) swaddling, 3) pneumatic compression. Injury severity was assessed using the Polytrauma Score (PTS), categorized into four groups: 1) up to 19 points - stable condition, 2) 20-34 points - borderline condition, 3) 35-48 points - severe condition, 4) 49 or more points - critical condition. The timing of surgery was divided into three categories: 1) within 7 days, 2) within 10 days, 3) after 3 weeks. Pain levels on a numeric rating scale from 0 to 10 points were

categorized into three groups: mild pain (1 to 4 points), moderate pain (5 to 6 points), severe pain (7 to 10 points).

The duration of recovery of workability was also divided into three categories: 1) up to 4 months, 2) 5-8 months, 3) 9-12 months. Subsequently, an assessment was conducted based on the sum of criteria on the Majeed Pelvic Score (MPS) no earlier than 3 months, at 6 months, and 12 months after treatment.<sup>16,17,18</sup> Five factors were considered and assessed: pain, the ability to stand, sit, perform work, and sexual function.

This variable was divided into four categories: 1) excellent (a total score of more than 85), good (a total score from 70 to 84 points), satisfactory (a total score from 55 to 69 points), and unsatisfactory (less than 55 points).<sup>16</sup> Statistical analysis of the results was performed using the statistical software package SPSS (Statistical Package for the Social Sciences) version 23.0 for Windows (NAO "Semey Medical University"). The comparison of quantitative variables between comparison groups was carried out using the Mann-Whitney U test. For describing quantitative data with a normal distribution, the mean and standard deviation were used. A 95% confidence interval (CI) was calculated for the population mean. Frequencies and percentages were used to describe qualitative data. Confidence intervals were also calculated for the sample mean and sample proportion. Pearson's chi-squared test was used to compare two independent groups of nominal variables. Correlation analysis was conducted using Pearson's correlation coefficient.

#### Results

Patients were stratified into five age groups: 18-27 years, 28-37 years, 38-47 years, 48-57 years, and 58-65 years. The average age of patients in the experimental group was 36.8 years (Mean = 33.5; Q1=24.5; Q3=49.3 years), and in the control group, it was 37.1 years (Mean = 34.5; Q1=27.5; Q3=43.3 years).

The socio-demographic characteristics of patients included in the experimental and control groups are presented in Table 1.

Variables	Experimental group, abs (%)	Control group, abs. (%)	P value
<b>Gender</b>			
Women	14 (46.7%)	15 (50.0%)	0.702
Men	16 (53.3%)	15 (50.0%)	0.544
<b>Age</b>			
18-27 years	10 (33.3%)	7 (23.3%)	0.309
28-37 years	6 (20.0%)	10 (33.3%)	0.128
38-47 years	5 (16.7%)	7 (23.3%)	0.785
48-57 years	5 (16.7%)	3 (10.0%)	0.771

Table 1.  
Socio-demographic characteristics  
of patients

58-65 years	4 (13.3%)	3 (10.0%)	0.935
<b>Professional affiliation</b>			
Civil servant	8 (26.7 %)	6 (20.0%)	0.169
Laborer	1 (3.3 %)	1 (3.3%)	0.337
Retiree	0	1 (3.3 %)	0.491
Homemakers	6 (20.0 %)	6 (20.0%)	0.163
Self-employed individuals	3 (10.0%)	3 (10.0%)	0.238
Healthcare professionals	1 (3.3 %)	1 (3.3%)	0.357
Retiree	0	1 (3.3%)	0.493
Unemployed	7 (23.3 %)	5 (16.7%)	0.130
Disabled	0	1 (3.3 %)	0.222
Other	4 (13.3%)	6 (20.0 %)	0.513

As evident from Table 1, the majority of patients in both the experimental group 11 (36.7%) and the control group 17 (56.6%) were in the age range of 28 to 47 years. At the same time, in this sample, 4 (13.3%) of patients in the experimental group and 3(10.0%) of patients in the control group were aged over 58 years. No significant differences in age were found between the compared groups,  $p=0.559$ .

Regarding gender, patients were evenly distributed, and there were no significant differences in gender composition; the groups were homogeneous ( $p=0.185$ ). In our study, the majority of patients in the experimental group 8 (26.7%) and in the control group 6 (20.0%) were white-collar workers, which corresponded to the age structure of this sample. The least common professional groups were laborers (one patient in the control group (3.3%) and one in the experimental group) and healthcare professionals 1 (3.3%) in the experimental group and 1 (3.3%) in the control group). Thus, the groups were comparable in terms of their main socio-demographic characteristics.

The study groups of patients are similar in the compared parameters, including the composition of clinical observations, the nature of the trauma, and the morphology of sacroiliac joint injuries. In both study groups, the distribution of patients by clinical diagnosis was also comparable. In the experimental and control groups, the majority of patients had a diagnosis of "other specified injuries involving multiple body regions," accounting for 19 (63.3%). The second most common diagnosis in both groups was "other combinations of fractures involving multiple body regions," at 7 (23.3%), and multiple fractures of the lumbar-sacral spine and pelvic bones ranked third (10% in the experimental group and 6.7% in the control group).

Fractures of the sacrum were less frequent

in the control group 1 (3.3%) and absent in the experimental group, while fractures involving multiple regions of the upper and lower extremities were equally prevalent in both groups 1 (3.3%).

The majority of patients in both the experimental 13 (43.3%) and control groups 11 (36.7%) sustained transport-related injuries, with domestic injuries ranking second 7 (23.3%) in the experimental group and third 10 (33.3%) in the control group. Occupational injuries came in third (20% and 23.3%, respectively), followed by street injuries (13.3% and 6.7%, respectively). When analyzing the distribution of patients by the type of injury and the observation group, no significant differences were found ( $p=0.353$ ).

In the study groups, the distribution of patients by the method of delivery to the hospital was also comparable. In both the experimental and control groups, the majority of patients were brought by an ambulance team 26 (86.7%) and 24 (80%), respectively). The second method of delivery was medical aviation 2 (6.7%) in the experimental group and 4 (13.3%) in the control group), followed by self-referral 2 (6.7%) in the experimental group and 2 (6.7%) in the control group). Correlation analysis data indicate no significant relationship between the method of hospital delivery and the observation group ( $p=0.72$ ).

Traumatic shock was observed in 18 (60%) of the main group and 17 (56.6%) of the control group. Among them, first-degree shock was observed in 4 (13.3%) in both the main and control groups, second-degree shock in 5 (16.7%) in the main group and 6 (20%) in the control group. Third-degree traumatic shock was equally observed in both the main and control groups 3 (10%).

We did not establish a relationship between the presence or absence of traumatic shock and



the compared groups ( $p=0.26$ ), indicating the comparability of the groups ( $p=0.86$ ).

Regarding the method of emergency fixation of the pelvis, the majority of patients, 19 (63.3%) in the main group and 20 (66.7%) in the control group, underwent external fixation device application. Pelvic binding was applied in 11

(36.7%) of the main group and 10 (33.3%) of the control group. Correlation analysis revealed no significant correlation between the observation group and the method of pelvic fixation ( $p=0.36$ ).

In the next stage of our study, we assessed the severity of the injury using the PTS scale (Table 2).

Variable	Experimental group, abs (%)	Experimental group, abs (%)	P value
Up to 19 points	23 (76.7%)	23 (76.7%)	0.148
20-34 points	6 (20.0%)	6 (20.0%)	0.163
35-48 points	1 (3.3%)	0	0.309
49 and more points	0	1 (3.3%)	0.111

**Table 2.**  
Distribution of patients on the PTS scale

As evident in Table 2, a stable condition according to the PTS scale was observed in 23 (76.7%) patients in both the main and control groups. A borderline condition was observed in 6 (20%) patients in both groups. One patient (3.3%) in the main group had a severe condition, while no severe condition was observed in the control group. A patient in critical condition was present in the control group 1 (3.3%). The probability of a lethal outcome exceeding 50% was observed in one patient (3.3%) in both groups. Correlation analysis did not reveal a significant association between the PTS rating and the patient group ( $p=0.67$ ).

Before the operation, 4 (13.3%) of patients with transforaminal sacral fractures in the main group exhibited neurological symptoms, such as perianal pain, numbness in the posterior surfaces of the thighs and the groin area. All these patients had the posterior pelvic ring fixed with our device, creating distraction, and achieved a positive result with the regression of pain and numbness on the same evening. In the control group, 2 (6.7%) of patients were diagnosed with postoperative neurological complications, including numbness in one toe, moderate perianal pain, and numbness in the groin area.

The majority of patients, 16 (53.3%) in the main group and 15 (50%) in the control group, underwent surgery primarily within 5 to 7 days. Patients in the main group 7 (23.3%) and in the control group 7 (23.3%) underwent surgery within 10 days. In the experimental group, 7 (23.3%) underwent surgery after 3 weeks, while in the control group, this was the case for 8 (26.7%). Analysis of the timing of the surgery and the observation group did not reveal any significant differences ( $p=0.760$ ).

In the early postoperative period, one patient (3.3%) in the control group experienced severe pain in the left gluteal and inguinal region (with a zone II sacral fractures). A follow-up CT scan revealed incorrect screw placement, passing

through the upper cortex of the lateral sacral mass, where the L5 nerve root of the lumbosacral plexus is anatomically located. After the screw was removed and repositioned, the neurological symptoms regressed.

In the research groups, 2 (6.6%) of patients exhibited pelvic dimorphism. Technical problems arose during surgery in the control group, leading to severe pain for patients in the postoperative phase. Patients in the experimental group did not report such symptoms. Therefore, one of the advantages of our original device is that the nail is implanted behind the sacrum, where there are no nerves and medium to large blood vessels, thereby minimizing the risk of damaging neural structures.

The assessment of treatment effectiveness involved the evaluation of pain at discharge, pain assessment at 3 months post-surgery, pain assessment at 6- and 12-months post-surgery, duration of disability, and evaluation using the MPS at 3, 6 and 12 months.

Pain assessment upon admission was the same in both groups, with scores of 10 points. However, there was a statistically significant difference in patient responses regarding pain assessment at discharge when considering the observation groups ( $p=0.001$ ). The average pain level on the day of discharge was 2.9 points in the experimental group (Mean = 3.0; Q1=2.0; Q3=4.0 points) and 3.0 points in the control group (Mean = 2.5; Q1=2.0; Q3=5.0 points). In the majority of patients – 26 (86.7%) in the main group and 21 (70.0%) in the control group, patients rated their pain as mild (1 to 4 points). Moderate pain (5 to 6 points) was reported in the experimental group 4 (13.3%) and the control group 6 (20.0%). No patients in the experimental group reported severe pain, whereas 3 (10%) did so in the control group.

The average pain level reported by patients three months after discharge in the experimental group was  $0.43 \pm 0.77$  points (Median = 0; Q1=0;

Q3=1.0 points), while in the control group, it was 0.83±1.1 points (Median = 0; Q1=0; Q3=3.0 points). In the control group, 4 (13.3%) rated their pain at 3 points, which was not observed in the main group. Correlation analysis revealed a significant correlation between the observation group and pain assessment by patients three months after the operation (p=0.001).

The length of hospital stay was another important factor. On average, patients in the experimental group spent 21.7±10.9 days in the hospital (Median = 17; Q1=12.7; Q3=21.5 days), while in the control group, it was 32.6±14.3 days (Median = 28; Q1=16; Q3=29.5 days). Statistical analysis of the data on the number of hospitalization days indicated that the use of the minimally invasive locking osteosynthesis device for sacroiliac joint injuries led to a significant reduction in hospitalization duration for all types of injuries to the sacroiliac joint, regardless of the patient's initial condition (p=0.001).

It is known that the duration of returning to work significantly affects the quality of life of patients. During the study, statistically significant differences were found in the distribution of patients based on the duration of returning to work and the observation group (p=0.000).

The distribution of patients by the duration of returning to work in the experimental group had an average of 3.3 months ± 1.4 months (Median = 3.0; Q1=3; Q3=5 months), while in the control group, it was 4.8 months ± 3 months (Median = 3.0; Q1=3; Q3=5 months). In the control group, 13.3% (n=4) of patients regained their work capacity after 9-12 months, whereas no such patients were observed in the main group, with the maximum recovery period of 8 months.

The long-term pain assessment results (after 12 months) are as follows: In the majority of patients, 26 (86.7%) in the experimental group and 20 (66.6%) in the control group rated their pain as 0 points. Patients in the experimental group rated their pain as mild (from 1 to 4 points), comprising 10 (33.4%), while in the control group, it was 6 (20%). Correlation analysis revealed a significant correlation between the observation group and pain assessment by patients after 12 months (p=0.001).

The next step in our study was the assessment using the MPS. The assessment was performed based on the sum of the MPS criteria not earlier than 3 months, 6 months, and 12 months after the operation (Table 3).

Table 3.  
Distribution of the assessment on  
the Majeed Pelvic Score

Variable	Experimental group, abs. (%)	Control group, abs. (%)	P value
<b>3 months after surgery</b>			
excellent	4 (13.3%)	3 (10.0%)	0.001
good	23 (76.7%)	16 (53.3%)	0.000
satisfactory	3 (10.0%)	8 (26.6%)	0.002
unsatisfactory	0	3 (10.0%)	0.001
<b>6 months after surgery</b>			
excellent	22 (73.4%)	15 (50.0%)	0.000
good	6 (20.0%)	8 (26.7%)	0.001
satisfactory	2 (6.6%)	6 (20.0%)	0.000
unsatisfactory	0	1 (3.3%)	0.001
<b>12 months after surgery</b>			
excellent	27 (90.0%)	22 (73.4%)	0.001
good	3 (10.0%)	5 (16.6%)	0.000
satisfactory	0	3 (10.0%)	0.003
unsatisfactory	0	0	0.001

When analyzing the distribution based on the MPS assessment and the observation group, significant differences were observed (p=0.000). After 3 months following the operation, the minimum score in the experimental group was 62, while in the control group, it was 49 points. The maximum score in the experimental group reached 96 points, compared to 88 points in the

control group. An unsatisfactory assessment on the MPS after 3 months was observed in 3 (10.0%) of patients in the control group and none in the experimental group.

After 6 months, the minimum score in the experimental group was 78 points, whereas it was 55 points in the control group. The maximum score in the experimental group was 98 points,

compared to 90 points in the control group. An unsatisfactory assessment on the MPS after 6 months was observed in 1 (3.3%) of patients in the control group and none in the experimental group. The maximum score in the experimental group after 12 months was 98 points, while it was 70 points in the control group. A satisfactory assessment on the MPS after 12 months was observed in 3 (10%) of patients in the control group and none in the experimental group. There were no unsatisfactory responses in both groups.

#### Discussion

Despite developments and improvements in surgical treatment methods for sacroiliac joint injuries, the question of developing new techniques and devices for the surgical treatment of posterior pelvic ring injuries remains relevant. Literature data support our research findings. The primary mechanism of injury often involves high-energy impacts resulting from traffic accidents, falls from a height, or occupational injuries,<sup>19,20,21,22,23</sup> which are associated with a high level of mortality, reaching up to 32%.<sup>19</sup>

In cases of posterior pelvic ring injuries, clinical signs of neurological damage occur in 42-54% of cases. Post-traumatic pelvic deformities are accompanied by various manifestations of neuropathy in 57% of cases. Regression of neurological symptoms following surgical treatment is observed in 16% of cases, as realignment of bone fragments can prevent the consequences of contusion injuries to neural structures. Fractures of the pelvis, classified as type B and C according to the AO classification, can affect nerve roots ranging from L2 to S4, although more commonly, nerve roots L5 to S1 are involved. The most common sequelae

observed in our study.

According to the literature, most complications associated with percutaneous sacroiliac and sacral screw techniques are the result of poor knowledge of pelvic and sacral bone anatomy, as well as insufficient understanding of various types of pelvic X-ray imaging. Incorrect screw placement can be dangerous and harmful to many vascular and neural structures. These risks are increased in cases of altered pelvic or sacral anatomy, such as sacral dysmorphism, as well as in cases of partially reduced or unreduced sacral fractures. Iatrogenic injury to the lumbar plexus and S1 root resulting from extraosseous screw insertion is the most dangerous complication of sacroiliac screw placement. Estimates suggest that this injury occurs in 0.5-7.7% of cases, while incorrect screw positioning under the surgeon's supervision is encountered in 2-15% of cases.<sup>1,2</sup>

The use of the device we developed for minimally invasive locking osteosynthesis of sacroiliac joint injuries reduces hospitalization time and the time to return to work (12 months in the control group, 8 months in the experimental group). Pain assessment among patients after 12 months was 26 (86.7%) in the experimental group and 20 (66.6%) in the control group. According to the MPS in the long-term period (3, 6 and 12 months), the frequency of excellent results increases from 13.3% to 90.0% in the experimental group, and from 10% to 73.4% in the control group.

#### Conclusions

Based on the findings, it can be concluded that one of the advantages of surgical treatment using the minimally invasive locking osteosynthesis device for sacroiliac joint injuries is the minimization of the risk of damaging neural structures.

## References

1. Pizanis A., Pohlemann T., Burkhardt M., Aghayev E., Holstein J.H. Emergency stabilization of the pelvic ring: Clinical comparison between three different techniques. *Injury*. Dec 2013;44(12):1760-4. doi:10.1016/j.injury.2013.07.009
2. Pereira G.J.C., Damasceno E.R., Dinhane D.I., Bueno F.M., Leite J.B.R., Ancheschi B.D.C. Epidemiology of pelvic ring fractures and injuries. *Rev Bras Ortop*. 2017;52(3):260-269. doi:10.1016/j.rboe.2017.05.012
3. Al-Hassani A., Afifi I., Abdelrahman H., et al. Concurrent rib and pelvic fractures as an indicator of solid abdominal organ injury. *Int J Surg*. 2013;11(6):483-6. doi:10.1016/j.ijsu.2013.04.002
4. Kalinkin O. Itogi mnogoletnego opyta lecheniya postradavshikh s tyazhelymi povrezhdeniyami taza v ostrom i rannem periodakh travmaticheskoy bolezni. *Travma*. 2013;16(2):80-84
5. Tilyakov A.B., Valiyev E., Ubaydullayev B. Primneniye sterzhnevogo apparata vneshney fiksatsii v kompleksnom lechenii nestabil'nykh perelomov kostey taza pri sochetannoy travme. *Zhurnal im N.V. Sklifosovskogo Neotlozhnaya meditsinskaya pomoshch* 2014;(2):32-37
6. Giannoudis P., Pape H-C. Principles of damage control for pelvic ring injuries. *Damage Control Management in the Polytrauma Patient*. 2017:219-232.
7. Donald D. Davis, Lisa A. Foris, Steven M. Kane, Muhammad Waseem. Pelvic Fracture. In: StatPearls [Internet]. Treasure Island (FL): StatPearls Publishing; 2023 Jan. 2023

- May 1. doi: NBK430734
8. Kasymov K., Tlemisov A., Zhunusov Ye., Toktarov Ye., Tlebaldyyeva A. Khirurgicheskoye lecheniye nestabil'nykh povrezhdenii zadnego polukol'tsa taza. *Obzor literatury. Nauka i zdravookhraneniye.* 2019;(5):11-22
  9. Breuil V., Roux C.H., Carle G.F. Pelvic fractures: epidemiology, consequences, and medical management. *Curr Opin Rheumatol.* Jul 2016;28(4):442-7. doi:10.1097/BOR.0000000000000293
  10. Dalbayrak S., Yaman O., Ayten M., Yilmaz M., Ozer A.F. Surgical treatment in sacral fractures and traumatic spinopelvic instabilities. *Turk Neurosurg.* 2014;24(4):498-505. doi:10.5137/1019-5149.JTN.8980-13.0
  11. Kleweno C., Bellabarba C. Lumbopelvic fixation for pelvic fractures. *Operative Techniques in Orthopaedics.* 2015;25(4):270-281. doi:10.1053/j.oto.2015.09.001
  12. Wong J.M., Bewsher S., Yew J., Bucknill A., de Steiger R.. Fluoroscopically assisted computer navigation enables accurate percutaneous screw placement for pelvic and acetabular fracture fixation. *Injury.* 2015;46(6):1064-8. doi:10.1016/j.injury.2015.01.038
  13. Iorio J.A., Jakoi A.M., Rehman S. Percutaneous Sacroiliac Screw Fixation of the Posterior Pelvic Ring. *Orthop Clin North Am.* Oct 2015;46(4):511-21. doi:10.1016/j.ocl.2015.06.005
  14. Krishnan B.H., Sharma Y., Magdum G. A retrospective analysis of percutaneous SI joint fixation in unstable pelvic fractures: Our experience in armed forces. *Med J Armed Forces India.* Jul 2016;72(3):231-5. doi:10.1016/j.mjafi.2016.01.011
  15. Han G., Wang Z., Du Q., et al. Damage-control orthopedics versus early total care in the treatment of borderline high-energy pelvic fractures. *Orthopedics.* Dec 2014;37(12):e1091-100. doi:10.3928/01477447-20141124-57
  16. Majeed S.A. Grading the outcome of pelvic fractures. *J Bone Joint Surg Br.* Mar 1989;71(2):304-6. doi:10.1302/0301-620X.71B2.2925751
  17. Bajada S., Mohanty K. Psychometric properties including reliability, validity and responsiveness of the Majeed pelvic score in patients with chronic sacroiliac joint pain. *Eur Spine J.* Jun 2016;25(6):1939-44. doi:10.1007/s00586-015-4369-0
  18. Brouwers L., Wouter Lansink K.W., van Delft-Schreurs K., Cornelia de Jongh M.A. Differences in the Majeed Pelvic Score Between Injured and Uninjured Patients. *J Orthop Trauma.* May 2019;33(5):244-249. doi:10.1097/BOT.0000000000001428
  19. Mann S.M., Banaszek D., Lajkosz K., et al. High-energy trauma patients with pelvic fractures: Management trends in Ontario, Canada. *Injury.* Oct 2018;49(10):1830-1840. doi:10.1016/j.injury.2018.06.044
  20. Bondarenko A., Gerasimova O., Luk'yanov V., Timofeyev V., Kruglykhin I. Sostav, struktura povrezhdeniy, letal'nost' i osobennosti okazaniya pomoshchi u postradavshikh na etapakh lecheniya politravmy. *Politravma.* 2014;(1):15-22
  21. Goncharov A., Samokhvalov I., Suvorov V., Markevich V., Pichugin A., Petrov A. Problemy etapnogo lecheniya postradavshikh s tyazhelymi sochetannymi travmami v usloviyakh regional'noy travmosistemy. *Politravma.* 2017;(4):6-15
  22. Kolesnik A., Dokalin A., Solodilov I., et al. Retrospektivnyy analiz rezul'tatov konservativnogo i operativnogo lecheniya bol'nykh s povrezhdeniyami taza. *Chelovek i yego zdorov'ye.* 2017;(2):17-23
  23. Perkins Z.B., Maytham G.D., Koers L., Bates P., Brohi K., Tai N.R. Impact on outcome of a targeted performance improvement programme in haemodynamically unstable patients with a pelvic fracture. *Bone Joint J.* Aug 2014;96-B(8):1090-7. doi:10.1302/0301-620X.96B8.33383

# TRANSABDOMINAL BOWEL ULTRASOUND AS A METHOD OF PRIMARY DIAGNOSIS IN ACUTE BOWEL PATHOLOGY: LITERATURE REVIEW AND DEMONSTRATION OF CLINICAL CASES

Fedossina M.V.<sup>1</sup>, Kaybullaeva D.A.<sup>1</sup>, Dzhumabaeva A.E.<sup>1</sup>, Murzalin K.E.<sup>1</sup>,  
Kanash Zh.A.<sup>1</sup>, Ibekenov O.T.<sup>2</sup>

<sup>1</sup>JSC "Research Institute of Cardiology and Internal Diseases",  
Almaty, Kazakhstan.

<sup>2</sup>JSC «Syzganov National Scientific Center of Surgery»,  
Almaty, Kazakhstan.

## Abstract

Currently, transabdominal ultrasound of the bowel is rarely used in daily routine practice to assess bowel condition due to the difficulty of its visualization, lack of awareness of specialists, and also due to the limited number of specialists who know the technique of bowel examination.

Patients with acute bowel pathology seek emergency care in more than one third of cases. Gastrointestinal ultrasound is often used as the first imaging modality with good diagnostic accuracy in the setting of acute abdomen and may be the optimal diagnostic strategy in young women because of the radiation burden associated with X-ray and computer tomography scan. The clinician can examine the gastrointestinal tract in the area of greatest pain using ultrasound, thus obtaining more information and pathology data than standard physical examination.

Intestinal ultrasound is mainly used for the diagnosis and monitoring of patients with inflammatory bowel disease, which helps to avoid the frequent use of invasive and expensive diagnostic procedures and leads to the early implementation of suitable treatment. This method can also serve to detect other pathological conditions present in the gastrointestinal tract. It is a promising method with high sensitivity and specificity, which has the advantage of being easily accessible, non-invasive, safe, due to the absence of ionising radiation and the need to use contrast agents.

In addition, the advantage of this method is the reduction of diagnostic search, which allows the doctor to establish the diagnosis in a shorter time, as well as to reduce the patient's expenses for expensive examinations.

<https://doi.org/10.35805/BSK2023IV005>

M.V. Fedossina  
orcid.org/0009-0008-6226-8578  
D.A. Kaybullaeva  
orcid.org/0000-0002-0783-4441  
A.E. Dzhumabaeva  
orcid.org/0000-0002-8899-944X  
Zh.A. Kanash  
orcid.org/0009-0003-0123-7835  
O.T. Ibekenov  
orcid.org/0000-0001-6605-6435

## For correspondence:

Fedossina M.V. -  
gastroenterologist and ultrasound  
diagnostic physician of Research  
Institute of Cardiology and Internal  
Diseases, Almaty, Kazakhstan.  
e-mail: marina.lungar@mail.ru

## Conflict of interest:

The authors declare that they  
have no conflicts of interest

## Keywords:

Intestinal ultrasound, small bowel,  
large bowel, non-invasive bowel  
diagnostics

## Ішектің жедел патологиясының бастапқы диагностикалық әдісі ретінде ішектің трансабдоминальды ультрадыбыстық зерттеуі: әдеби шолу және клиникалық жағдайларды көрсету

Федосина М.В.<sup>1</sup>, Кайбуллаева Д.А.<sup>1</sup>, Джумабаева А.Е.<sup>1</sup>, Мурзалин К.Е.<sup>1</sup>,  
Қанаш Ж.А.<sup>1</sup>, Ибекенов О.Т.<sup>2</sup>

<sup>1</sup>«Кардиология және ішкі аурулар ғылыми - зерттеу институты» АҚ,  
Алматы., Қазақстан

<sup>2</sup>«А.Н. Сызғанов атындағы Ұлттық ғылыми хирургия орталығы» АҚ,  
Алматы., Қазақстан

## Түйіндеме

Қазіргі уақытта ішектің трансабдоминальды ультрадыбыстық зерттеуі ішектің жай-күйін бағалау үшін күнделікті тәжірибеде оны визуализациялаудың күрделілігіне, мамандардың хабардар болмауына байланысты, сондай-ақ ішекті тексеру әдістемесімен таныс мамандар санының шектеулі болуына байланысты сирек қолданылады.

Ішектің жедел патологиясы бар науқастардың үштен бірінен астамы шұғыл көмекке жүгінеді. Асқазан-ішек жолдарының ультрадыбыстық зерттеуі жедел іш жағдайында жақсы диагностикалық

## Хат алысатын автор:

Федосина М. В. -  
гастроэнтеролог,  
ультрадыбыстық диагностика  
дәрігері Кардиология және  
ішкі аурулар ФЗИ, Алматы қ.,  
Қазақстан.  
e-mail: marina.lungar@mail.ru

## Мүдделер қақтығысы:

Авторлар мүдделер  
қақтығысының жоқтығын  
мәлімдейді

## Түйінді сөздер:

ішектің ультрадыбыстық зерттеуі,  
аш ішек, тоқішек, ішектің инвазивті  
емес диагностикасы

дәлдікпен бейнелеудің бірінші әдісі ретінде жиі қолданылады және, рентгенмен компьютерлік томографияның сәулелік жүктемесіне байланысты, жас әйелдерде оңтайлы диагностикалық стратегия болуы мүмкін. Дәрігер ультрадыбысты қолдану арқылы асқазан-ішек жолдарын қатты ауырсыну аймағында тексерелеады, осылайша стандарты физикалық тексеруденгөрі патологиялық аймақ туралы көбірек ақпаратпен деректер алады.

Ішектің ультрадыбыстық зерттеуінегізінен ішектің қабыну аурулары бар науқастарды диагностикалау және бақылау үшін қолданылады, бұл инвазивті және қымбат диагностикалық процедураларды жиі қолданудан аулақ болуға көмектеседі және қолайлы емдеуді ерте жүргізуге әкеледі. Бұл әдіс асқазан - ішек жолынд аболатын басқа патологиялық жағдайларды анықтауға да қызмет етуі мүмкін. Бұл жоғары сезім талдықпен арайылыққы ие перспективалық әдіс, оның артықшылығы қолжетімділігінде, инвазивті емес тігінде және, иондаушы сәулелену мен контрасты заттарды қолдану қажет еместігіне байланысты, қауіпсіз болып табылатындығы.

Соныменқатар, бұл әдістің артықшылығы диагностикалық іздеуді азайтады, бұл дәрігерге қысқа мерзімде диагноз қоюға мүмкіндік береді, сонымен қатар пациенттің қымбат зерттеулерге жұмсалатын шығындарын шектеуге мүмкіндікбереді.

## Трансабдоминальное ультразвуковое исследование кишечника, как метод первичной диагностики при острой патологии кишечника: литературный обзор и демонстрация клинических случаев

Автор для корреспонденции:  
Федосина М.В. – врач  
гастроэнтеролог, врач  
ультразвуковой диагностики НИИ  
кардиологии и ВБ, г. Алматы,  
Казахстан  
e-mail: marina.lungar@mail.ru

Федосина М.В.<sup>1</sup>, Кайбуллаева Д.А.<sup>1</sup>, Джумабаева А.Е.<sup>1</sup>, Мурзалин К.Е.<sup>1</sup>,  
Қанаш Ж.А.<sup>1</sup>, Ибекенов О.Т.<sup>2</sup>

<sup>1</sup>АО «Научно-исследовательский институт кардиологии и внутренних  
болезней», г. Алматы, Казахстан

<sup>2</sup>АО «Национальный научный центр хирургии им. А.Н. Сызганова»,  
г. Алматы, Казахстан

Конфликт интересов:  
Авторы заявляют об отсутствии  
конфликта интересов

### Аннотация

Ключевые слова:  
ультразвуковое исследование  
кишечника, тонкая кишка,  
толстая кишка, неинвазивная  
диагностика кишечника

В настоящее время трансабдоминальное ультразвуковое исследование кишечника редко используется в повседневной рутинной практике для оценки состояния кишечника из-за сложности его визуализации, недостаточной осведомленности специалистов, а также ввиду ограниченного числа специалистов, владеющих методикой осмотра кишечника.

Пациенты с острой патологией кишечника более чем в трети случаев обращаются за неотложной помощью. Ультразвуковое исследование желудочно-кишечного тракта часто используется в качестве первого метода визуализации с высокой диагностической точностью в условиях острого живота, является оптимальной диагностической стратегией у молодых женщин из-за низкой лучевой нагрузки, в сравнении с рентгеном и компьютерной томографией. Врач может обследовать желудочно-кишечный тракт в зоне наибольшей болезненности с помощью ультразвука, получая, таким образом, больше информации и данных о патологии, чем при стандартном физикальном обследовании.

Ультразвуковое исследование кишечника в основном используется для диагностики и наблюдения за пациентами с воспалительными заболеваниями кишечника, что помогает избежать частого использования инвазивных и дорогостоящих диагностических процедур и приводит к раннему осуществлению подходящего лечения. Этот метод может служить для выявления других патологических состояний, присутствующих в желудочно-кишечном тракте. Это перспективный метод, обладающий высокой чувствительностью и специфичностью, преимуществом которого является легкая доступность, неинвазивность, безопасность, ввиду отсутствия ионизирующего излучения и потребности в использовании контрастных веществ. Преимущество данного метода заключается в сокращении диагностического поиска, что позволяет врачу сократить сроки установить диагноза и затраты пациента на дорогостоящие обследования.

### Introduction

Both low- and high-resolution transducers are required for a complete bowel examination. The method of scanning to assess the bowel may vary depending on the clinical problem: the

examination tactics, for example, will differ for abdominal trauma, suspected bowel obstruction or appendicitis and chronic complaints such as prolonged diarrhea. For surgical conditions, a more rapid targeted approach is used, whereas

for suspected chronic bowel pathology, a full systematic gastrointestinal scan is performed. There are no comparative studies comparing one method of gastrointestinal scanning with another, and these recommendations are largely a matter of expert opinion.<sup>1,2</sup>

#### **Pathological conditions.**

In intestinal ultrasound, the most frequent pathological findings are thickening of the intestinal wall, changes in the echo pattern of the intestinal wall, hyperaemia of the intestinal wall, decreased elasticity and peristalsis, hypertrophy of mesenteric fatty tissue, enlargement of lymph nodes and the presence of abdominal free fluid.<sup>3</sup>

#### **Appendicitis**

Acute appendicitis is one of the most frequent abdominal emergencies worldwide, with an incidence of approximately 100 per 100.000 person-years and a lifetime prevalence of 7-8%.<sup>3,4</sup>

Since several studies have demonstrated a marked reduction in the incidence of negative laparotomy findings when abdominal ultrasound is used preoperatively,<sup>4</sup> recent guidelines recommend the routine use of gastrointestinal ultrasound in every patient with suspected appendicitis.<sup>5</sup> Indeed, the sensitivity and specificity of bowel ultrasound performed by experienced professionals exceeds 90%, equivalent to computed tomography (CT) or magnetic resonance (MRI), with the advantage of wide availability, non-invasiveness and absence of ionising radiation.<sup>6</sup>

The role of bowel ultrasound in suspected acute appendicitis is to confirm the diagnosis or rule it out by demonstrating a normal appendix along its entire length, and to rule out an alternative cause of abdominal pain.<sup>5</sup> Moreover, bowel ultrasound can differentiate between uncomplicated and complicated appendicitis, as non-surgical treatment of uncomplicated appendicitis is recommended.<sup>6</sup>

In clinical practice, only a combination of various intestinal ultrasound findings allows the diagnosis of acute appendicitis. The detection of an appendix with thickened walls and hyperechogenic periappendicular tissue over the area of greatest pain are the most significant criteria in confirming the diagnosis, while mesenteric lymphadenopathy and color Doppler evaluation of the appendix are not specific signs and may be seen in a number of conditions.<sup>3</sup> (Case 1).

#### **Intestinal intussusception**

Intestinal intussusception occurs when one segment of intestine retracts into a neighboring segment of intestine, causing obstruction and even intestinal ischaemia.<sup>7</sup>

Intestinal intussusception is the leading cause of intestinal obstruction in children, but in adults it accounts for only 5% of

all intussusceptions and 0.003-0.02% of all adult hospitalizations. Unlike pediatric intussusception, which is idiopathic in 90% of cases, intussusception in adults has a distinct leading point that represents a well-defined pathological abnormality in 70-90% of cases.<sup>8</sup>

The symptoms of intussusception in adults are so nonspecific that a clinical diagnosis beyond intestinal obstruction is rarely made preoperatively.<sup>8</sup>

Ultrasonography is considered a useful tool for the diagnosis of intussusception in both children and adults.<sup>9</sup>

Classic ultrasonographic features include "target" or "donut" signs visible in transverse section and "pseudo-bulb" signs visible in longitudinal. Ultrasound has several disadvantages, two of which include masking of identifiable features by gas-filled bowel loops and operator dependence.<sup>7</sup>

The association between intestinal intussusception in adults and celiac disease has been described previously and has not yet been widely recognized.

Interestingly, a 2016 World Journal of Gastrointestinal Surgery article described intestinal intussusception as the initial manifestation of celiac disease in 57% of American adults.<sup>10</sup>

Intestinal intussusception in adults is a rare condition whose cause should be carefully investigated to expedite treatment and prevent unnecessary surgical intervention.<sup>11</sup>

In general, ultrasound has a sensitivity of 98-100% and specificity of 88-89% for the diagnosis of intestinal intussusception. Abdominal CT is currently considered the most sensitive radiological method to confirm intussusception with a diagnostic accuracy of 58-100%.<sup>12</sup> (Case 2).

#### **Intestinal obstruction**

Intestinal obstruction is a frequent cause of acute abdominal pain leading to hospitalization in the emergency department. Small intestinal obstruction accounts for approximately 80% of mechanical intestinal obstruction cases. Colonic obstruction is 4-5 times less common and in most cases is caused by colorectal tumours.<sup>3</sup>

The clinical presentation of intestinal obstruction depends on the localization and cause of the obstruction and often includes abdominal pain, nausea, vomiting, cessation of gas and/or stool discharge and abdominal bloating. Indeed, the clinical picture is non-specific and imaging is mandatory to confirm the diagnosis and distinguish between mechanical and functional small bowel obstruction, to determine the location and cause of obstruction, and to assess the risk of complications (bowel ischaemia) and the feasibility of non-surgical treatment (1).

Among the available imaging modalities, gastrointestinal ultrasound shows similar accuracy to CT (sensitivity 87%, specificity 81%) and higher than X-ray in detecting small bowel obstruction.<sup>13</sup>

Indeed, given its well-known advantages, ultrasound is recommended as the first screening method to detect the presence of intestinal obstruction.<sup>14</sup> Otherwise, the reliability of ultrasound for determining the location and cause of obstruction is lower than CT, so it may be appropriate to combine the two methods.<sup>15</sup>

Sonographic findings of bowel obstruction include dilated, fluid-filled loops of bowel with hyperechogenic patches of gas moving within the fluid. These dilated loops may have a thickened wall, usually up to 3 mm, thickened circumferential folds and increased "back and forth" movement of bowel contents.<sup>16</sup> (Case 3).

The aim of this review article is to present the current capabilities of transabdominal ultrasound in the evaluation of the most common and important surgical conditions in bowel pathology, and to present our own results of echographic imaging of the bowel.

#### Materials and methods

The recruitment of patients was carried out at the Research Institute of Cardiology and Internal Diseases, Department of Functional and Ultrasound Diagnostics. Patients (inpatient and outpatient) were sent on an accelerated basis for

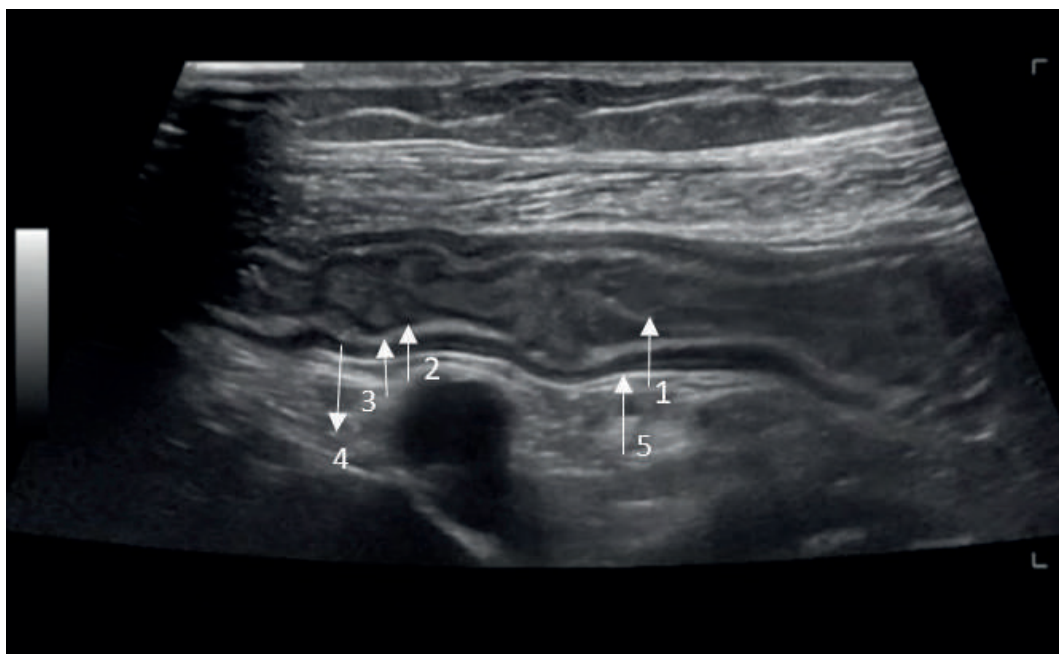
transabdominal ultrasound examination of the intestine with symptoms of acute abdominal pain against the background of chronic pathology of the gastrointestinal tract (2 patients with Crohn's disease and 1 with celiac disease).

The study was performed on an ultrasound device - Philips Affinity 70, manufactured in 2021.

During transabdominal ultrasound examination, a curvilinear low frequency probe was used to obtain a systematic scan of the intestine, then for a more detailed examination of the intestinal wall, the examination was carried out with a linear high-frequency probe.

*Ultrasound anatomy of the intestine.* Normally, the intestinal wall consists of five sonographic layers when examined with a high-frequency transducer (above 5 MHz). The sonographic layers do not exactly correspond to the histological layers, thus representing a combination of the interface echo signals of the histological layers. Starting from the lumen, the first layer (hyperechogenic) is the interface between the mucosa and the lumen, the second layer (hypoechoic) to the mucosa, the third layer (hyperechogenic) to the submucosa, the fourth layer (hypoechoic) to the muscularis and the fifth layer (hyperechogenic) to the echo interface between the muscularis and serosa.<sup>3</sup> (Figure 1).

**Figure 1.**  
Normal echogram of the small intestine. The image was obtained using a high-frequency linear transducer. 1 - superficial (boundary) echogenic layer; 2 - mucosa; 3 - submucosa; 4 - muscularis; 5 - serosa.

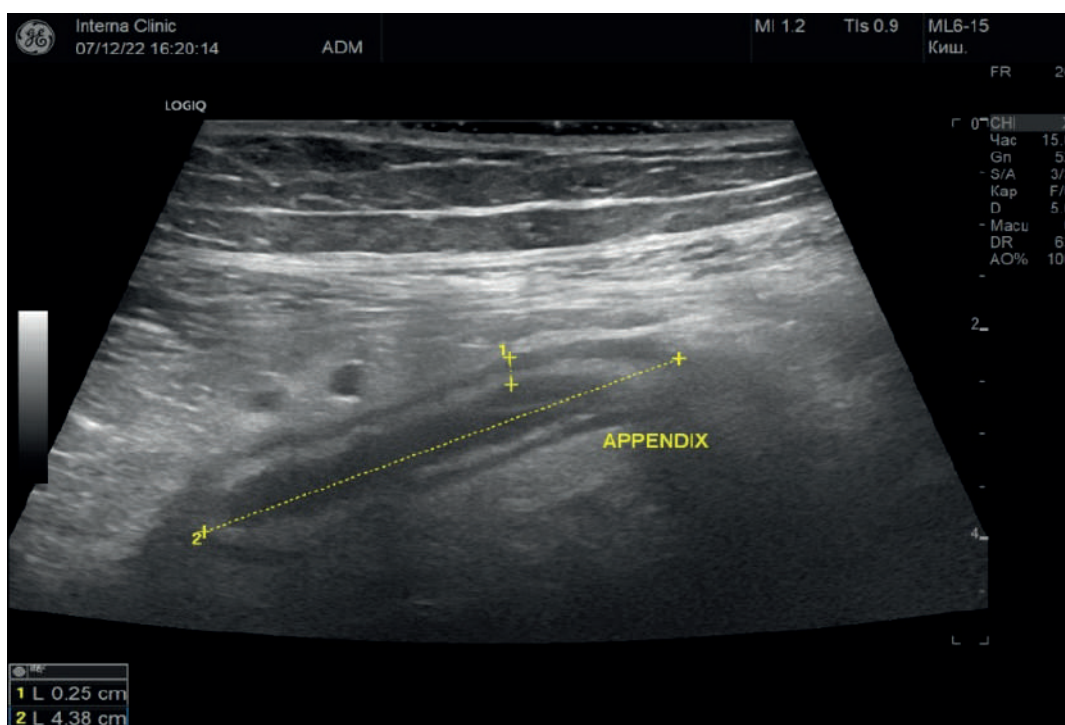


#### Case presentation 1

A patient with Crohn's disease in remission for a year complained of pain in the right iliac region. The general blood analysis revealed: leukocytosis, neutrophilosis, acceleration of erythrocyte sedimentation rate. An exacerbation

of Crohn's disease was suspected, in connection with which the patient was referred for intestinal ultrasound, which revealed signs of acute appendicitis and no evidence of Crohn's disease exacerbation (Figure 2).



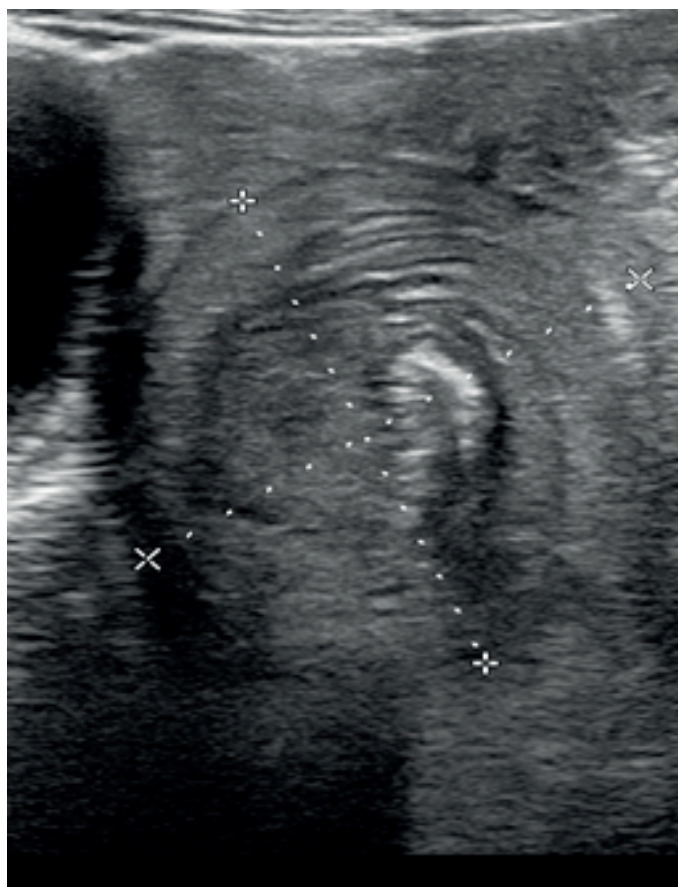

**Figure 2.** Longitudinal scan of the appendix showing thickened walls and hyperechoic periappendicular tissue (hypertrophy of mesenteric fat), tissue (hypertrophy of mesenteric fat); compression with the probe does not allows the lumen to contract, and this manoeuvre causes localized pain in the patient.

**Presentation case 2. Intestinal intussusception**

A 38-year-old female patient presented with complaints of liquid stools up to 2 times a day, without pathological impurities, abdominal

bloating and pain predominantly in the right iliac region, history of celiac disease for 6 years, without following a strict gluten-free diet (Figure 3).



**Figure 2.** Intussusception with typical appearance of concentric rings of thickened intestinal wall of different echogenicity "target symptom" was detected in the right iliac fossa.

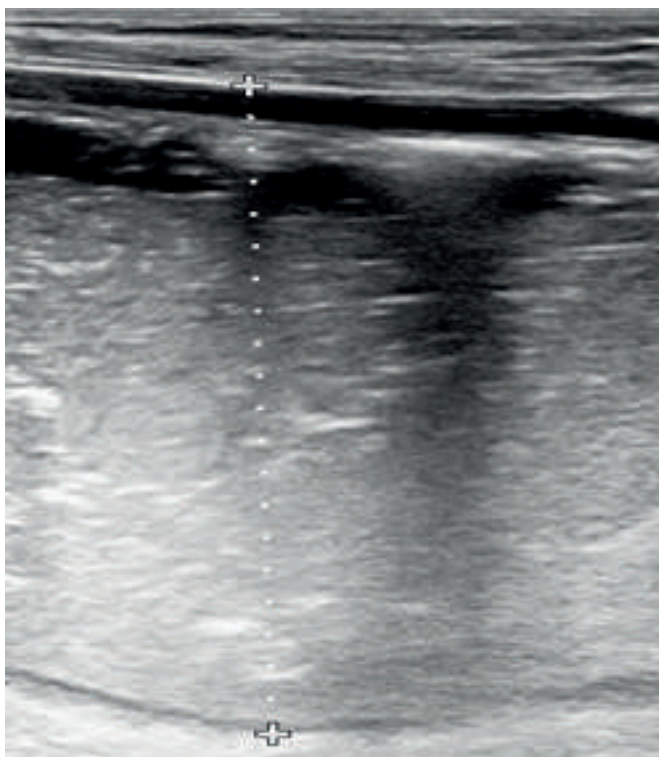
**Presentation case 3. Intestinal obstruction**

An 18-year-old female patient complained of abdominal pain after eating, vomiting after eating food, regular stools alternating with constipation for 3 days.

She was referred for intestinal ultrasound, which revealed signs of colonic obstruction (Figure 4), further confirmed by abdominal CT scan (Figure 5).

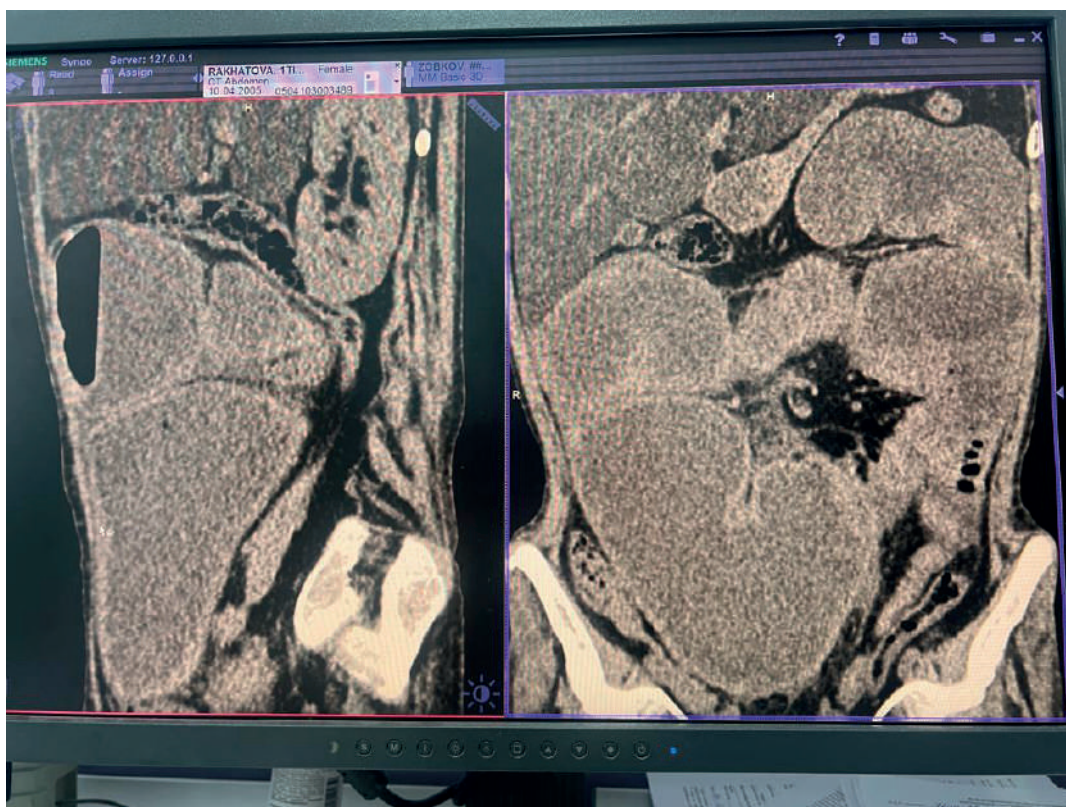
**Figure 4.**

In practically all parts of the abdominal cavity, dilated to d - 5.86 cm. loops of the colon are visualised, with a large amount of heterogeneous fluid content in the lumen, with sluggish pendulous peristalsis.



**Figure 5.**

CT image of the abdominal organs of this patient with signs of acute intestinal obstruction. Severely swollen loops of the large intestine with a fluid level are visualized.



### Conclusions

Intestinal ultrasound, allows the diagnosis of the vast majority of both acute and chronic intestinal pathologies. Sonography plays a vital role in the detection of acute gastrointestinal

pathology and should be used more frequently in daily clinical practice due to its accessibility, portability, cost-effectiveness and absence of ionising radiation.

### References

1. Smereczyński A, Kołaczyk K. Ultrasound diagnostics of bowel diseases in adults. *Paediatrics and Family Medicine*. 2015;11(2):157.
2. Nylund K, Maconi G, Hollerweger A, et al. EFSUMB recommendations and guidelines for gastrointestinal ultrasound-part 1: examination techniques and normal findings (long version). *Ultraschall in der Medizin-European Journal of Ultrasound*. 2017;38(03):e1-e15.
3. Boccacatonda A, D'Ardes D, Tallarico V, et al. Gastrointestinal Ultrasound in Emergency Setting. *J Clin Med*. Jan 19 2023;12(3) doi:10.3390/jcm12030799
4. Lahaye MJ, Lambregts DM, Mutsaers E, et al. Mandatory imaging cuts costs and reduces the rate of unnecessary surgeries in the diagnostic work-up of patients suspected of having appendicitis. *Eur Radiol*. May 2015;25(5):1464-70. doi:10.1007/s00330-014-3531-0
5. Dirks K, Calabrese E, Dietrich CF, et al. EFSUMB Position Paper: Recommendations for Gastrointestinal Ultrasound (GIUS) in Acute Appendicitis and Diverticulitis. *Ultraschall Med*. Apr 2019;40(2):163-175. doi:10.1055/a-0824-6952
6. Zhang H, Liao M, Chen J, Zhu D, Byanju S. Ultrasound, computed tomography or magnetic resonance imaging-which is preferred for acute appendicitis in children? A Meta-analysis. *Pediatric radiology*. 2017;47:186-196.
7. StatPearls. 2023.
8. Yakan S, Caliskan C, Makay O, Denecli AG, Korkut MA. Intussusception in adults: clinical characteristics, diagnosis and operative strategies. *World J Gastroenterol*. Apr 28 2009;15(16):1985-9. doi:10.3748/wjg.15.1985
9. Marinis A, Yiallourou A, Samanides L, et al. Intussusception of the bowel in adults: a review. *World J Gastroenterol*. Jan 28 2009;15(4):407-11. doi:10.3748/wjg.15.407
10. Paul C, Anderson S. The Correlation Between Pediatric Intussusceptions and Celiac Disease. *Journal of Diagnostic Medical Sonography*. 2019;35(5):419-424.
11. AlAhmad M, Almessabi A. Transient Small-Bowel Intussusception Unmasking Adult Celiac Disease. *Case Rep Gastroenterol*. 2022;16(1):44-48. doi:10.1159/000521542
12. Akbulut S. Intussusception due to inflammatory fibroid polyp: a case report and comprehensive literature review. *World J Gastroenterol*. Oct 28 2012;18(40):5745-52. doi:10.3748/wjg.v18.i40.5745
13. Gottlieb M, Peksa GD, Pandurangadu AV, Nakitende D, Takhar S, Seethala RR. Utilization of ultrasound for the evaluation of small bowel obstruction: A systematic review and meta-analysis. *Am J Emerg Med*. Feb 2018;36(2):234-242. doi:10.1016/j.ajem.2017.07.085
14. Hollerweger A, Maconi G, Ripolles T, et al. Gastrointestinal Ultrasound (GIUS) in Intestinal Emergencies-An EFSUMB Position Paper. *Ultraschall Med*. Dec 2020;41(6):646-657. doi:10.1055/a-1147-1295
15. Hollerweger A, Wüstner M, Dirks K. Bowel Obstruction: Sonographic Evaluation. *Ultraschall Med*. Jun 2015;36(3):216-35; quiz 236-8. doi:10.1055/s-0034-1399292
16. Hefny AF, Corr P, Abu-Zidan FM. The role of ultrasound in the management of intestinal obstruction. *J Emerg Trauma Shock*. Jan 2012;5(1):84-6. doi:10.4103/0974-2700.93109

<https://doi.org/10.35805/BSK2023IV006>

Kudabaeva I.D.<sup>1</sup>

<https://orcid.org/0009-0002-2328-9778>

Sadykov S.J.<sup>1</sup>

<https://orcid.org/0009-0008-5337-1047>

Zhakybaeva A.N.<sup>2</sup>

<http://orcid.org/0009-0008-8597-3026>

# CLINICAL CASE OF LASER ABLATION OF LINGUAL AMYGDALA

Kudabaeva I.D.<sup>1</sup>, Sadykov S.J.<sup>1</sup>, Zhakybaeva A.N.<sup>2</sup>

**For correspondence:**  
Kudabaeva I.D. – assistant of the department of otorhinolaryngology of S.D. Asfendiyarov KazNMU, otorhinolaryngologist, Center of Modern Medicine “Mediterra” Institute of Surgery LLP, Almaty, Kazakhstan, e-mail: [indira65512@gmail.com](mailto:indira65512@gmail.com)

<sup>1</sup>Center of Modern Medicine “Mediterra” Institute of Surgery LLP,, Almaty, Kazakhstan,

<sup>2</sup>Kazakh National Medical University named after S.D. Asfendiyarov, Almaty, Kazakhstan

## Conflict of interest:

The authors declare that they have no conflicts of interest

## Keywords:

hypertrophy of the lingual tonsil, laser ablation of the tonsils, laryngoscopy.

## Abstract

*Hypertrophy of the lingual tonsil is a condition in which the lingual tonsil, located at the base of the tongue, enlarges. This tonsil consists of clusters of follicles separated by a central groove. In children under 5 years old, the number of follicles usually ranges from 10 to 12, while in adults up to 40 years old, it can reach 35 to 40. This structure plays an important role in the immune system, helping the body fight infections and microbes. Like other tonsils in the throat, the lingual tonsil can sometimes cause problems, such as hypertrophy (enlargement) or chronic infections.*

*The causes of lingual tonsil hypertrophy can be diverse. In some cases, it develops as a compensatory process after the removal of the palatine tonsils. The primary cause in adults may be chronic inflammation of the pharynx.*

*Severe degrees of lingual tonsil hypertrophy are very rare but can lead to various symptoms, such as coughing, difficulty swallowing and breathing, a feeling of pressure in the area beneath the tongue, and other nonspecific complaints. These symptoms are not pathognomonic for lingual tonsil hypertrophy. The challenges in diagnosis and the lack of a standardized approach to surgical treatment require detailed consideration and description in each individual case. Sometimes, patients with lingual tonsil hypertrophy complain of coughing paroxysms. In such cases, mechanical irritation of the lingual tonsil with a probe can provide some assistance in diagnosis.*

*In the context of this study, lingual tonsillectomy surgery was performed on a patient using a diode laser. The results obtained confirmed the high level of technological feasibility and appropriateness of using laser ablation for the treatment of lingual tonsil hypertrophy. Laser ablation is one of the possible surgical procedures for treating lingual tonsil hypertrophy. It can be an effective and technologically advanced method, although it requires experience and qualification of specialists.*

## Тіл бадамшаларының лазерлі абляциясының клиникалық көрінісі

Кудабаева И.Д.<sup>1</sup>, Садыков С.Ж.<sup>1</sup>, Жақыбаева А.Н.<sup>2</sup>

Хат алысатын автор:

Кудабаева И. Д. –

С. Д. Асфендияров атындағы ҚазҰМУ оториноларингология кафедрасының ассистенті, оториноларинголог, “Mediterra” ЖШС қазіргі заманғы медицина орталығы хирургия институты, Алматы, Қазақстан, e-mail: [indira65512@gmail.com](mailto:indira65512@gmail.com)

<sup>1</sup>Заманауи медицина орталығы «Медитерра»

«Хирургия институты» ЖШС, Алматы, Қазақстан,

<sup>2</sup>С.Ж. Асфендияров атындағы Қазақ Ұлттық медициналық университеті, Алматы, Қазақстан

## Түйіндеме

Тілдік бадамша безінің гипертрофиясы-бұл тілдің тамырында орналасқан тілдік бадамша безінің мөлшерінен ұлғаятын жағдай. Бұл бадамша без орталық жұлгемен бөлінген фолликулалардың шоғырларынан тұрады. 5 жасқа дейінгі балаларда фолликулалардың саны әдетте 10-12 құрайды, ал 40 жасқа дейінгі ересектерде олардың саны 35-40-қа жетуі мүмкін. Бұл құрылым иммундық жүйеде маңызды рөл атқарады, ағзаға инфекция және микробтармен күресуге көмектеседі. Тамақтағы басқа бадамша бездер сияқты, тілдік тонзилла кейде гипертрофия (мөлшерінен тыс ұлғаюы) немесе созылмалы инфекциялар сияқты проблемаларды тудыруы мүмкін.

Тіл бадамша безінің гипертрофиясының себептері әртүрлі болуы мүмкін. Кейбір жағдайларда ол таңдай бадамша бездерін алып тастағаннан кейін компенсаторлық процесс ретінде дамиды. Ересектердің негізгі себебі тамақ-жұтқыншақ созылмалы қабынуы болуы мүмкін. Тіл бадамша

безінің гипертрофиясы өте сирек кездеседі, бірақ әртүрлі белгілерді тудыруы мүмкін, мысалы, жөтел, жұтынудың және тыныс алудың қиындауы, тіл асты сүйегі аймағындағы қысым сезімі және басқа да спецификалық емес шағымдар сияқты әртүрлі белгілерді тудыруы мүмкін.

Бұл шағымдар тіл бадамша безінің гипертрофиясы үшін патогномоникалық емес. Диагностиканың қиындықтары және хирургиялық емдеудің бірыңғай тәсілінің болмауы әр жағдайда егжей-тегжейлі қарастыруды және сипаттауды қажет етеді. Кейде тілдік бадамша безінің гипертрофиясы бар науқастар жөтел пароксизміне шағымданады. Мұндай жағдайларда диагностикада арнайы зондтың көмегімен тілдік бадамша безін механикалық тітіркендіру арқылы тексеруге болады.

Осы зерттеу аясында диодты лазерді қолдана отырып, науқаста тілдік бадамша безінің тонзиллотомия операциясы жасалды. Нәтижелер тіл бадамша безінің гипертрофиясын емдеу үшін лазерлік абляцияны қолданудың жоғары технологиялық деңгейі мен орындылығын растады. Лазерлік абляция-тіл бадамша безінің гипертрофиясын емдеудің хирургиялық процедураларының бірі. Бұл тиімді және технологиялық әдіс болуы мүмкін, бірақ ол мамандардың тәжірибесі мен біліктілігін қажет етеді.

**Мүдделер қақтығысы:**  
Авторлар мүдделер қақтығысының жоқтығын мәлімдейді

**Түйінді сөздер:**  
тіл бадамша безінің гипертрофиясы, бадамша бездердің лазерлік абляциясы, ларингоскопия.

## Клинический случай лазерной абляции язычной миндалины

Кудабаева И.Д.<sup>1</sup>, Садыков С.Ж.<sup>1</sup>, Жақыбаева А.Н.<sup>2</sup>

<sup>1</sup>Центр современной медицины “Mediterra” ТОО “Институт хирургии”, Алматы, Казахстан,

<sup>2</sup>Казахский Национальный медицинский университет имени С.Д. Асфендиярова, Алматы, Казахстан

**Автор для корреспонденции:**  
Кудабаева И.Д. – ассистент кафедры оториноларингологии КазНМУ им. С.Д. Асфендиярова, оториноларинголог, Центр современной медицины ТОО “Mediterra” Институт хирургии, Алматы, Казахстан, e-mail: indira65512@gmail.com

### Аннотация

Гипертрофия язычной миндалины – это состояние, при котором язычная миндалина, расположенная у корня языка, увеличивается в размерах. Эта миндалина состоит из скоплений фолликулов, разделенных центральной бороздой. У детей моложе 5 лет количество фолликулов обычно составляет 10-12, а у взрослых до 40 лет их количество может достигать 35-40. Эта структура играет важную роль в иммунной системе, помогая организму бороться с инфекциями и микробами. Подобно другим миндалинам в горле, язычная миндалина может иногда вызывать проблемы, такие как гипертрофия (увеличение размеров) или хронические инфекции. Причины гипертрофии язычной миндалины могут быть разнообразными. В некоторых случаях она развивается как компенсаторный процесс после удаления небных миндалин. Основной причиной взрослых может быть хроническое воспаление ротоглотки. Выраженная степень гипертрофии язычной миндалины встречается очень редко, но может вызывать разнообразные симптомы, такие как кашель, затруднение глотания и дыхания, ощущение давления в области подъязычной кости и другие неспецифические жалобы. Эти жалобы не являются патогномоничными для гипертрофии язычной миндалины. Трудности диагностики и отсутствие единого подхода к хирургическому лечению требует детального рассмотрения и описания в каждом отдельном случае. Иногда больные с гипертрофией язычных миндалин жалуются на пароксизмы кашля. В таких случаях определенную помощь в диагностике может оказать механическое раздражение язычной миндалины при помощи зонда.

В рамках данного исследования была проведена операция тонзиллотомия язычной миндалины у пациентки с применением диодного лазера. Полученные результаты подтвердили высокий уровень технологичности и целесообразности применения лазерной абляции для лечения гипертрофии язычной миндалины. Лазерная абляция – одна из возможных хирургических процедур для лечения гипертрофии язычной миндалины. Она может быть эффективной и технологичной методикой, хотя требует опыта и квалификации специалистов.

**Конфликт интересов:**  
Авторы заявляют об отсутствии конфликта интересов

**Ключевые слова:**  
гипертрофия язычной миндалины, лазерная абляция миндалин, ларингоскопия.

### Introduction

The lingual amygdala hypertrophy is a condition marked by the enlargement of the lingual amygdala. This can lead to symptoms such as breathlessness during inhalation, discomfort in the throat, coughing, difficulty in swallowing, which can be mistaken for

pharyngitis. Additionally, it can result in pathological snoring, breathing interruptions during sleep, and impact the development of systemic infections.<sup>1,2</sup> The diagnosis of left tonsil (LT) hypertrophy was determined through a comprehensive evaluation by an ear, nose, and throat (ENT) specialist. This evaluation included

a flexible endoscopy, followed by an MRI scan, and ultimately confirmed through drug-induced sleep endoscopy.<sup>2,3</sup>

The prevalence of lingual amygdala disorders is notably higher than their diagnosis rate. This is attributed to its location within the less visible portion of the larynx, as well as the absence of a standardized examination protocol for patients. Limited research exists on the function, diagnosis, and treatment of hyperplastic processes in the root of the tongue. Surgical procedures in this region are often discouraged due to bleeding risks and accessibility concerns. [1-8].

Diseases that affect the lingual tonsils are often not given much attention in both clinical practice and medical literature. Infections of the lingual tonsils are usually treated with medications. However, when patients have chronic inflammation or significant enlargement of the lingual tonsils with troublesome symptoms, surgical intervention may be necessary. Laser

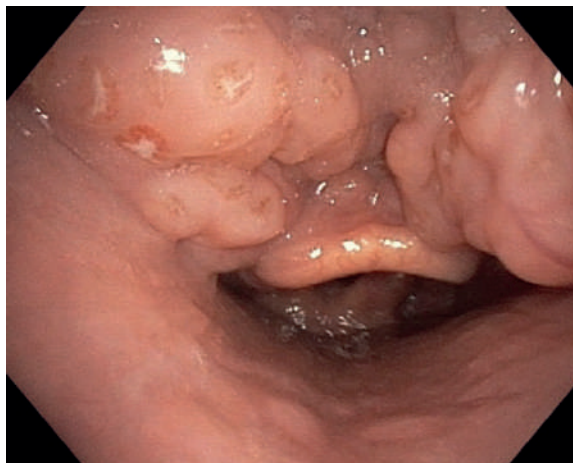
surgery has proven to be an effective method for treating benign overgrowth and inflammatory conditions of the lingual tonsils.[4].

Conventional surgical removal of the lingual amygdala has given way to more advanced methods. Contemporary approaches include electrocauterization for cauterizing amygdala growth [8], cryoexposure [6], laser resection of hypertrophied amygdala tissues [5-7], and coblation using a cold-plasma emitter for the tongue root area [9].

#### Case presentation

A videolaryngoscopy was performed on a 37-year-old female patient with dyspnoea complaints, nocturnal apnoea attacks disturbing for 1 year (Figure 1). Examination revealed hypertrophy of lingual amygdala. 6 years ago, a tonsillectomy of the palatine tonsils was performed, which probably caused hypertrophy of the lingual tonsillum

Figure 1.  
Videolaryngoscopy prior to surgery



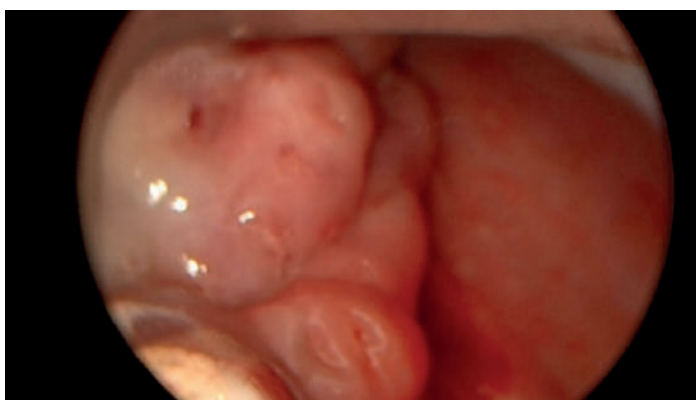Based on this examination, a clinical diagnosis of hypertrophy of the lingual amygdala was made and it was decided to perform an operation - ablation of the lingual amygdala using the LAKHTA-MILON diode laser.

The operation was performed under endotracheal anesthesia, by direct laryngoscopy under the video control of rigid endoscope 00

(Figure 2).

The lingual amygdala was ablated with a diode laser at a power of 10 W with a light guide with a cylindrical diffuser (Figure 3). As a result, there is a significant reduction in the size of the lingual amygdala. There was no bleeding during the operation.

Figure 2.  
Hypertrophied lingual amygdala in  
direct laryngoscopy.



On the second day after the operation, the patient noted that the attacks of shortness of breath had passed, complained of a feeling of numbness of the tongue and pain in the throat of a moderate nature.

She was in the hospital for 3 days, received dexamethasone for three days, at a dose of 12 mg, followed by outpatient administration of dexamethasone at a dose of 6 mg for three days.

No antibacterial therapy was performed.

A follow-up examination was performed 4 weeks after surgery (Figure 4). There were no complaints at the time of the follow-up examination, there were no bouts of shortness of breath and no nocturnal apnea. There is a significant reduction in the size of the lingual amygdala.

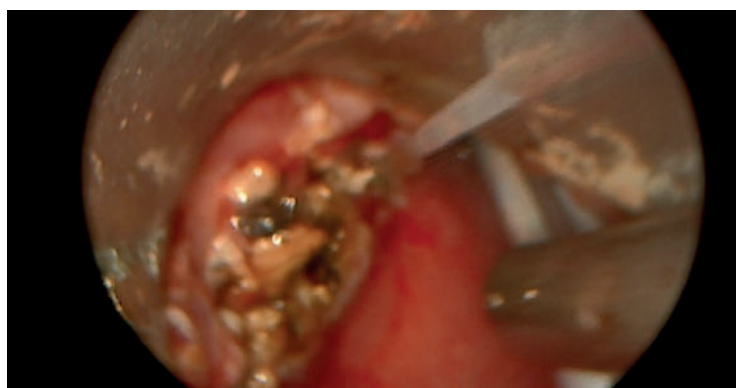

Figure 3.  
The appearance of the lingual amygdala immediately after laser ablation

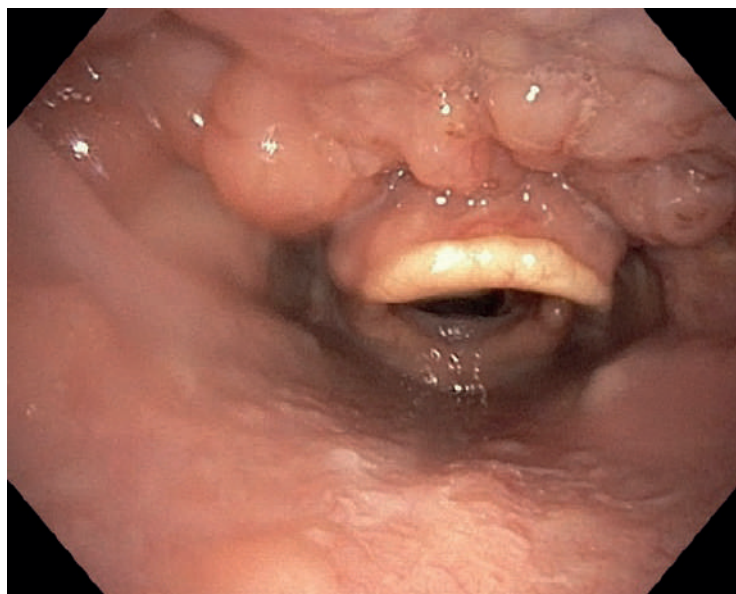


Figure 4.  
Videolaryngoscopy 4 weeks after surgery

### Discussion

The case presented highlights the clinical significance of lingual amygdala hypertrophy and the efficacy of laser ablation as a treatment method. Here, we delve into key points for discussion: Lingual amygdala hypertrophy can result in considerable distress for patients, causing symptoms like shortness of breath and nocturnal apnea. Its impact on sleep quality and overall well-being underscores its clinical importance [1]. The diagnosis of lingual amygdala hypertrophy is often complex due to its location within the larynx. The comprehensive approach involving videolaryngoscopy proved crucial in identifying the condition. The challenge lies in the fact that many cases may go

undiagnosed or misdiagnosed, contributing to the underestimation of its prevalence [3]. Surgical intervention for lingual amygdala hypertrophy has evolved over time. While conventional surgery was associated with bleeding risks and accessibility concerns, advanced methods such as laser ablation have emerged as effective alternatives. The discussion can revolve around the advantages and disadvantages of various surgical approaches, including laser ablation, electrocauterization, cryoexposure, and coblation [5-9]. The patient's postoperative experience, including the relief from shortness of breath and associated side effects like tongue numbness and throat pain, raises questions about the postoperative management and potential

complications. Further research into optimizing recovery and minimizing side effects is essential. The lack of standardized examination protocols and limited research on lingual amygdala hypertrophy underscores the need for more studies in this field. Understanding the etiology, prevalence, and optimal treatment strategies is vital for improving patient care.

The positive outcomes observed in this case highlight the potential benefits of laser ablation as a treatment modality. A larger study group and longer-term follow-up could provide more insights into the efficacy and safety of this approach.

Thus, lingual amygdala hypertrophy is a condition that can have a significant impact on a patient's quality of life, and its diagnosis and treatment require careful consideration. The case presented here sheds light on the

successful use of laser ablation as a surgical method, emphasizing the importance of continued research and discussion in this area of otorhinolaryngology and somnology.

#### Conclusions

Thus, the problem of hypertrophy of the lingual amygdala occupies an important place in otorhinolaryngology and somnology, as it causes such problems as attacks of shortness of breath and nocturnal apnea [1]. A comprehensive, thorough approach to diagnosis using videolaryngoscopy allows you to detect hypertrophy of the lingual amygdala and prevent possible complications. Laser application for operative treatment of hypertrophy of lingual amygdala allows to avoid bleeding at reduction of amygdala and to accelerate period of convalescence.

### References

---

1. Leyzerman M, Grishunina O. Radiofrequency Reduction and Resection of Hypertrophic Lingual Tonsils.
2. Babiyak V, Govorun M. Nakatis Ya. *Clinical otorhinolaryngology: a guide for doctors St Petersburg: Hippocrates.* 2005;
3. Mure C, Blumen M, Alali A, Page L, Chabolle F. Surgical ablation of lingual tonsils in the treatment of obstructive sleep apnea. *Eur Ann Otorhinolaryngol Head Neck Dis.* Feb 2019;136(1):19-23. doi:10.1016/j.anorl.2018.11.001
4. Bock JM, Trask DK. Coblation-assisted lingual tonsillectomy for dysphagia secondary to tongue base hypertrophy. *Ann Otol Rhinol Laryngol.* Jul 2008;117(7):506-9. doi:10.1177/000348940811700706
5. Maturo SC, Mair EA. Coblation lingual tonsillectomy. *Otolaryngology—Head and Neck Surgery.* 2006;135(3):487-488.



# К 90-летию профессора Кукеева Т.К.



Турар Койшигараевич Кукеев родился в селе Ушарал Таласского района Жамбылской области 15 декабря 1933 года. В 1952 году по окончании семи классов, с отличием закончил медицинское училище в г. Тараз и вне конкурса был зачислен на 1 курс лечебный факультет Казахского Государственного Медицинского института в г. Алматы, который закончил с отличием в 1958 году. Лидерские качества, отличная учеба были залогом того, что начиная со 2 курса Т.К.Кукеев стал Сталинским стипендиатом, членом комитета комсомола ВУЗа. После окончания медицинского института, с отличием, в 1958 году он был направлен заместителем главного врача в Таласскую районную больницу Жамбылской области, где совмещал эту работу с работой практического врача-хирурга. Профессор Брякин М.И. пригласил своего выпускника для поступления в аспирантуру по конкурсу на кафедру госпитальной хирургии КазМИ

Поступил в аспирантуру на кафедру своего учителя, аспирант Кукеев Т.К. досрочно написал и защитил диссертацию на соискание ученой степени кандидата медицинских наук, которая вскоре была подтверждена ВАКом СССР. С этого времени вся трудовая и научно-педагогическая деятельность Т.К.Кукеева неразрывно была связана с кафедрой госпитальной хирургии, где он прошел все ступени формирования его, как ученого: аспиранта, ассистента кафедры, доцента кафедры и профессора кафедры, в последующем, по рекомендации своего учителя профессора Брякина М.И. стал заведующим кафедрой госпитальной хирургии с 1979 года.

Вместе со своим учителем профессором М.И.Брякиным, Т.К.Кукеев является одним из пионеров

развития и становления сосудистой хирургии в Казахстане на научной основе. Под руководством М.И.Брякина, Т.К.Кукеевым в Казахстане с 1965 года стали выполняться реконструктивно-восстановительные операции при окклюзионных заболеваниях артерий нижних конечностей: аорто-бедренное и подвздошно-бедренное шунтирование, аллопротезирование, резекция окклюзированного сегмента артерии с пластикой аутовеной и аллопротезом. Он внедрил в широкую практику такие сложные операции на кровеносных сосудах, как: резекция травматической аневризмы бедренной артерии с аутовенозной пластикой, операции при сложных гемангиомах бедра, ягодичной области, ранениях подвздошной и бедренной артерий, операция тромбинимэктомии и эндартерэктомии при стенозирующих заболеваниях сосудов, операции при ПТФС.

При облитерирующем эндартериите Т.К.Кукеев стал широко, впервые в Республике, применять поясничную и грудную симпатэктомию. Им опубликованы ряд наблюдений успешной антикоагулянтной и фибринолитической терапии при тяжелых илеофemorальных флеботромбозах и синдроме Педжета-Шреттера и продолжительной ремиссии при болезни Бюргера.

Впервые в Казахстане Т.К.Кукеевым в 1967 году, вместе с профессором Брякиным, доцентом Г.Н.Андреевым выполнена операция наложения спленоренального анастомоза при портальной гипертензии. Благодаря активной деятельности внедрены сложные ангиографические исследования: транслюмбальная аортография, артериография, восходящая и нисходящая флебография, диагностическая и лечебная лимфография для устранения последствий рожистого воспаления конечности.

Работая на кафедре госпитальной хирургии с 1958 года, Т.К.Кукеев внес неоценимый вклад в подготовке практических хирургов через субординатуру и интернатуру. Он является одним из первых организаторов интернатуры в РК, и руководителей хирургической интернатуры в АГМИ.

Профессор Т.К.Кукеев был в числе пионеров внедрения преподавания и издания учебных пособий по хирургии на государственном языке. Им подготовлены и изданы на государственном языке «Избранные лекции по госпитальной хирургии», также он был соавтором трех учебников по хирургии для 5 и 6 курсов, двух монографий, 15 учебно-методических пособий.

Активная врачебная и научно-педагогическая деятельность Кукеева Т.К. была по достоинству, высоко оценена Родиной. За заслуги в области хирургии Т.К.Кукеев в 1970 году Минздравом СССР награжден нагрудным знаком «Отличник здравоохранения СССР». В 1981 году указом Президиума Верховного Совета Казахской ССР Турару Койшигараевичу Кукееву присвоено почетное звание «Заслуженный работник Высшей школы Казахской ССР».

За особые заслуги в учебно-педагогической деятельности АГМИ, вклад в развитие и становление

ангиохирургии в Казахстане доценту Т.К.Кукееву, в 1994 г. решением ВАК РК было присвоено звание «Профессора медицины».

За особые заслуги в организации и развитии неотложной, плановой сосудистой хирургии, подготовки хирургических кадров в РК он, решением Ученого совета НЦХ им. А.Н.Сызганова, в 1997 году избран «Почетным профессором» Национального Научного Центра Хирургии им. А.Н.Сызганова» Республики Казахстан.

В 2002 году, общественность, администрация Жамбылской области с чувством глубокой признательности за развитие хирургической службы и в связи с 2000-летием г.Тараза, избрала профессора Т.К.Кукеева «Почетным гражданином Жамбылской области», а в 2013 г. он избран «Почетным гражданином Алма – Атинской области»

В 2011 году, на очередном Международном конгрессе хирургов Республики Казахстан, профессор Т.К.Кукеев стал обладателем Золотой медали Национального центра хирургии имени академика А.Н.Сызганова, также стал обладателем золотой медали «Алтын Дәрігер»

Национальной Ассоциации врачей и провизоров РК в 2012 году, награжден высшей наградой МОН РК - медалью «Ыбырай Алтынсарина», был избран Академиком общественной академии им. Куртка Табиба, а в 2013 году Т.К. Кукеев избран «Почетным профессором Каз НМУ им. С.Д. Асфендиярова»

Профессор Т.К. Кукеев скоропостижно ушел из жизни 31 декабря 2016 г.

Медицинская наука, хирургия понесла невосполнимую утрату.

В честь профессора Кукеева Т.К. и признания его заслуг перед народом Казахстана КазНМУ им. Асфендиярова присвоило одной из учебных аудиторий его имя.

Свой богатый, жизненный опыт, практику поливалентного хирурга, педагогический талант и энергию профессор Т.К. Кукеев отдавал своему важнейшему долгу жизни – подготовке научно-практических хирургов и врачебных кадров для РК.

**Профессор А.С. Ибадильдин**