

www.vhk.kz



А.Н.Сызғанов
атындағы
ҰЛТТЫҚ
ҒЫЛЫМИ ХИРУРГИЯ
ОРТАЛЫҒЫ



А.Н. Сызғанов атындағы Ұлттық ғылыми хирургия орталығы
Национальный научный центр хирургии им. А.Н. Сызганова
Syzganov National Scientific Center of Surgery

№4 (81) 2024

BULLETIN OF SURGERY IN KAZAKHSTAN

ISSN 2306-5559 (print)
ISSN 2410-938X (online)

ISSN 2306-5559 (print)
ISSN 2410-938X (online)

www.vhk.kz



№4 (81) 2024

BULLETIN OF SURGERY IN KAZAKHSTAN

АЛМАТЫ /ALMATY

әр тоқсанда шығып тұратын А.Н. Сызғанов атындағы Ұлттық ғылыми хирургия орталығының ғылыми-тәжірибелік журналы
ежеквартальный научно-практический журнал Национального научного центра хирургии им. А.Н. Сызғанова
a quarterly scientific-practical journal of the «Syzganov National Scientific Center of Surgery»

БАС РЕДАКТОР

Баймаханов Б.Б.,

«А.Н. Сызғанов атындағы Ұлттық ғылыми хирургия орталығы» АҚ Басқарма Төрағасы, м.ғ.д., профессор, ҚР ҰҒА академигі

БАС РЕДАКТОРДЫҢ ОРЫНБАСАРЫҒ, PhD

Қаниев Шокан

ЖАУАПТЫ ХАТШЫ, М.Ғ.К., ПРОФЕССОР

Исмаилова Г.Н.

РЕДАКЦИЯ АЛҚАСЫ

Баймаханов Ж.Б., PhD, профессор
Нерсесов А.В., м.ғ.д., профессор
Досханов М.О., PhD
Сұлтаналиев Т.А., м.ғ.д., профессор
Байымбетов А.Қ., PhD, профессор
Бөлегенов Т.А., м.ғ.д.
Миербеков Е.М., м.ғ.д., профессор
Жураев Ш.Ш., м.ғ.д., профессор
Исмаилова Г.Н., м.ғ.к., профессор
Мутагиров В.В., м.ғ.к.
Ширтаев Б.Қ., м.ғ.к.
Мурадов М.И., м.ғ.к., профессор
Баймаханов А.Н., м.ғ.к.

РЕДАКЦИЯ КЕҢЕСІ

Susumu Eguchi (Жапония)
Wojciech Polak (Голландия)
Remzi Emiroglu (Туркия)
Bulent Oktay (Туркия)
Tamer Turan (Туркия)
Subhash Gupta (Индия)
Jeong Tea Kim (Корея)
Владимир Вишнеvский (Ресей)
Иван Стилиди (Ресей)
Олег Руммо (Беларусь)
Hannu Kuokkanen (Финляндия)
Ho-Seong Han (Корея)
Mehmet Haberal (Туркия)
Дильгам Магеррамов (Әзірбайжан)

Журнал ҚР ақпарат, мәдениет және спорт
Министрлігінде тіркелген.
Журнал ҚР ҒБМ Ғылым және білім саласындағы
бақылау комитеті ұсынған Ғылыми еңбектің
негізгі нәтижелерін жариялау үшін ұсынатын
ғылыми баспалар тізбесі енгізілген.

Тіркеу нөмірі 5564-Ж.

Журналдың иесі – «А.Н. Сызғанов атындағы
Ұлттық ғылыми хирургия орталығы» АҚ.

Баспаның мекен-жайы:

050004, Алматы қ., Желтоқсан көш. 62,
тел. +7(727) 2795306

http://vhk.kz, e-mail: dr.gismailova@gmail.com

Әрленім және беттеу:

«Старков С.А.» ЖК

Көкшетау қ., Әуелбеков к., 98

Тапсырыс №634
Таралымы - 500 дана

Жарияланатын мақалалардың мазмұнына
авторлар жауапты.

ҚАЗПОЧТА жазылу индексі – 75327

ГЛАВНЫЙ РЕДАКТОР

Баймаханов Б.Б.,

Председатель правления АО «Национальный научный
центр хирургии им. А. Н. Сызғанова», д.м.н.,
профессор, академик НАН РК

ЗАМЕСТИТЕЛЬ ГЛАВНОГО РЕДАКТОРА, PhD

Қаниев Шокан

ОТВЕТСТВЕННЫЙ СЕКРЕТАРЬ, К.М.Н., ПРОФЕССОР

Исмаилова Г.Н.

РЕДАКЦИОННАЯ КОЛЛЕГИЯ

Баймаханов Ж.Б., PhD, профессор
Нерсесов А.В., д.м.н., профессор
Досханов М.О., PhD
Сұлтаналиев Т.А., д.м.н., профессор;
Байымбетов А.Қ., PhD, профессор;
Бөлегенов Т.А., д.м.н., доцент;
Миербеков Е.М., д.м.н., профессор;
Жураев Ш.Ш., д.м.н., профессор;
Исмаилова Г.Н., к.м.н., профессор;
Мутагиров В.В., к.м.н.;
Ширтаев Б.Қ., к.м.н.;
Мурадов М.И., к.м.н., профессор;
Баймаханов А.Н., к.м.н

РЕДАКЦИОННЫЙ СОВЕТ

Susumu Eguchi (Япония)
Wojciech Polak (Голландия)
Remzi Emiroglu (Турция)
Bulent Oktay (Турция)
Tamer Turan (Турция)
Subhash Gupta (Индия)
Jeong Tea Kim (Корея)
Владимир Вишнеvский (Россия)
Иван Стилиди (Россия)
Олег Руммо (Беларусь)
Hannu Kuokkanen (Финляндия)
Ho-Seong Han (Корея)
Mehmet Haberal (Турция)
Дильгам Магеррамов (Азербайджан)

Журнал зарегистрирован в Министерстве
информации, культуры и спорта РК.
Журнал включен в перечень научных
изданий, рекомендуемых Комитетом
по контролю в сфере образования и науки
МОН РК

Регистрационный номер: 5564-Ж.

Владелец журнала – АО «Национальный научный
центр хирургии имени А.Н. Сызғанова».

Адрес редакции:

050004, г. Алматы, ул. Желтоқсан, 62,
тел. +7 (727) 2795306

http://vhk.kz, e-mail: dr.gismailova@gmail.com

Дизайн и верстка:

ИП «Старков С.А.»

г. Кокшетау, ул. Ауелбекова, 98

Заказ 634
Тираж - 500 экз.

Ответственность за содержание
публикуемых материалов несут авторы.

Подписной индекс КАЗПОЧТЫ – 75327

EDITOR IN CHIEF

Baimakhanov B. B.,

Chairman of the Board of «Syzganov National
Scientific Center of Surgery» JSC, D.Med.Sc.,
professor, academician of NAS RK

DEPUTY CHIEF EDITOR, PhD

Kaniyev Shokan

EXECUTIVE SECRETARY, C.M.S., PROFESSOR

Ismailova G.N.

EDITORIAL BOARD

Baimakhanov Zh.B., PhD, prof.;
Nersesov A.V., D.Med.Sc., prof.;
Doskhanov M.O., PhD;
Sultanaliyev T.A., D.Med.Sc., prof.;
Baimbetov A.K., PhD, prof.;
Bulegenov T.A. D.Med.Sc.,
Miyerbekov Ye.M., D.Med.Sc., prof.;
Zhurayev Sh.Sh., D.Med.Sc., prof.;
Ismailova G.N., Can.Med.Sc., prof.;
Mutagirov V.V. Can.Med.Sc.
Shirtayev B.K., Can.Med.Sc.;
Muradov M.I., Can.Med.Sc., prof.;
Baimakhanov A.N. Can.Med.Sc.

EDITORIAL COUNCIL

Susumu Eguchi (Japan)
Wojciech Polak (Holland)
Remzi Emiroglu (Turkey)
Bulent Oktay (Turkey)
Tamer Turan (Turkey)
Subhash Gupta (India)
Jeong Tea Kim (Korea)
Vladimir Vishnevski (Russia)
Ivan Stilidi (Russia)
Oleg Rummo (Belarus)
Hannu Kuokkanen (Finland)
Ho-Seong Han (Korea)
Mehmet Haberal (Turkey)
Dilgam Maherramov (Azerbaijan)

The journal is registered with the Ministry of
Information, Culture and Sports of the
Republic of Kazakhstan.

The journal is included in the list of scientific
publications recommended by the Committee
for Control of Education and Science, Ministry
of Education and Science of Kazakhstan.

Registration number: 5564-Ж

The owner of the journal – «Syzganov
National Scientific Center of Surgery» JSC

Editorial address:

62, Zheltoksan street, Almaty, 050004
tel. +7 (727) 2795306

http://vhk.kz, e-mail: dr.gismailova@gmail.com

Design and lead out:

«Starkov S.A.» SP

98 Auelbekov street, Kokshetau

Order №634

Edition - 500 copies

The authors are responsible for the content of
published materials.

Subscript index of KAZPOST – 75327

CONTENS

SURGERY

Surgical treatment of atrial fibrillation using cryoablation in patients with rheumatic mitral valve disease and atrial fibrillation, for the first time in kazakhstan.....	4
<i>Nurbay Z., Tuleutayev R., Kuanishbekova R., Djumabekov A., Yestayev D.</i>	
Stepwise application of aortic wall autoplasty, vac-system and combined sterno-osteosynthesis in tandem cardiac surgical complications in one patient	12
<i>Kuatbekov K.N., Tugambaev A.E., Mishin A.V., Nurbekov A.M.</i>	
Thrombosis of mechanical valve prosthesis: a case report	19
<i>Rakishev B.A., Kudaibergen A.B., Imammyrzayev U.E., Taimanova R.S., Temirkhanov A.D., Kaniyev S.A.</i>	
Combined surgery of lung echinococcosis.....	25
<i>Shirtayev B.K., Kaniyev S.A. Ismailova G.N., Yerimova N.Zh., Kurbanov D.R., Aitzhanov M.G., Rakhman N.N.</i>	
Current status of the problem of prevention of post-neoplastic ventral hernias.....	34
<i>Moshkal K.A., Jainakbayev N.T., Madyarov V.M.</i>	
Stereotactic radiosurgery using gamma knife for Itsenko-Cushing's disease.....	45
<i>Bakirzhan M.A., Kozhemzharova M.K., Kuanyshbaeva G.S., Kamitbekova Z.r U., Bazarova A.V.</i>	
CT and MRI referral practices under mandatory social health insurance: a survey of radiologists and GPs.....	57
<i>Baiguissova D., Sadykova A., Baimuratova M.A., Ryskulova A.R., Kalshabay Ye., Mukhamejanova A.N., Battalova G., Kabidenov A.</i>	

SURGICAL TREATMENT OF ATRIAL FIBRILLATION USING CRYOABLATION IN PATIENTS WITH RHEUMATIC MITRAL VALVE DISEASE AND ATRIAL FIBRILLATION, FOR THE FIRST TIME IN KAZAKHSTAN

DOI: 10.35805/BSK2024IV001

Nurbay Z.

<https://orcid.org/0000-0001-5414-6871>

Tuleutayev R.

<https://orcid.org/0000-0002-6003-3010>

Kuanishbekova R.

<https://orcid.org/0000-0002-2020-3353>

Djumabekov A.

<https://orcid.org/0000-0002-3502-4411>

Yestayev D.

<https://orcid.org/0009-0001-6952-043X>

Nurbay Z.^{1,2}, Tuleutayev R.³, Kuanishbekova R.¹,
Djumabekov A.², Yestayev D.³

¹ SCE «City Cardiological Center», Almaty, Kazakhstan

² Kazakh Medical University «KSPH», Almaty, Kazakhstan.

³ JSC «Scientific Research Institute of Cardiology and Internal Medicine», Almaty, Kazakhstan.

received: 27.11.2024

accepted: 16.12.2024

Author for correspondence:

Nurbay Z.

MD, Deputy Director
for Organizational and Methodological
Work. Cardiac Surgery Consultant.
Cardiac Surgeon at the SOE
"City Cardiological Center"
in Almaty. PhD candidate Kazakh
Medical University "KSPH",
<https://orcid.org/0000-0001-5414-6871>,
phdnurbay@gmail.com
+77018008296

Conflict of interest:

The authors declare no potential
conflict of interest requiring disclosure
in this article.

Keywords:

Atrial fibrillation, cryoablation,
radiofrequency ablation, rheumatic
mitral valve disease, sinus rhythm,
surgical treatment of arrhythmias.

Abstract

Background. This study presents the results of a clinical trial evaluating the effectiveness of surgical treatments for atrial fibrillation in patients with rheumatic mitral valve disease. Special attention is given to the comparison of cryoablation and radiofrequency ablation, two methods used in conjunction with mitral valve surgeries. The results indicate that cryoablation, a method first used in Kazakhstan, has long-term advantages for restoring sinus rhythm and cardiac remodeling, thereby improving patients' quality of life.

Materials and Methods. The study was conducted at the period from January 2020 to March 2024 through a retrospective analysis of data from patients with atrial fibrillation and rheumatic mitral valve disease who underwent surgical treatment using one of two methods: Cryoablation with left atrial appendage clipping (Group I) – 50 patients; Radiofrequency ablation with left atrial appendage suturing (Group II) – 50 patients.

Results. According to the conducted research, both cryoablation and radiofrequency ablation are highly effective in restoring sinus rhythm in patients with atrial fibrillation and rheumatic mitral valve disease. Cryoablation, a procedure that was used for the first time in Kazakhstan, demonstrated significant advantages in the long-term maintenance of sinus rhythm and improvement in heart remodeling parameters, such as left atrial volume. This has enhanced the quality of life for patients.

Conclusions. There is a need for the widespread implementation of innovative treatments for atrial fibrillation, such as cryoablation, as surgical procedures are more effective and patients with severe cardiovascular diseases have better outcomes.

Introduction

Currently, cardiac arrhythmia surgery, particularly atrial fibrillation (AF), is a multifaceted field of knowledge encompassing electrophysiology, anatomy, pathophysiology, cardiology, and surgical techniques. It is an actively developing area both in scientific and practical medicine. The main complication today remains stroke.

According to the World Health Organization, there are more than 37 million cases of atrial fibrillation worldwide.^{1,2} Age is the main risk factor for AF, and its

prevalence is expected to increase by 2.3 times due to the rising life expectancy of the population.^{3,4} The age structure of the population in Kazakhstan, like in other European countries, is characterized by an increasing proportion of elderly individuals. It is estimated that by 2050, the global burden of AF may increase by more than 60%.^{5,6}

Currently, the following methods are available for diagnosing AF worldwide: electrocardiogram (ECG), Holter ECG monitoring, and portable devices. The first two methods are available in

the Republic of Kazakhstan. Enhancing the diagnostic capabilities for AF can be achieved through the use of various existing diagnostic methods. However, for coordinated work among healthcare professionals, proper structuring and optimal sequence of actions are necessary.^{7,8}

Guidelines from the European Society of Cardiology indicate that there should be between 280,000 and 560,000 cases of AF among 14 million adults in Kazakhstan. This sharply contrasts with the current situation in the country, which is due to the low level of disease detection.⁹ Stroke prevention with oral anticoagulants, which are sometimes not used by doctors due to concerns about bleeding, is an important part of AF detection. There is always a risk of bleeding.^{3,10,11}

Atrial fibrillation is the most common arrhythmia in patients with rheumatic mitral valve disease. Despite existing treatments, safer and more effective surgical approaches are needed. Cryoablation, an innovative procedure first used in Kazakhstan, employs extremely low temperatures to treat diseases and promises significant improvements in this field.^{12,13}

Schmidt et al. (2016) presented one-year follow-up data from the German Ablation Registry, showing that the recurrence rate of atrial fibrillation one year after the procedure was similar for cryoballoon and radiofrequency ablation (RFA).¹⁴ However, diaphragm nerve paralysis was observed more frequently with cryoablation.^{4,14} In *Tomayko E.'s et al.* (2019) study, it was found that cryoablation and RFA have the same efficacy in restoring sinus rhythm in patients undergoing mitral valve surgery. However, patients who underwent RFA had a greater need for inotropic support in the postoperative period.¹⁵

Engin M. et al. (2024) conducted a retrospective study comparing the safety and clinical outcomes of cryoablation and RFA. Both methods demonstrated similar effectiveness in restoring sinus rhythm one year after surgery.¹⁶

Kuck K. et al randomized study found that cryoablation outperforms radiofrequency ablation in the treatment of paroxysmal atrial fibrillation.¹⁷ Compared to

RFA, cryoballoon ablation requires fewer repeat ablations and has a shorter procedure time, as shown in *Andrade's et al.* study (2019).¹⁸ According to *Schmidt et al.* (2016), the recurrence rate of AF one year after RFA and cryoablation is similar, but the complications associated with these methods differ.¹⁴

Materials and Methods

The study was conducted at the JSC "Scientific Research Institute of Cardiology and Internal Diseases" from January 2020 to March 2024 using a retrospective analysis of data from patients with atrial fibrillation (AF) and rheumatic mitral valve disease who underwent surgical treatment. The study involved a retrospective analysis of data from patients with atrial fibrillation and rheumatic mitral valve disease who underwent open-heart surgery with one of two treatment methods: Cryoablation with left atrial appendage (LAA) clipping (Group I). Radiofrequency ablation (RFA) with suturing of the left atrial appendage (Group II).

A total of 100 patients participated in the study. Group I consisted of 50 patients who underwent valve replacement with cryoablation and LAA clipping. The ArtiCure system for cryoablation of the right and left atria is an innovative method that was first used in Kazakhstan. During the procedure, nitrogen freezes the heart tissue to a temperature of -71°C, and additionally, a clip is placed on the left atrial appendage. This method was applied during open surgeries, such as mitral valve replacement or repair. Group II included 50 patients who underwent valve replacement with radiofrequency ablation and suturing of the left atrial appendage. This traditional method uses radiofrequency heating for ablation, followed by suturing of the left atrial appendage.

The goal of the statistical analysis was to determine the significance of the differences between the two groups. The primary research methods were ECG, echocardiography (ECHO), 24-hour Holter ECG monitoring, and heart computed tomography (CT) before and after surgery to assess the left atrial appendage.

Statistical Analysis. A comparative examination of clinical outcomes, including tracking the incidence of atrial fibrillation recurrence and the emer-

gence of post operative complications, was conducted to evaluate the efficacy of each treatment approach. The gathered data were statistically processed in order to ascertain the significance of the differences between the two groups. The groups were compared using descriptive statistics, the χ^2 test for categorical data, and the t-test for continuous variables. When the differences' significance was at $p < 0.05$, it was deemed significant. Mean and standard deviations (SD) were calculated for each group.

Ethical approval for this study was obtained from the local ethics committee of the Kazakh Medical University "Higher School of Public Health", No. 3, dated February 2, 2024.

Results

Demographic data were analyzed to assess the safety and effectiveness of

cryoablation and radiofrequency ablation in patients with rheumatic mitral valve disease. The number of patients in both groups was the same (50 patients in each group). The average age (in years) was 60.6 ± 9 in Group I and 60.7 ± 9.1 in Group II ($p = 0.960$). The gender distribution (female/male) was 82 (64%) / 18 (36%) in Group I and 83 (66%) / 17 (34%) in Group II ($p = 0.869$).

An analysis of surgical parameters revealed the following key findings (Table 1):

The ablation time in Group I was significantly longer than in Group II ($p < 0.001$), indicating that radiofrequency ablation is quicker than cryoablation.

The aortic cross-clamp time was shorter in Group II compared to Group I ($p = 0.043$), indicating lower invasiveness of radiofrequency ablation.

Table 1.
Operative Parameters

Parameter	Group I (cryoablation) n=50	Group II (RFA) n=50	P value
Ablation time (minutes)	13.7 ± 1	8.6 ± 1	< 0.001
Aortic compression time (minutes)	76.8 ± 7.3	74.1 ± 10.4	0.043
Total perfusion time (minutes)	108.5 ± 12.7	107.3 ± 14.1	0.869

There were no significant differences in total perfusion time between the groups ($p = 0.101$), suggesting comparable operation duration in both groups.

Sinus rhythm restoration in patients

with rheumatic mitral valve disease was evaluated at 6 and 12 months post-surgery to determine the effectiveness of cryoablation and radiofrequency ablation (see Table 2).

Table 2.
Frequency of Sinus Rhythm Restoration

Parameter	Group I (cryoablation)	Group II (RFA)	P value
After 6 months	$66\% \pm 5$	$52\% \pm 5$	< 0.05
After 12 months	$66\% \pm 5$	$50\% \pm 5$	< 0.05

The results showed that, both at 6 months and 12 months post-surgery, the rate of sinus rhythm restoration was significantly higher in the cryoablation group compared to the radiofrequency ablation group. These findings confirm that cryoablation is more effective in restoring sinus rhythm in patients with rheumatic mitral valve disease.

The left atrial volume (LAV) is an important indicator for assessing the degree of reverse remodeling of the heart.

LAV was measured before the operation, immediately after the operation, and 6 months post-operation. The results of LAV analysis (see Table 3) showed that in the cryoablation group, the left atrial appendage volume was significantly lower both immediately after the operation and 6 months later, compared to the radiofrequency ablation group. This suggests more pronounced reverse remodeling of the heart in the cryoablation group.

Observation period	Group I (cryoablation) n=50	Group II (RFA) n=50	P value
Before the operation	119.2 ± 20.1	120.5 ± 21.3	0.761
Immediayely after the operation	82.68 ± 15.3	95.7 ± 18.2	< 0.001
After 6 months	78.64 ± 12.5	94.1 ± 16.4	< 0.001

Table 3.
Left Atrium Volume (ml)

The study also showed that stroke volume in both groups decreased immediately after surgery and remained at the same level after six months. However, no significant differences were found between the groups. Both the end-diastolic volume and end-systolic volume decreased immediately after surgery and

continued to decrease over six months, with no significant differences between the groups.

Ejection fraction (EF), the percentage of blood volume ejected from the left ventricle in one cardiac cycle, was also an important indicator of the heart's pumping function (see Figure 1).

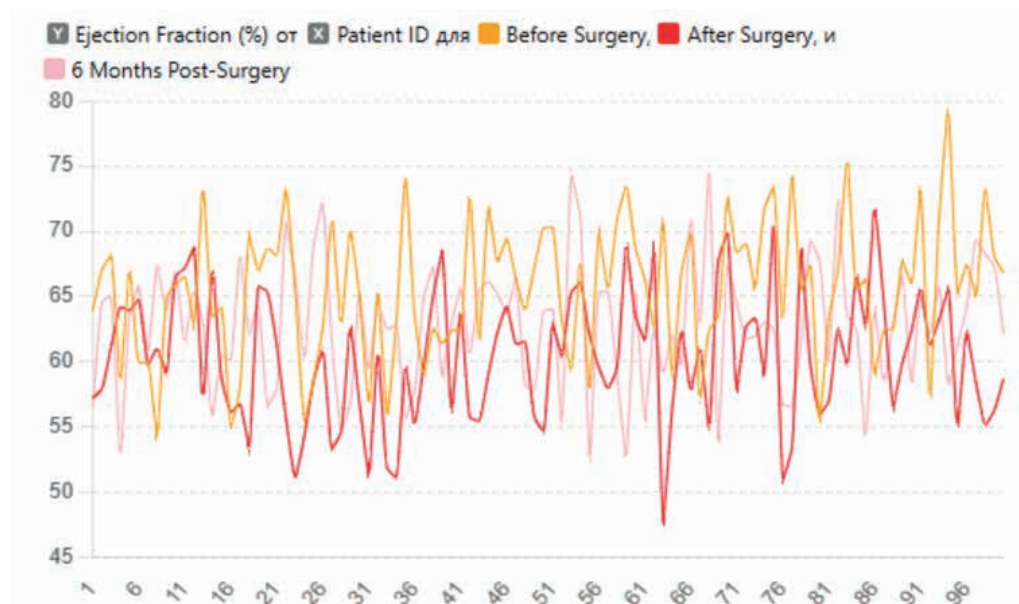


Figure 1.
Changes in Ejection Fraction Over Time

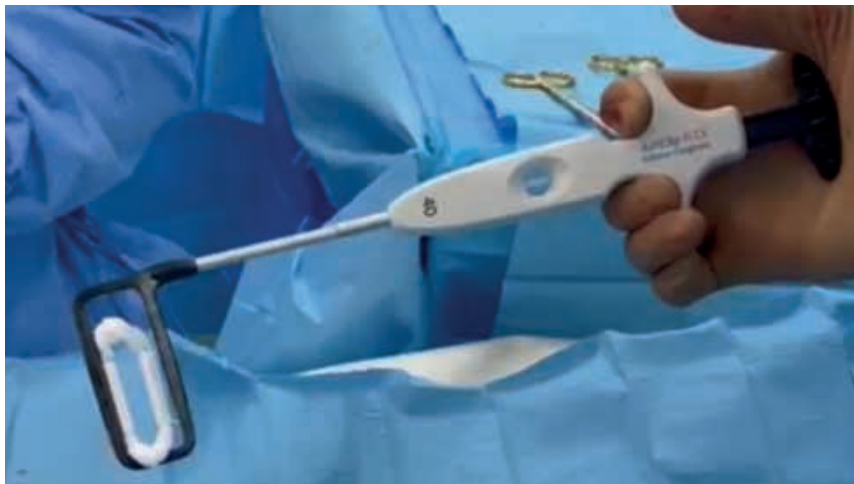Post-surgery, positive changes were observed in the normalization of heart rhythm and improved regulation of heart activity. This was confirmed by ECG data reflecting changes in heart rate (HR) during the day and night. An increase in the number of premature ventricular contractions (PVCs) after surgery may be the result of short-term impact on heart rhythm due to surgical intervention. Such an increase may indicate a temporary rise in the arrhythmic potential of the heart, which is a common response to stress caused by the surgery.

At 6 months post-surgery, the average number of PVCs decreased to levels below baseline, indicating heart stabilization and improved electrical stability. This suggests that the surgical intervention positively impacts heart function

and reduces the risk of arrhythmias. ST segment changes after surgery should be closely monitored, as they may indicate ischemia or changes in myocardial perfusion. Since these changes may signal the need for treatment adjustments or additional diagnostic procedures, they require careful observation. Overall, positive trends in heart electrical activity are observed when considering ECG changes before and after surgery, as well as in the long-term recovery period. This underscores the importance of regular monitoring to evaluate heart function recovery, treatment effectiveness, and potential complications.

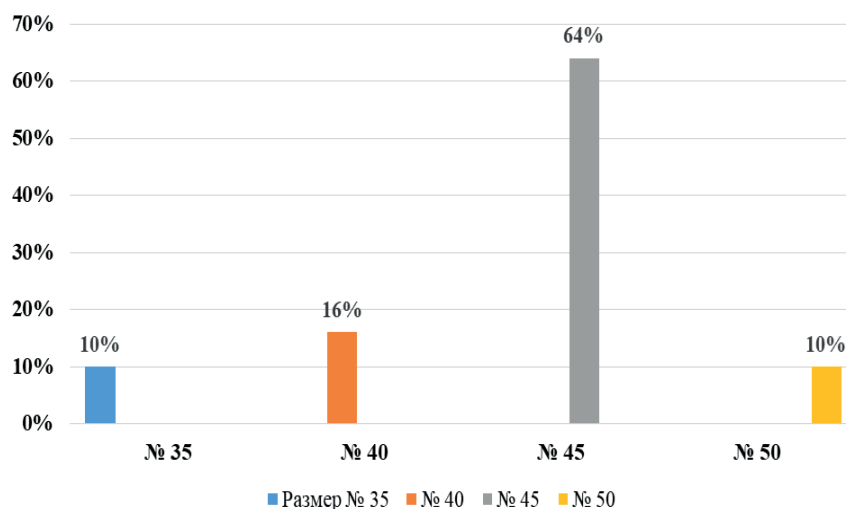
In most cases (80%), left atrial appendage occlusion was performed using the "AtriCure" clip system in various sizes (see Figure 2).

Figure 2.
Left atrial appendage clipping device



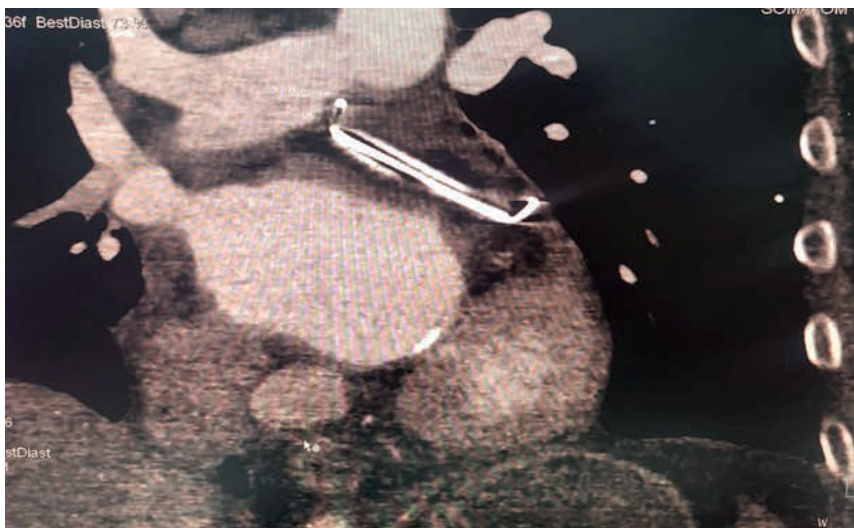
In fewer cases (20%), LAA closure was achieved through suturing due to anatomical features of the LAA and the inability to use a clip (for example, in 2 patients, the LAA was too short and small for the clip, and in 8 patients, the presence of thrombi in the LAA made clip placement contraindicated). The sizes of the clips used are shown in Figure 3.

Figure 3.
Shows the sizes of the clips used for left atrial appendage clipping



In the postoperative period, LAA was also assessed via heart CT to evaluate the integrity and correctness of the clip placement (see Figure 4).

Figure 4.
Hermetically closed left atrial appendage according to cardiac CT scans



After surgery, 99% of patients were successfully discharged for outpatient follow-up, indicating a positive surgical outcome and effective recovery. No deaths were reported in either group. After surgery, three patients in the cryoablation group and one patient in the radiofrequency ablation group had pacemakers implanted. Six months after surgery, six patients in the cryoablation group and three in the radiofrequency ablation group had pacemakers. Twelve months after surgery, six patients in the cryoablation group and four in the radiofrequency ablation group had pacemakers.

The average time spent in the intensive care unit was 1.4 days, indicating rapid recovery and minimal time in intensive care. No serious complications occurred in the postoperative period, reflecting a high level of postoperative care and management of potential risks.

Discussion

The results of the conducted study show that both cryoablation and radiofrequency ablation are highly effective methods for restoring sinus rhythm in patients with atrial fibrillation and rheumatic mitral valve disease. Cryoablation, which was used for the first time in Kazakhstan, demonstrated significant advantages in the long-term maintenance of sinus rhythm and improved heart remodeling parameters, such as left atrial volume. This contributed to an enhancement in the patients' quality of life.^{5,6}

Compared to radiofrequency ablation, cryoablation is more effective and reduces the risk of arrhythmia recurrence, despite the longer surgery time. However, both methods showed similar results in terms of total perfusion time and mortality, confirming their safety and applicability in clinical practice.^{2,13,17}

Our results, which showed that cryoablation is more effective than radiofrequency ablation in restoring sinus rhythm at 6 and 12 months, are consistent with the findings of the *Kuck et al.* (2016) study,¹⁹ where similar effectiveness of both procedures was observed. However, our data differ in terms of more pronounced left atrial remodeling, which was not reflected in the *Kuck et al.* (2016) study.¹⁷

Cryoablation and radiofrequency ablation have shown effectiveness in re-

storing sinus rhythm. Previously, both cryoablation and RFA have been shown to be effective in treating atrial fibrillation, with comparable success rates. Previously, both cryoablation and RFA have been shown to be effective in treating atrial fibrillation, with comparable success rates. Studies such as those by *Schmidt et al.* (2016) and *Engin M et al.* (2024) reported similar outcomes in restoring sinus rhythm, but complications differ across the methods.^{14,16}

This is especially evident in the improvement of long-term sinus rhythm restoration outcomes and more pronounced left atrial remodeling.³

Limitations. Retrospective and single-center study design. The sample size, though sufficient for initial comparisons, may not be large enough to draw definitive conclusions applicable to broader populations. Additionally, the study focused solely on patients with rheumatic mitral valve disease, limiting the generalizability of the findings to other patient groups.

What's known? It has been previously established that AF is a common arrhythmia in patients with mitral valve disease. Cryoablation and radiofrequency ablation have shown similar effectiveness in restoring sinus rhythm.

What's new? Our study, conducted for the first time in Kazakhstan, showed that cryoablation has significant advantages over radiofrequency ablation in treating atrial fibrillation in patients with rheumatic mitral valve disease.

Conclusion

The data suggest the need for further research and widespread implementation of innovative methods for treating atrial fibrillation, such as cryoablation, as surgical interventions are more effective, and patients with severe cardiovascular diseases achieve better outcomes. A comprehensive approach, including the use of modern technologies and personalized therapy, promotes sinus rhythm recovery and reduces the risk of complications and mortality.

Acknowledgements. The authors would like to express their sincere gratitude to the scientific advisors for their invaluable guidance, support and expertise throughout the study. Their encouragement, insightful comments, and con-

tinuous support were essential for the successful completion of this work.

Author's contributions. N.Zh., T.R.: Study concept; N.Zh., D.A.: Study design; N.Zh, Y.D.: Data analysis; N.Zh,

T.R.: Drafting of manuscript; N.Zh, T.R., D.A.: Writing the text of the article; K.R.: Critical revision of the manuscript. All authors approved the final version of the manuscript.

References

1. Lippi G, Sanchis-Gomar F, Cervellin G. Global epidemiology of atrial fibrillation: An increasing epidemic and public health challenge. *Int J Stroke*. Feb 2021;16(2):217-221. doi:10.1177/1747493019897870
2. Bai Y, Wang YL, Shantsila A, Lip GYH. The Global Burden of Atrial Fibrillation and Stroke: A Systematic Review of the Clinical Epidemiology of Atrial Fibrillation in Asia. *Chest*. Oct 2017;152(4):810-820. doi:10.1016/j.chest.2017.03.048
3. Rahman F, Kwan GF, Benjamin EJ. Global epidemiology of atrial fibrillation. *Nat Rev Cardiol*. Jul 14 2016;13(8):501. doi:10.1038/nrcardio.2016.114
4. Hindricks G, Potpara T, Dagres N, et al. 2020 ESC Guidelines for the diagnosis and management of atrial fibrillation developed in collaboration with the European Association for Cardio-Thoracic Surgery (EACTS): The Task Force for the diagnosis and management of atrial fibrillation of the European Society of Cardiology (ESC) Developed with the special contribution of the European Heart Rhythm Association (EHRA) of the ESC. *Eur Heart J*. Feb 1 2021;42(5):373-498. doi:10.1093/eurheartj/ehaa612
5. Baimbetov AK, Bizhanov KA, Abzaliev KB, Bairamov BA, Yakupova IA. Prediction of arrhythmia recurrence after atrial fibrillation ablation in patients with normal anatomy of the left atrium. *Int J Clin Pract*. Jun 2021;75(6):e14083. doi:10.1111/ijcp.14083
6. Bizhanov KA, capital A CKB, Baimbetov AK, Sarsenbayeva AB, Lyan E. Atrial fibrillation: Epidemiology, pathophysiology, and clinical complications (literature review). *J Cardiovasc Electrophysiol*. Jan 2023;34(1):153-165. doi:10.1111/jce.15759
7. Nishimura RA, Otto CM, Bonow RO, et al. 2014 AHA/ACC Guideline for the Management of Patients With Valvular Heart Disease: executive summary: a report of the American College of Cardiology/American Heart Association Task Force on Practice Guidelines. *Circulation*. Jun 10 2014;129(23):2440-92. doi:10.1161/CIR.0000000000000029
8. Baimbetov AK, Abzaliev KB, Jukenova AM, Bizhanov KA, Bairamov BA, Ualiyeva AY. Retraction Note: The efficacy and safety of cryoballoon catheter ablation in patients with paroxysmal atrial fibrillation. *Ir J Med Sci*. Feb 2024;193(1):539. doi:10.1007/s11845-023-03458-8
9. Virani SS, Alonso A, Aparicio HJ, et al. Heart Disease and Stroke Statistics-2021 Update: A Report From the American Heart Association. *Circulation*. Feb 23 2021;143(8):e254-e743. doi:10.1161/CIR.0000000000000950
10. Chun KRJ, Perrotta L, Bordignon S, et al. Complications in Catheter Ablation of Atrial Fibrillation in 3,000 Consecutive Procedures: Balloon Versus Radiofrequency Current Ablation. *JACC Clin Electrophysiol*. Feb 2017;3(2):154-161. doi:10.1016/j.jacep.2016.07.002
11. Andrade JG, Khairy P, Macle L, et al. Incidence and significance of early recurrences of atrial fibrillation after cryoballoon ablation: insights from the multicenter Sustained Treatment of Paroxysmal Atrial Fibrillation (STOP AF) Trial. *Circ Arrhythm Electrophysiol*. Feb 2014;7(1):69-75. doi:10.1161/CIRCEP.113.000586
12. Baimbetov AK, Abzaliev KB, Jukenova AM, Bizhanov KA, Bairamov BA, Ualiyeva AY. The efficacy and safety of cryoballoon catheter ablation in patients with paroxysmal atrial fibrillation. *Ir J Med Sci*. Feb 2022;191(1):187-193. doi:10.1007/s11845-021-02560-z

13. Chen X, Xia Y, Lin Y, et al. Cryoballoon Ablation for Treatment of Atrial Fibrillation in a Chinese Population: Five-Year Outcomes and Predictors of Recurrence After a Single Procedure. *Front Cardiovasc Med.* 2022;9:836392. doi:10.3389/fcvm.2022.836392
14. Schmidt M, Dorwarth U, Andresen D, et al. German ablation registry: Cryoballoon vs. radiofrequency ablation in paroxysmal atrial fibrillation--One-year outcome data. *Heart Rhythm.* Apr 2016;13(4):836-44. doi:10.1016/j.hrthm.2015.12.007
15. Tomaiko E, Su WW. Comparing radiofrequency and cryoballoon technology for the ablation of atrial fibrillation. *Curr Opin Cardiol.* Jan 2019;34(1):1-5. doi:10.1097/HCO.0000000000000578
16. Engin M, Gursoy NC, Tatli AB. Importance of additional risk factors in postoperative atrial fibrillation risk analysis methods. *Rev Assoc Med Bras* [1992]. 2024;70(2):e20231319. doi:10.1590/1806-9282.20231319
17. Kuck KH, Furnkranz A, Chun KR, et al. Cryoballoon or radiofrequency ablation for symptomatic paroxysmal atrial fibrillation: reintervention, rehospitalization, and quality-of-life outcomes in the FIRE AND ICE trial. *Eur Heart J.* Oct 7 2016;37(38):2858-2865. doi:10.1093/eurheartj/ehw285
18. Andrade JG, Champagne J, Dubuc M, et al. Cryoballoon or Radiofrequency Ablation for Atrial Fibrillation Assessed by Continuous Monitoring: A Randomized Clinical Trial. *Circulation.* Nov 26 2019;140(22):1779-1788. doi:10.1161/CIRCULATIONAHA.119.042622
19. Kuck KH, Brugada J, Furnkranz A, et al. Cryoballoon or Radiofrequency Ablation for Paroxysmal Atrial Fibrillation. *N Engl J Med.* Jun 9 2016;374(23):2235-45. doi:10.1056/NEJMoa1602014

STEPWISE APPLICATION OF AORTIC WALL AUTOPLASTY, VAC-SYSTEM AND COMBINED STERNO-OSTEOSYNTHESIS IN TANDEM CARDIAC SURGICAL COMPLICATIONS IN ONE PATIENT

DOI:10.35805/BSK2024IV002

Kuatbekov K.N.<https://orcid.org/0000-0001-6605-6435>**Tugambaev A.E.**<https://orcid.org/0000-0002-4346-4468>**Mishin A.V.**<https://orcid.org/0000-0003-2858-6181>**Nurbekov A.M.**<https://orcid.org/0000-0003-4192-8940>**Kuatbekov K.N.¹, Tugambaev A.E.¹, Mishin A.V.¹, Nurbekov A.M.²**¹ Erensau Hospital Almaty, Kazakhstan² Asfendiyarov S.D. Kazakh National Medical University, Almaty, Kazakhstan

received: 25.11.2024

accepted: 10.12.2024

Author for correspondence:**Mishin A.**

Cardiac surgeon of the Department
of Cardiac Surgery and Cardiology
(avm_miishin@mail.ru, 87477231170)
ORCID 0000-0003-2858-6181

Conflict of interest:

The authors declare no potential
conflict of interest requiring disclosure
in this article.

Keywords:

bleeding, vacuum system,
thoracoplasty, case report; cardiac
surgery

Abstract

This paper describes the effective management of successive early postoperative complications, using aortic wall autoplasty, VAC-system, with completion of combined sterno-osteosynthesis in one cardiac surgical patient. The paper presents a clinical case of management of postoperative complications in a 67-year-old patient after aortic valve replacement and three-vessel myocardial revascularization by applying a combined and step-by-step approach for each complication: 1. In case of surgical bleeding - formation of flap plasty of the damaged aortic wall with autopericardium by in situ fixation method; 2. In case of profuse bleeding - application of VAC-system; 3. In case of high risk of sternum divergence - its closure by preferential rheosteosynthesis with tie-fixation devices. The described methods of control, carried an individual approach and the choice of the optimal method of their application, which requires knowledge of the entire arsenal of relevant and effective ways of emergency elimination of complications. In our case, unfortunately, against the background of successful one-stage treatment of all complications, the outcome was unfavorable, due to the exhaustion of compensatory mechanisms of the body against the background of severe combined acquired cardiac pathology. Autopericardium plasty by the method of fixation on the stem created additional protection of the aortic bleeding zone, and further installation of the VAC-system successfully stopped the uncontrollable non-surgical bleeding that was festering. Clamp-buckle osteosynthesis, which we applied as a standard in reoperations, contributed to more active intensive care in intensive care with improved repair of the sternum.

Introduction

The standard method of treatment of patients with combined aortic stenosis and coronary heart disease (CHD) is one-stage surgical aortic valve replacement and aortocoronary artery bypass grafting. The number of such surgeries is steadily increasing,^{1,2} and complications are growing proportionally. According to the data of the study by *Stefanov S.A. et al*, which included 244 patients, the risk assessment of the ascending aorta leakage during aortic valve prosthetic operations was given, where the ascending aorta leakage was noted in 20.5% of patients, in 4.9% of cases it was accompanied by intensive bleeding. In 88% of cases aor-

tic leakage was localized in the area of aortic sutures and its cannulation sites. The independent predictors of aortic leakage with high risk of bleeding were aortic diameter 46 mm and higher and its calcinosis. The combination of aortic stenosis and III degree calcinosis was also associated with moderate risk of aortic leakage.³

Unsatisfactory results of aortic surgeries are mainly associated with intra- and postoperative bleeding, therefore, the use of various methods of anastomosis formation and sealing is primarily aimed at reducing the volume of blood loss in order to achieve a favorable outcome of the operation. These are either

wrapping with own aortic tissues,² or using synthetic materials such as: vascular prostheses, tetrafluoroethylene gaskets, as well as the use of various medical adhesives and foams. Aortic surgeries are often complicated by coagulopathy, a factor of which is the disruption of normal blood coagulation mechanisms due to: blood loss, massive hemotransfusions, duration of artificial circulation, temperature regime, degree of hemodilution.^{4,5}

The risk of developing postoperative sternomediastinitis and sternal instability depends on the patient's comorbidities (diabetes, obesity, smoking, renal insufficiency) and surgical techniques (bilateral extraction of the internal thoracic artery, excessive use of coagulation, duration of surgery, postoperative bleeding).^{6,7} Deferred thorax apertum is extremely important in case of low-fraction heart function and myocardial edema after prolonged surgery,⁸ and the use of the innovative method of VAC-system has proved to be safe and highly effective not only for the prevention of infectious complications and mediastinal stabilization, but also its hemostatic effect in profuse bleeding.⁹ Developments and clinical applications of negative pressure wound therapy belong to Russian surgeons *Davydov Y.A. et al.* The method of negative pressure wound treatment is highly effective and multifunctional, its drainage-evacuation and stabilizing effect, as well as antiseptic and hemostatic effect, are widely used in the treatment and prevention of many complications after open cardiac surgery.¹⁰

An important step in the completion of open surgery is the restoration of the integrity of the sternal rib cage using various types of alternative fixation devices to conventional wire. Studies on the use of pectoral implants with extrasternal fixation, demonstrate clinical advantages in sternum divergence after surgery using tie-clamps compared to surgical wire.¹¹ Reoperations always increase the risk of postoperative sternal destabilization and infectious complications, while thoracic cable ties provide reliable closure of the sternum, reducing the risk of these complications.¹²

In the present work we present a clinical case of several complications

after combined surgery on the valve and vascular apparatus of the heart in one patient, with combined methods of their effective elimination.

The purpose of the study is present work presents a description of the effective management of one after another early postoperative complications that arose by the use of aortic wall autoplasty, VAC-system, with completion of combined sterno-osteosynthesis in one cardiac surgical patient.

Ethical approval. All procedures performed in research involving human subjects conformed to institutional and national research committee ethical standards, as well as to the 1964 Declaration of Helsinki and its more recent amendments

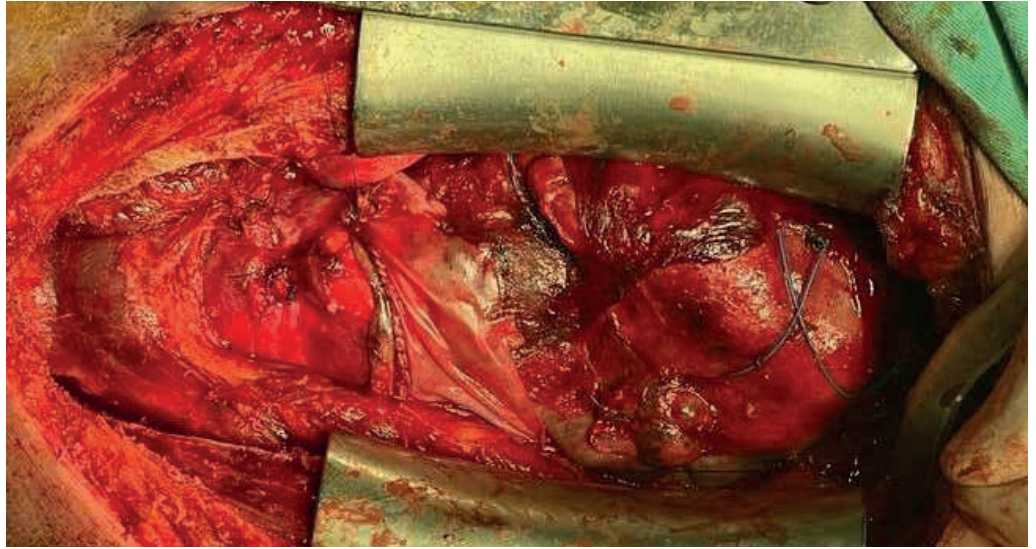
Case presentation

Patient A. 67 years old, diagnosis: Multifocal atherosclerosis. Stenosis, calcinosis of aortic valve of IV degree. Multivessel coronary lesion. Unstable angina pectoris class IIIB according to Braunwald. CHF stage B (ACC/AHA), III FC according to NYHA. According to ECHO: aortic valve fibrous ring 1.8 cm, peak systolic gradient on the valve 40 mm Hg, calcinosis of III degree. The diameter of the ascending aorta is 43 mm. Left ventricle: QDR 3.9 cm; CSR 2.3 cm; LV 66 ml; CSR 18 ml; hypokinesis of the anterior septal segment; EF 62%.

Aortic valve replacement with a mechanical prosthesis «Medtronic №21», mammary coronary artery bypass grafting of PMLV, aortocoronary bypass of DV and PCA were performed routinely. On the 4th postoperative day there was abundant scarlet blood flow through the antegrade drains, the patient was operated urgently. On operation: 500 ml of hemopericardium, a 4 x 7 mm diameter aortic wall rupture above the aortic suture was identified on the anterior aortic wall proximal from the previous three sutures with Teflon pads. The site of the rupture was sutured with prolene 4/0 thread on Teflon pads with hemostatic sponge application. Taking into account the technical impossibility to bypass the posterior wall of the aorta, in order to enhance the hemostatic effect, it was decided to form an encircling half-ring (8 x 3 cm) with autopericardium by the type of artificial adventitia without cut-

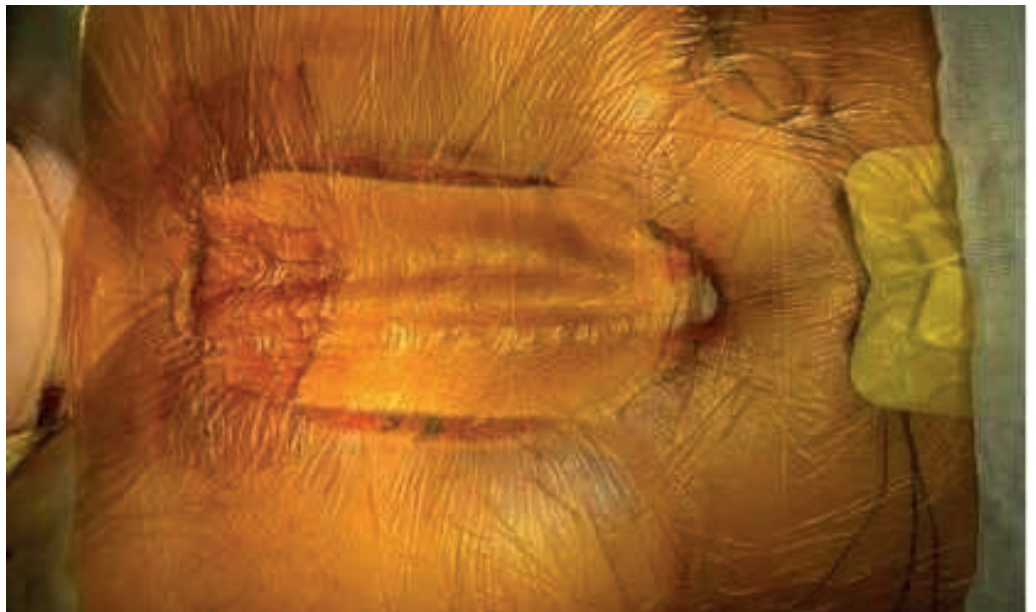
ting off its proximal part with the effect of rupture zone (Fig. 1). Due to unstable hemodynamics, it was decided to leave the sternum open.

Figure 1.
Right pericardial flap fixed to
the anterior aortic stack



During the first postoperative day, 1200 ml of blood was released through the drains despite intensive conservative hemostatic therapy. It was decided to install a VAC-system to stop diffuse, uncontrolled bleeding (Fig. 2).

Figure 2.
Installed VAC-system on the
open mediastinum



The dynamics of bleeding reduction by drains amounted to: the first day - 250 ml, the second day - 150 ml, the third day - 110 ml. After 5 days of continuous course of VAC therapy, it was possible to completely stop coagulopathic bleeding (Fig. 3).

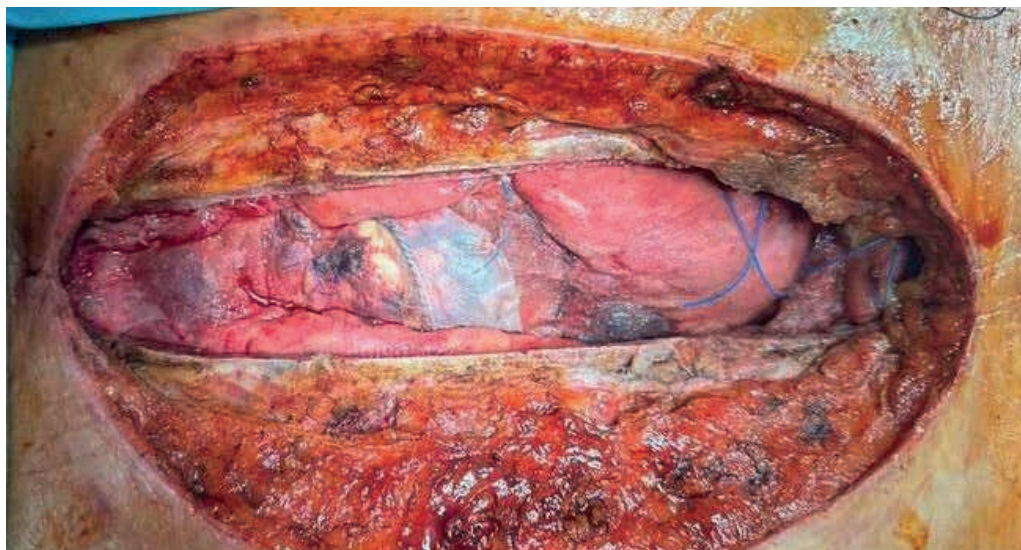


Figure 3.
Result of a 5-day course of negative pressure therapy: control of diffuse bleeding with antiseptic effect

On the 11th day after the first elective surgery, the mediastinum was closed by combined osteosynthesis of the sternum with two 12 mm clamp ties and two surgical wires (Figure 4).

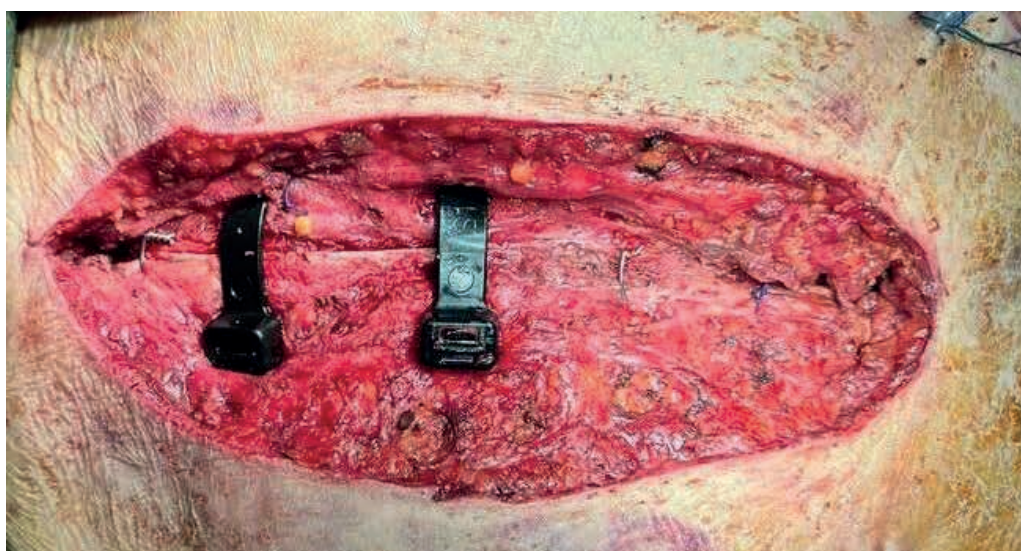


Figure 4.
Combined osteosynthesis of the sternum

Despite all measures taken, death could not be avoided due to progressive heart failure.

Discussion

External wrapping of aortic anastomoses with a vascular prosthesis is the method of choice for hemostasis in case of diffuse bleeding of the aortic wall.¹³ For total closure of the extensive bleeding zone of the aorta, we needed to pass its posterior wall, which was technically impossible without the latter, so we decided to use the separated autopericardium by moving its flap on the feeding pedicle with preservation of its vascularized proximal part. The distal part of the pericardium directly covered the area of the lesion of the anterior wall of the aor-

ta. After completion of the plasty, its reliable operation was checked during hypertensive peaks, when the load on the suture line was submaximal. In contrast to artificial patches or tanned pericardium, which lack the properties of extensibility, static suture zone of attachment on the working heart is always at risk of rupture, while our method of plasty with autopericardium on a mobile stem reduces this risk due to the preservation of elasticity with damping effect of such a patch, which at the same time enhances the tread compression of the damaged aortic zone especially in the systolic phases of contraction.

The use of VAC therapy for the treatment of mediastinitis significantly re-

duces mortality, complication rate, and the need for surgical procedures, thus leading to a significant reduction in labor costs.^{14,15} Using multifunctional VAC-system, we pursued the aim to use first of all its hemostatic function to stop uncontrolled non-surgical bleeding, together with its highly effective anti-infection protection and simultaneous stabilization of the open mediastinum in unstable hemodynamics. For myocardial protection, we placed povidone-impregnated dense tissue directly on the anterior surface of the heart and main vessels. The mode parameters of VAC were set as standard: 5 minutes of operation with pressure of 125 mmHg and 2 minutes of stopping.

Sternum fixation systems with the help of clamp ties provide a larger bone contact of the implant with a better distribution of the tension force, preventing the sternum from erupting.¹⁶ The use of these devices in comparison with conventional steel wire excludes intraosseous damage of the spongy substance without disturbing its trophism with better repair. In sternum osteosynthesis, we adhere to our approach of using clamp ties in almost all reoperations, as well as initially in cardiac surgery patients with a high risk of sternum instability in the postoperative period. Given the patient's excessive body weight (BMI 29.7), we used a 12 mm width of the ties 6 times the contact area of conventional wire, which allowed us to use only 2 ties in the areas of greatest load (upper third of the sternum) for reliable stabilization.

Thus, the above-mentioned methods of control in each specific case had an individual approach and the choice of the optimal method of their application, which requires knowledge of the entire arsenal of relevant and effective ways of emergency elimination of complications. In our case, unfortunately, against the background of successful one-stage management of all complications, the outcome was unfavorable, due to the exhaustion of compensatory mechanisms of the body against the background of severe combined acquired heart pathology.

Limitations. The only limitation of our work may have been the unfavorable patient outcome, but the sequential ap-

plication of all three treatment modalities successfully managed successive complications, indicating their high efficacy.

What's known? The tactics of management of diffuse bleeding was and still is therapeutic treatment aimed at homeostasis of rheological properties of blood by transfusion of SPP and individual factors of the coagulation system. Prevention of local bleeding is the use of various methods of anastomosis formation and sealing by wrapping with own aortic tissues, or the use of synthetic materials (vascular prostheses, tetrafluoroethylene gaskets, as well as the use of various medical adhesives and foams). In case of sternal diastasis, various methods of osteosynthesis with wire cerclages have been used, for example, according to Robichek.

What's new? In the available literature we have not found a similar method of formation of a protective hemostatic patch from autopericardium on a mobile stem, as well as methods of treatment of three complications in one and the same patient by the new methods described in the article.

Conclusion

After complex combined cardiac surgery, it is necessary to always keep in mind the high risk of various complications that require knowledge of the entire arsenal of relevant and effective ways of their urgent elimination. Our proposed method of aortic wall strengthening by autolusculature on a pedicle gives an alternative to mechanical hemostasis by «inanimate» patches in case of impossibility to envelop the whole aortic tube. Highly effective VAC-therapy should be applied not only at the moment of clinical manifestation of diffuse and uncontrolled mediastinal bleeding, but also immediately after planned surgeries in patients with high risks of its development. The use of sternal clamp fixators should be the standard for all reoperations and primary use in patients with a high risk of postoperative sternal diastasis.

Acknowledgement. We would like to express our gratitude to the staff of the operating unit of the «Erensau Hospital».

Author's contributions. M.A.: Study concept; M.A., N.A.: Study design; M.F.,

K.K.: Data analysis; M.A., N.A.: Drafting of manuscript; M.A., T.A.: Writing the text of the article; K.K., M.A.: Critical revision

of the manuscript. All authors approved the final version of the manuscript.

Funding. Not funded.

References

1. Santoro A, Rizk M, Inga Tavera L, Ramadan MS, Melissano G. Successful Open Repair of a Thoracoabdominal Aortic Aneurysm After Multiple Failed Endovascular Treatments in a 22-Years-Old Individual With Loeys-Dietz Syndrome. *Vasc Endovascular Surg.* Sep 25 2024;15385744241285112. doi:10.1177/15385744241285112
2. Tanaka A, Smith HN, Safi HJ, Estrera AL. Open Treatments for Thoracoabdominal Aortic Aneurysm Repair. *Methodist Debakey Cardiovasc J.* 2023;19(2):49-58. doi:10.14797/md-cvj.1178
3. Stefanov SA, Smolianinov KA, Matugin MP, et al. [Paradoxical embolism: clinical situation and approaches to treatment]. *Angiol Sosud Khir.* 2015;21(1):192-7.
4. Brown JA, Kilic A, Aranda-Michel E, et al. Long-Term Outcomes of Reoperation for Bleeding After Cardiac Surgery. *Semin Thorac Cardiovasc Surg.* Autumn 2021;33(3):764-773. doi:10.1053/j.semtcvs.2020.11.013
5. Qureshi SH, Ruel M. Commentary: A Long-Lasting Complication: Re-exploration for Bleeding and Its Negative Correlation With Long-Term Survival. *Semin Thorac Cardiovasc Surg.* Autumn 2021;33(3):776-777. doi:10.1053/j.semtcvs.2020.12.025
6. Goh SSC. Post-sternotomy mediastinitis in the modern era. *J Card Surg.* Sep 2017;32(9):556-566. doi:10.1111/jocs.13189
7. Sa M, Ferraz PE, Soares AF, et al. Development and Validation of a Stratification Tool for Predicting Risk of Deep Sternal Wound Infection after Coronary Artery Bypass Grafting at a Brazilian Hospital. *Braz J Cardiovasc Surg.* Jan-Feb 2017;32(1):1-7. doi:10.21470/1678-9741-2016-0030
8. Bakaeen FG, Haddad O, Ibrahim M, et al. Advances in managing the noninfected open chest after cardiac surgery: Negative-pressure wound therapy. *J Thorac Cardiovasc Surg.* May 2019;157(5):1891-1903 e9. doi:10.1016/j.jtcvs.2018.10.152
9. Lorenz V, Gambacciani A, Guerrini S, Giuseppe MF, Gianfranco M, Mattesini A. Management of Giant Pulmonary Artery Aneurysm with Quadricuspid Valve Stenosis. *Int J Angiol.* Dec 2023;32(4):312-315. doi:10.1055/s-0041-1732435
10. Davydov VI, Karasev EV, Popova EV, Poletaev VI. Method of estimating sea-surface paleotemperatures through biotic proxies: A case study in Upper Paleozoic paleoclimatic, paleogeographic and paleotectonic reconstructions of Siberia. *Ecol Evol.* Nov 2024;14(11):e70265. doi:10.1002/ece3.70265
11. Nezafati P, Shomali A, Kahrom M, Omidvar Tehrani S, Dianatkah M, Nezafati MH. ZipFix Versus Conventional Sternal Closure: One-Year Follow-Up. *Heart Lung Circ.* Mar 2019;28(3):443-449. doi:10.1016/j.hlc.2018.01.010
12. Marasco SF, Fuller L, Zimmet A, et al. Prospective, randomized, controlled trial of polymer cable ties versus standard wire closure of midline sternotomy. *J Thorac Cardiovasc Surg.* Oct 2018;156(4):1589-1595 e1. doi:10.1016/j.jtcvs.2018.04.025
13. Song L, Gao Y, Xu M, Wang B, Li X, Wang X. "Sleeve" Sinus of Valsalva Repair in Patients with Acute Type A Aortic Dissection. *Heart Surg Forum.* May 11 2021;24(3):E418-E421. doi:10.1532/hsf.3629
14. Tarzia V, Carrozzini M, Bortolussi G, et al. Impact of vacuum-assisted closure therapy on outcomes of sternal wound dehiscencedagger. *Interact Cardiovasc Thorac Surg.* Jul 2014;19(1):70-5. doi:10.1093/icvts/ivu101
15. Pericleous A, Dimitrakakis G, Photiades R, von Oppell UO. Assessment of vacuum-assisted closure therapy on the wound healing process in cardiac surgery. *Int Wound J.* Dec 2016;13(6):1142-1149. doi:10.1111/iwj.12430

16. Stelly MM, Rodning CB, Stelly TC. Reduction in deep sternal wound infection with use of a peristernal cable-tie closure system: a retrospective case series. *J Cardiothorac Surg.* Nov 14 2015;10:166. doi:10.1186/s13019-015-0378-7

THROMBOSIS OF MECHANICAL VALVE PROSTHESIS: A CASE REPORT

Rakishev B.A., Kudaibergen A.B., Imammyrzayev U.E.,
Taimanova R.S., Temirkhanov A.D., Kaniyev S.A.

Syzganov National Scientific Center of Surgery

Abstract

Mitral valve prosthesis thrombosis is a rare but life-threatening complication associated with mechanical heart valves. It requires timely diagnosis and prompt intervention to prevent severe morbidity and mortality. We report the case with hemoptysis, severe dyspnea, and fever, two years after mechanical mitral valve replacement with a St. Jude Medical prosthesis. Despite consistent anticoagulation therapy, recent transition from warfarin to low-molecular-weight heparin during hospitalization for pneumonia may have contributed to prosthetic thrombosis. Echocardiography revealed significant mitral valve dysfunction with a mean pressure gradient of 45 mmHg and evidence of thrombus formation. Emergency surgery confirmed total prosthetic valve thrombosis and necessitated thrombectomy and replacement with a new mechanical valve. Post-operative recovery was uneventful, with improved hemodynamics and resolution of pulmonary edema. This case highlights the complexities of managing mechanical valve thrombosis in patients with multiple risk factors, including anticoagulation changes, atrial fibrillation, and recurrent pulmonary infections. The surgical approach remains the gold standard for treatment, though emerging evidence supports the potential role of thrombolysis in select cases. In conclusion, mitral valve prosthesis thrombosis represents a significant challenge requiring multidisciplinary management and strict anticoagulation monitoring, and the importance of developing standardized protocols for early diagnosis, anticoagulation management, and surgical intervention.

DOI: 10.35805/BSK2024IV003

Rakishev B.A.

<https://orcid.org/0009-0001-2380-5480>

Kudaibergen A.B.

<https://orcid.org/0000-0002-2725-7530>

Imammyrzayev U.E.

<https://orcid.org/0000-0001-8302-6879>

Taimanova R.S.

<https://orcid.org/0000-0002-5308-5381>

Temirkhanov A.D.

<https://orcid.org/0000-0003-4153-321X>

Kaniyev S.A.

<https://orcid.org/0000-0002-1288-0987>

received: 01.12.2024

accepted: 10.12.2024

Author for correspondence:

Kudaibergen A.B.

cardiac surgeon of the cardiac surgery department of the Syzganov National scientific center of surgery; kudaibergen_med@mail.ru; +77027760883

ORCID ID 0000-0002-2725-7530

Conflict of interest:

The authors declare no potential conflict of interest requiring disclosure in this article.

Keywords:

Dysfunction of a mechanical prosthesis, prosthetic thrombosis, pulmonary edema, anticoagulant therapy.

Introduction

Heart defects with valvular dysfunction remain a major focus in cardiology and cardiac surgery, affecting over 100 million people worldwide and contributing significantly to disability and mortality.^{1,2} Surgical intervention, including valve repair or replacement, is the cornerstone of treatment. In recent years, transcatheter techniques for valve repair and replacement have gained widespread adoption due to their minimally invasive nature.

However, all prosthetic heart valves, whether mechanical or biological, are inherently thrombogenic and associated with a risk of complications. These devices necessitate anticoagulant therapy, which may be required for a short or extended duration depending on the type of prosthesis and individual patient factors.

Prosthetic valve dysfunction can arise from multiple causes, including impaired leaflet mobility, incomplete closure, thin-

ning of biological leaflets, alterations in the effective orifice area, or changes in transvalvular pressure gradients.³ The underlying etiologies of prosthetic dysfunction include thrombosis, prosthetic endocarditis with vegetation formation, pannus formation, and leaflet degeneration in biological prostheses.⁴ Notably, the risk of thrombus formation is significantly higher with mechanical prostheses compared to biological ones.⁵ However, the choice of prosthesis type depends on specific patient characteristics and clinical indications, each with distinct advantages and limitations.

This report aims to present a severe complication of thrombosis involving a mechanical mitral valve prosthesis, highlighting the clinical challenges and considerations associated with this condition.

Case presentation

A 44-year-old male chef was urgently admitted to the intensive care unit

presenting with a two-day history of hemoptysis, severe dyspnea at rest, and fever reaching 39.5°C. His medical history revealed degenerative mitral valve insufficiency with chordae rupture, for which he underwent surgical replacement in 2019 using a St. Jude Medical mechanical mitral prosthesis (size 31). Concurrent tricuspid regurgitation was managed with De Vega annuloplasty during the same procedure. The patient had been on long-term warfarin therapy, maintaining therapeutic international normalized ratio (INR) levels. His history was further complicated by cardiac arrhythmias, including paroxysmal bradycardic atrial fibrillation, necessitating the implantation of a dual-chamber pacemaker. In 2022, worsening heart failure was documented, with a left ventricular ejection fraction (LVEF) reduced to 20% and a left ventricular end-diastolic volume (LVEDV) exceeding 200 mL. To address the progressive deterioration, the pacemaker system was upgraded to an implantable cardioverter defibrillator (ICD). Unfortunately, no additional detailed medical history or clinical records were available from the patient or his family.

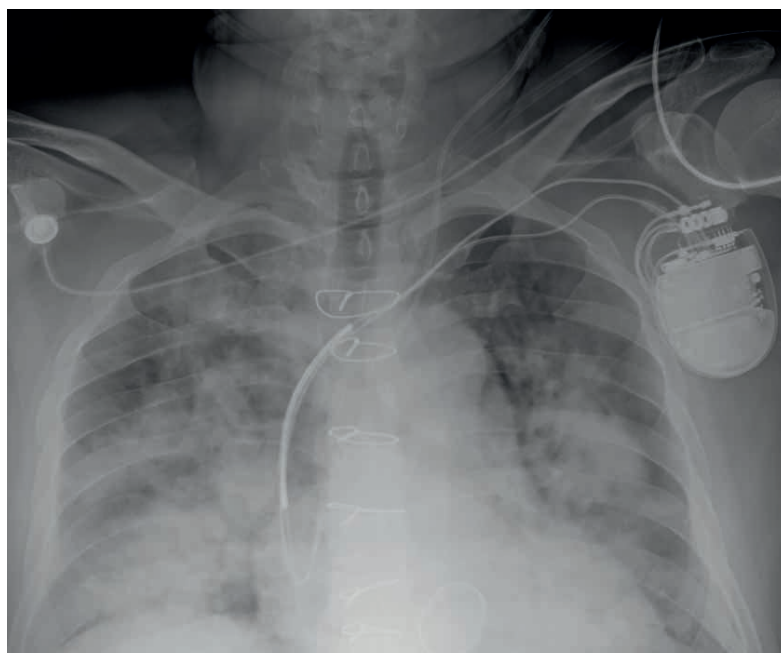
The patient had a long-standing history of grade 3 arterial hypertension and was on a regimen of bisoprolol, spironolactone, and warfarin. Since late 2019, he had also experienced recurrent episodes of community-acquired pneumonia, requiring periodic hospitalizations.

In recent weeks, he was admitted to a therapeutic department where anticoagulation therapy was transitioned from warfarin to subcutaneous low-molecular-weight heparin. However, his condition progressively worsened, culminating in signs of pulmonary edema. A chest X-ray (Figures 1) and computed tomography (CT) scan confirmed pulmonary edema with associated hypostatic changes. Transthoracic echocardiography (TTE) revealed significant mitral valve dysfunction, with a maximum pressure gradient across the valve of 68 mm Hg and a mean gradient of 45 mm Hg. The mobility of the prosthetic mitral valve's moving elements was markedly reduced, and echodense structures were visualized on its ventricular surface, indicative of thrombotic material.

Left ventricular volumetric analysis (M-mode, Teicholz method) demonstrated a left ventricular end-diastolic volume (LVEDV) of 183 mL, end-systolic volume (ESV) of 88 mL, and stroke volume (SV) of 95 mL, with a calculated left ventricular ejection fraction (LVEF) of 51%. Systemic diastolic pressure (SDP) was measured at 70 mm Hg (Figure 2).

A multidisciplinary team reviewed the findings and confirmed the diagnosis of mechanical mitral valve thrombosis, prosthetic dysfunction, and pulmonary edema. Given the severity of the condition, an emergency surgical intervention was deemed necessary.

Figure 1.
The chest X-ray: pulmonary edema



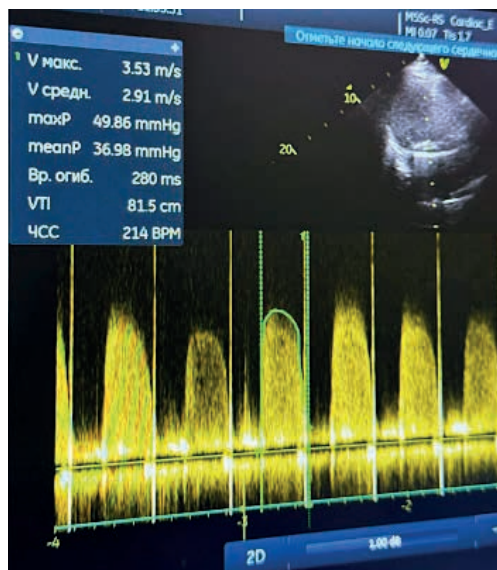
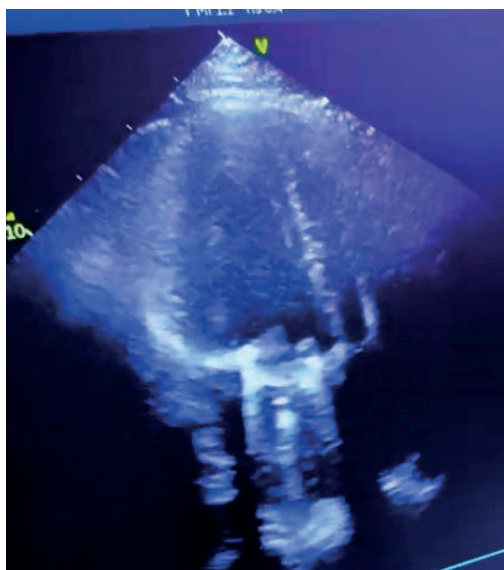


Figure 2. Transthoracic echocardiography before intervention

The surgery commenced with a re-sternotomy. Upon reopening the sternum, extensive adhesive processes were encountered, necessitating a subtotal cardiolysis to free the cardiac structures. Standard cannulation of the ascending aorta was performed, along with separate cannulation of the superior and inferior vena cava. Cardiopulmonary bypass (CPB) was initiated, and the aorta was cross-clamped. Antegrade cold blood cardioplegia was delivered into the aortic root to achieve myocardial protection.

The left atrium was accessed through the Waterstone groove for revision. The left atrial cavity was notably enlarged; however, no thrombotic masses were identified in the left atrial appendage or at the pulmonary vein ostia. During examination of the mitral valve, complete thrombosis of the bi-leaflet mechanical prosthesis was observed (Figures 3-4). Both leaflets were encased in throm-

botic material, comprising both fresh and organized thrombi, which severely impaired the mobility of the prosthetic components (Figures 5-6).

The thrombotic material was meticulously removed (Figure 4), and the dysfunctional prosthesis was explanted (Figure 5). A new St. Jude Medical mechanical prosthesis (size 29) was implanted in the intra-annular position using 14 “P”-shaped sutures with spacers to ensure secure fixation. The left atrium was subsequently closed. Following the release of the aortic clamp, spontaneous cardiac function was successfully restored.

The subsequent stages of the surgery, including weaning from cardiopulmonary bypass, placement of drains, and metal osteosynthesis of the sternum, proceeded without complications. The total duration of cardiopulmonary bypass was 184 minutes, with a cardiac arrest time of 127 minutes.

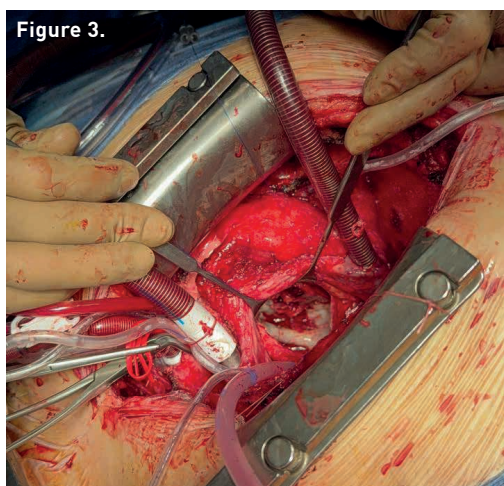


Figure 3.

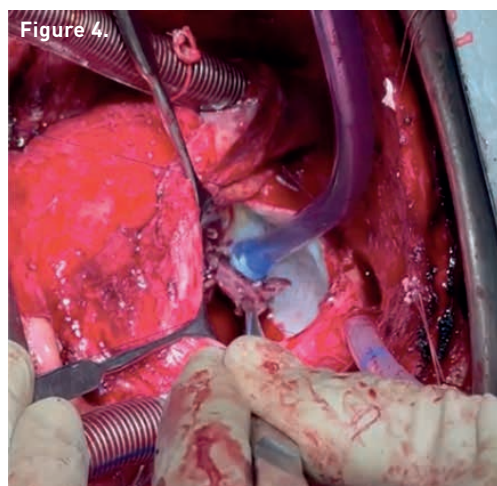


Figure 4.

Figure 3. Thrombosis of the mechanical mitral valve prosthesis

Figure 4. Removal of the platelet concentrate

Figure 5.
Explantation of the mechanical prosthesis

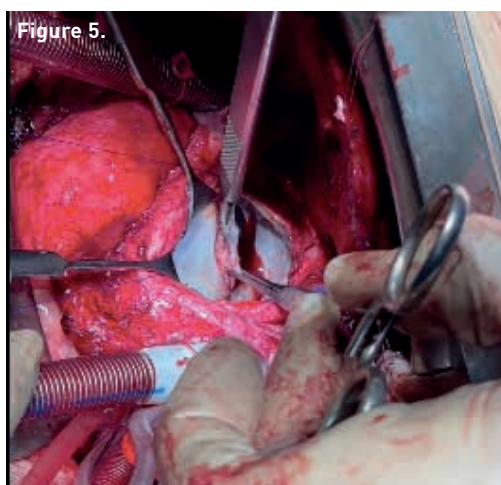
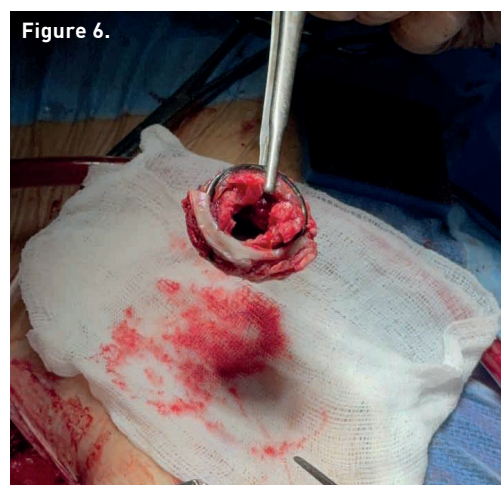


Figure 6.
Dysfunction of prosthesis



After the surgery, the patient was transferred to the intensive cardiac care unit (ICU) on inotropic support with *Nor-epinephrine* 170 ng/kg/min and *Dobutamine* 7 µg/kg/min. The patient's condition was successfully stabilized postoperatively. A transthoracic echocardiogram was performed, showing the following results:

- Mean gradient across the mitral valve prosthesis: 5 mm Hg;
- Maximum gradient: 7 mm Hg;
- Left ventricle: End-diastolic diameter (EDD) 4.8 cm, End-systolic diameter (ESD) 3.2 cm;
- Left ventricular volumes (Teicholz method): End-diastolic volume (EDV) 106 ml, End-systolic volume (ESV) 40 ml, Stroke volume (SV) 66 ml, Ejection fraction (EF) 62% (66% by Simpson's method);
- Systemic diastolic pressure: 42 mm Hg;

There was positive progression in the chest X-ray results, with the resolution of pulmonary edema. The patient continues to receive intensive therapy in the ICU.

Discussion

All artificial heart valve prostheses are thrombogenic, posing significant risks of complications despite their life-saving benefits. Implantation imposes a rigorous treatment regimen on patients, requiring consistent management of risk factors, strict adherence to anti-coagulant therapy, and regular clinical monitoring. Thrombosis of mitral valve prosthesis, while rare with proper therapy, remains a severe and life-threatening complication that demands an individualized approach, particularly in

determining the timing of surgical intervention.⁶ The complexity of this condition stems from its profound implications for systemic circulation, making prompt diagnosis and intervention crucial.

Surgical management, including thrombus removal and prosthetic valve reimplantation, continues to be the cornerstone of treatment. Survival rates correlate with the extent of thrombus involvement, with better outcomes observed in cases identified and managed early. Despite advancements in treatment, no standardized protocol for managing prosthetic valve thrombosis exists, underscoring the importance of case-specific, multidisciplinary team discussions for optimal decision-making.^{7,8}

Emerging evidence on thrombolytic therapy for prosthetic valve thrombosis offers a potential alternative or adjunct to surgical management but requires further validation through robust clinical trials.⁹ In this case, the surgical intervention was executed effectively, addressing the circulatory insufficiency caused by the thrombosis.¹⁰

Limitations. This case highlights multiple contributing factors to the development of mitral valve prosthesis thrombosis. However, significant gaps in clinical data limit a comprehensive understanding of the patient's condition. There is limited information regarding the patient's postoperative anticoagulation management, especially during the first year after mitral valve replacement. Additionally, the adequacy of warfarin therapy during this period is unclear. The presence of atrial fibrillation, ne-

cessitating pacemaker implantation, further compounded the patient's risk of thrombosis. The duration and extent of left ventricular systolic dysfunction also remain poorly defined. Other contributing factors, such as inflammatory lung processes and the transition from warfarin to low-molecular-weight heparin, likely played a role in thrombus formation. Furthermore, the precise factors leading to heart failure at the time of initial treatment and the pharmacological regimen that improves the ejection fraction remain unclear.

What's known? Studies indicate that the risk of thrombus formation is highest within the first three months post-implantation, emphasizing the critical importance of stringent anticoagulant therapy and INR monitoring during this period. Risk stratification tools like the CHA2DS2-VASc score can aid in tailoring management strategies.

What's new? Regular echocardiography evaluation, clinical assessment of thrombotic and bleeding risks and close monitoring allow to decrease of risk. As the number of patients with heart valve prostheses continues to rise, the development of standardized protocols for early risk factor identification, thrombus

prevention, and safe, effective anticoagulation therapy is imperative.

Conclusions

Mitral valve prosthesis thrombosis is a rare but life-threatening complication requiring careful and comprehensive management. The presence of comorbidities such as atrial fibrillation and other implanted devices increases the likelihood of thrombotic events. This case underscores the need for ongoing research and multidisciplinary collaboration to improve outcomes for patients with prosthetic heart valves.

Acknowledgement. The research team would like to thank the individuals who generously shared their time and data, and participated in the study.

Author's contributions. R.B., K.A., I.U., K.S.: Concept, design and control of the research, approval of the final version of the article; T.R., T.A., R.B.: Collection and preparation of data, primary processing of the material and their verification; K.A., I.U.: Statistical processing and analysis of the material, writing the text of the article (material and methods, results); R.B., T.A., T.R., I.U., T.A.: Writing the text of the article (introduction, discussion). All authors approved the final version of the manuscript.

References

- Serban A, Gavan D, Pepine D, et al. Mechanical valve thrombosis: Current management and differences between guidelines. *Trends Cardiovasc Med.* Aug 2024;34(6):351-359. doi:10.1016/j.tcm.2023.07.004
- Writing Committee M, Otto CM, Nishimura RA, et al. 2020 ACC/AHA Guideline for the Management of Patients With Valvular Heart Disease: Executive Summary: A Report of the American College of Cardiology/American Heart Association Joint Committee on Clinical Practice Guidelines. *J Am Coll Cardiol.* Feb 2 2021;77(4):450-500. doi:10.1016/j.jacc.2020.11.035
- Lim WY, Lloyd G, Bhattacharyya S. Mechanical and surgical bioprosthetic valve thrombosis. *Heart.* Dec 2017;103(24):1934-1941. doi:10.1136/heartjnl-2017-311856
- Soria Jimenez CE, Papolos AI, Kenigsberg BB, et al. Management of Mechanical Prosthetic Heart Valve Thrombosis: JACC Review Topic of the Week. *J Am Coll Cardiol.* May 30 2023;81(21):2115-2127. doi:10.1016/j.jacc.2023.03.412
- Ozkan M, Gunduz S, Guner A, et al. Thrombolysis or Surgery in Patients With Obstructive Mechanical Valve Thrombosis: The Multicenter HATTUSHA Study. *J Am Coll Cardiol.* Mar 15 2022;79(10):977-989. doi:10.1016/j.jacc.2021.12.027
- Dangas GD, Weitz JI, Giustino G, Makkar R, Mehran R. Prosthetic Heart Valve Thrombosis. *J Am Coll Cardiol.* Dec 20 2016;68(24):2670-2689. doi:10.1016/j.jacc.2016.09.958
- Ozkan M, Gunduz S, Gursoy OM, et al. Ultraslow thrombolytic therapy: A novel strategy in the management of PROsthetic MEchanical valve Throm-

- bosis and the predictors of outcome: The Ultra-slow PROMETEE trial. *Am Heart J.* Aug 2015;170(2):409-18. doi:10.1016/j.ahj.2015.04.025
8. Vahanian A, Beyersdorf F, Praz F, et al. 2021 ESC/EACTS Guidelines for the management of valvular heart disease: Developed by the Task Force for the management of valvular heart disease of the European Society of Cardiology (ESC) and the European Association for Cardio-Thoracic Surgery (EACTS). *Rev Esp Cardiol (Engl Ed).* Jun 2022;75(6):524. doi:10.1016/j.rec.2022.05.006
 9. Castilho FM, De Sousa MR, Mendonca AL, Ribeiro AL, Caceres-Loriga FM. Thrombolytic therapy or surgery for valve prosthesis thrombosis: systematic review and meta-analysis. *J Thromb Haemost.* Aug 2014;12(8):1218-28. doi:10.1111/jth.12577
 10. Gunduz S, Kalcik M, Gursoy MO, Guner A, Ozkan M. Diagnosis, treatment & management of prosthetic valve thrombosis: the key considerations. *Expert Rev Med Devices.* Mar 2020;17(3):209-221. doi:10.1080/17434440.2020.1733972

COMBINED SURGERY OF LUNG ECHINOCOCCOSIS

Shirtayev B.K., Kaniyev S.A., Ismailova G.N., Yerimova N.Zh.,
Kurbanov D.R., Aitzhanov M.G., Rakhman N.N.

Syzganov National scientific center of surgery

DOI: 10.35805/BSK2024IV004

Shirtayev B.K.

<https://orcid.org/0000-0002-0773-3878>

Kaniyev S.A.

<https://orcid.org/0000-0002-1288-0987>

Ismailova G.N.

<https://orcid.org/0000-0002-7461-4190>

Yerimova N.Z.

<https://orcid.org/0000-0002-0565-5327>

Kurbanov D.R.

<https://orcid.org/0000-0002-0426-9387>

Aitzhanov M.G.

<https://orcid.org/0009-0007-9995-2907>

Rakhman N.N.

<https://orcid.org/0009-0003-0816-8166>

received: 05.12.2024

accepted: 13.12.2024

Author for correspondence:

Shirtayev B.K. -

MD, PhD, the branch manager of thoracic and child surgery department Syzganov National scientific center of surgery,
tel.: +7(705) 7191127,
E-mail address: shirtayevb@gmail.com

Conflict of interest:

The authors declare no potential conflict of interest requiring disclosure in this article.

Keywords:

pulmonary cystic echinococcosis, video-assisted thorascopic echinococcectomy, bilateral echinococcosis, transmedistinal access, combined echinococcosis.

Abstract

Background. Pulmonary cystic echinococcosis, a parasitic disease, is a health care problem in developing countries. In this study, we evaluated outcomes of patients with pulmonary hydatid disease who were treated in our department. Study was performed to compare results of surgical treatment and complications of patients with unilateral or bilateral thoracic and combined pulmonary cystic echinococcosis.

Methods. This cross-sectional analysis of a prospective study was conducted in the Department of Thoracic and Pediatric Surgery, Scientific Center of Surgery, Almaty, Kazakhstan among 598 patients with pulmonary cystic echinococcosis, who had surgical treatment with various surgical methods, depending on the prevalence of echinococcosis, as follows: right lung in 357 (59.5%) patients, left lung in 243 (40.5%) patients, bilateral in 95 (15.8%) patients, and complicated echinococcosis in 317 (52.8%) patients. Length of stay per hospital stay has been decreased ($p < 0.0001$) by video-thorascopic echinococcectomy with the high-energy laser treatment of cyst, than after echinococcectomy by cyst treatment with povidone-iodine. Treatment with formalin presented the longest hospital stay ($p < 0.0001$).

Results. Comparative analysis of patients with uncomplicated and complicated pulmonary cystic echinococcosis showed a high frequency of postoperative complications associated with complicated echinococcosis (OR = 2.2, $p < 0.0001$).

Conclusion. Despite the success of surgical treatment of pulmonary cystic echinococcosis, issues of intraoperative dissemination and safety remain, and treatment success rates can be improved. These factors require further prospective multicenter studies.

Introduction

Pulmonary cystic echinococcosis (PCE) has no clinical presentation and may cause impassable cough, colored sputum, hemoptysis, and fever.^{1,2} X-ray and Computed tomography (CT) can detect lung abscess, bronchoscopy can detect cystic lesion, and serological testing can detect antibody titer to *Echinococcus granulosus*.²⁻⁵ Cystic echinococcosis is the most common type, and represents 95% of the cases. Estimated cases worldwide was 2 to 6 million, and the mortality rate was 2% to 4% per 100,000 world population.⁶

Endemic cystic echinococcosis primarily occurs in Mediterranean countries, Central Asia, North and East Africa, Australia, and South America.^{6,7} Despite of development of new oral anti-parasitic medicines; only surgical approaches were able to prove its effectiveness in the treatment of cystic echinococcosis.

Other important challenges that deserve to study are postoperative complications and recurrent echinococcosis.^{8,9} The purpose of this study is to explore the number of postoperative complications associated with various surgical treatments of complicated and uncomplicated PCE.

Materials and methods

This cross-sectional analysis of a prospective study was conducted in the Department of Thoracic and Pediatric Surgery, Syzganov National Scientific Center of Surgery, Almaty, Kazakhstan from 2018 to 2024. Ultrasound (US) or CT and other complete data available obtained from the patients with primary PCE were included in this review. Adult age ≥ 18 and < 70 years old were also included. Patients referred from any out-patients department or hospitals throughout Kazakhstan were also included. Presence of hydatid cysts, any size on the US or CT, were the indica-

tions for echinocoectomy.

Exclusion criteria were pregnant women, patients with fever and active-pulmonary tuberculosis, HIV positive with HIV symptoms, as well as with primary or secondary lung or liver cancer.

We analyzed treatment results of 598 patients with PCE who were hospitalized in the department of thoracic surgery. Two hundred eighty-three patients had uncomplicated echinococcosis, and 317 patients had complicated echinococcosis, due to festering echinococcosis cysts in the bronchus. Patients ranged in age from 32 to 67 years and included 74 (12.4%) women and 524 (87.6%) men. Data were collected prospectively from the Institutional Echinococcosis Registry.

Ethical approval. The study protocol was approved by our Institutional Local Research Ethics Committee (2023), and the study protocol was developed to conform to the ethical standards of the Declaration of Helsinki. We received informed consent from all participants in the study.

Statistical Analysis. Were conducted with SPSS software version 18.0. Z-sta-

tistic for analysis of main characteristics surgical patients, complications and deaths, Chi-square test for analysis of surgery methods, the odds ratio (OR) for analysis of complications and deaths. A $p < 0.05$ was used to determine significance. Continuous data (hospital stay, days) are presented as mean standard deviation (SD) or median and categorical data are presented as frequency in percentage. Comparisons of patients' characteristics and outcomes were conducted in the 2 patient groups with uncomplicated and complicated cases of PCE.

Results

Combined lesions on lungs and liver was seen in 136 (22.7%) patients, lung and other organs in 40 (6.7%) patients, 22 (3.7%) of them in the lesser sac, 8 (1.3%) of them in the spleen, 6 (1%) of them in the abdomen, and 4 (0.7%) in the greater omentum (Table 1). Unilateral common lesion of the lung with echinococcosis is statistically important, followed by bilateral lesion ($p < 0.0001$), and combined lesion of the lung, liver, and other abdominal organs, ($p < 0.0001$).

Table 1.
Main features

	Unilateral lesion of the lungs		Bilateral lesion of the lungs		Combined lesion of lungs, liver and etc.		Chi-squared	P value
	n	%	n	%	n	%		
Number of patients	327 ^{a,c}	54.7	95 ^{a,b}	15.9	176 ^{b,c}	29.4	44.5* 6.0 29.4*	0.0001 - 0.0001
Right lung	195	59.6	-	-	88	14.7	49.1*	0.0001
Left lung	132	40.4	-	-	32	5.3	14.1*	0.0002
Both lungs	-	-	-	-	12	2	-	-

*Statistical significant difference $p \leq 0.05$. a - comparison between patients with unilateral and bilateral involvement; b - bilateral involvement and combined lungs and extrathoracic involvement; c - unilateral involvement and combined lungs and extrathoracic involvement

Operative procedures. Organ-preserving surgery was performed, which is more

statistically significant ($p \leq 0.0001$) than frequency of lung resection (Table 2).

Table 2.
Organ-preserving surgery consisted of closed echinocoectomy by methods Delbe's, echinocoectomy or lung resection by Bobrov Spasocucotsky's or Vishnevsky's methods

Methods of surgery	Organ-preserving surgery		Lung resection		CI	Chi-squared
	n	%	n	%		
By Delbe	281	47	-	-	-	-
By Bobrov-Spasocucotskii	11	1.8	37	6.2	[17.6; 25.6]	0.3

by Vishnevskii	7	1.0	25	4.2	[17.6; 25.6]	0.3
One stage bilateral thoracotomy with echinococcectomy	23	3.8	-	-	-	-
One stage bilateral video-assisted thorascopicechinococcectomy	30	5	-	-	-	-
One stage bilateral thoracotomy with echinococcectomy with trans mediastinal access	9	1.5	-	-	-	-
Two stage bilateral thoracotomy with echinococcectomy	33	5.5	-	-	-	-
One stage thoracotomy with laparotomy	59	9.9	-	-	-	-
Two stage thoracotomy with laparotomy	84	14.1	-	-	-	-
<i>Fillingacyst</i>						
By Kulakeev	176	2.3	-	-	-	-
With capitonage	43	7.2	-	-	-	-
<i>the treatment of fibrous cyst capsule cavity</i>						
High-energy laser beam	109	18.2	-	-	-	-
Low-frequency ultrasound	97	16.2	-	-	-	-
formalin	180	30.1	-	-	-	-
Povidone-iodine	200	33.4	-	-	-	-
* Statistical significant difference $p \leq 0.05$						

Lung resection was carried out in 23 (3.8%) cases of festering cysts; in 18 (3%) cases of echinococcosis occupying the volume of almost the entire fraction (2 lobes) with irreversible coarse peri focal changes and fibrosis in the surrounding pulmonary tissue; and in

13 (2.2%) cases of echinococcosis with excessive multiplicity lesion of one or 2 lbs. Organ-preserving surgery consisted of Delbe closed echinococcectomy, echinococcectomy or lung resection by Bobrov-Spasocucotsky's or Vishnevsky's methods. (Figure 1.)

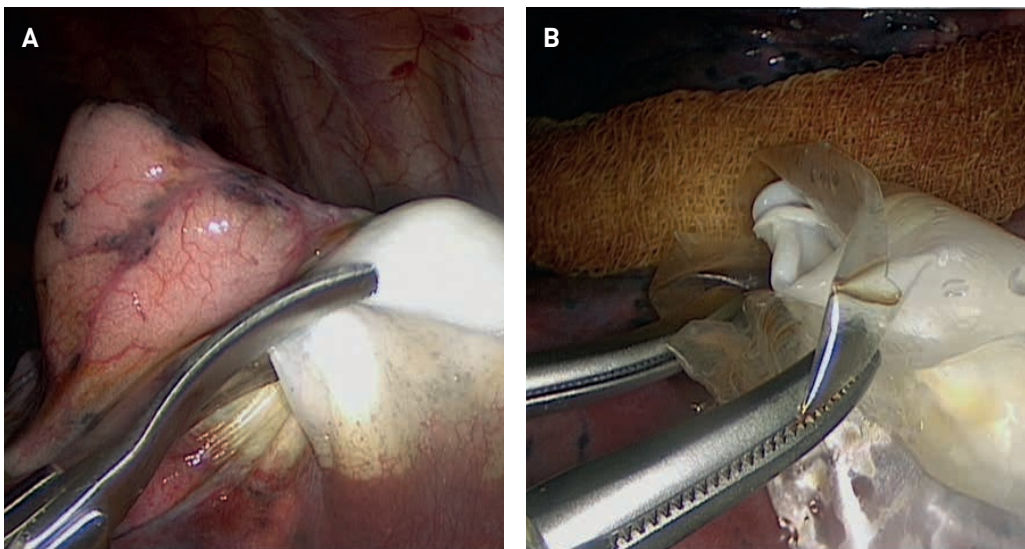
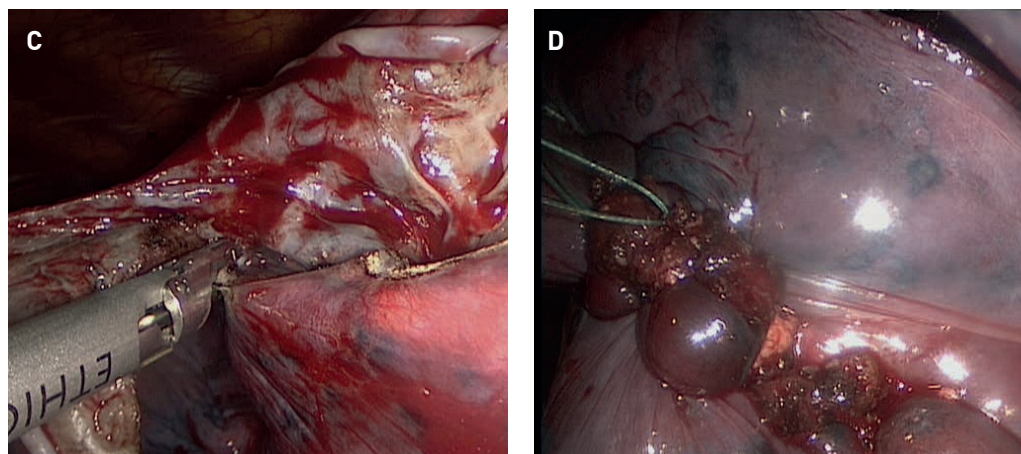


Figure 1. Video-assisted thorascopicechinococcectomy
 A. Opening of the echinococcal cyst fibrous capsule after puncture aspiration of the contents;
 B- Removing chitin membrane;
 C- Excision of the outer fibrous capsule after treatment with 10% povidone-iodine;
 D-capitonage echinococcosis cyst bed.



The treatment of fibrous PCE cyst capsule cavity was performed using a high-energy laser beam or using low-frequency ultrasound. The effectiveness of these methods has been compared to the result of anthelmintic treatment with formalin or povidone-iodine. Filling a cyst of fibrous capsule with vertical half purse-string suture by Kulakeev's method was carried out in 176 cases, 50% of them with PCE complications. Capitonage was carried out through a combination of horizontal and vertical sutures in 21 patients with complicated cysts (12 suppuration, 4 chitin membrane detachments, 2 rupture of cyst into bronchus, one rupture of cyst into the pleural cavity, and 2 pulmonary hemorrhages).

In patients with bilateral echinococcosis adhered to tactics, 2-stage bilateral thoracotomy was performed with an interval of 3, 6, or 8 weeks between them, depending on the severity. In patients with right PCE and upper segment liver right lobe, simultaneous one-stage thoracotomy with diaphragmotomy and echinococcectomy of the lung and liver were performed. In 44 (7.4%) patients with bilateral lesion of the lungs and spleen and liver echinococcosis, after phased thoracotomy with lung echinococcectomy (with an interval of 1 to 2 months between them), next-stage laparotomy was carried out to excise echinococcosis cysts of the abdominal parenchymatous organs. Of these, 27 patients had one-stage surgery; the others had 2-stage surgery with an interval of 4 to 8 weeks between them. In 40 (6.7%) patients with combined PCE and abdominal organs, after thoracotomy and lung echinococcectomy, they

received second-stage laparotomy and echinococcectomy from the lesser sac in 22 (3.7%) patients, from the abdomen in 6 (1%) patients, from the greater omentum in 4 (0.7%) patients, and with a splenectomy in 8 (1.3%) patients. One-stage bilateral video-assisted thoracoscopic echinococcectomy was performed in 30 (5%) patients with PCE. Organ-preserving video-assisted thoracoscopic echinococcectomy is performed under general anesthesia with separate intubation of the bronchi, which allows the surgeon to shut down the lung in the vents on the operative side. The cyst is covered with povidone-iodine wet napkins to prevent inadvertent implantation of scolices or daughter cysts. The pipe tool punctures the cyst through a thoracoport with hydatidic fluid aspirates; without removing the needle, 10% solution of povidone-iodine as scolicidal agent injected (nearly the same amount of the fluid aspirated) for 3 minutes. The fibrous capsule is opened and the chitin membrane is removed. The fibrous capsule cavity is eliminated depending on the size of the application clips or suturing.

A method of removing bilateral echinococcosis cysts of the lungs through transmediastinal access, was developed by our center. In bilateral lung echinococcosis when hydatid cysts located in the upper lobe, and in any part of the other lung, we carry out a one-sided lateral thoracotomy, hydatid cyst removed from one lung, and then performed resection of retrosternal mediastinal pleura, cyst of the upper lobe of the other lung moved to retrosternal mediastinal approach and then performed echinococcectomy. Then 2 pleural cavities

drained by 2 drainage tubes, one tube in the pleural cavity on the side of the thoracotomy, and second drain tube going through mediastinal approach to other pleural cavity, outputting the end of the tube through the chest wall on the side of thoracotomy. The advantages of this method are that the one-stage bilateral echinococcectomy using transmediastinal approach reduces the cosmetic de-

fect and reduces pain. This method was used in 9 (1.5%) patients, who had no postoperative complications.

Postoperative outcomes. A comparative study of the postoperative period features and the long-term results of treatment with a high-energy laser (HEL) were carried out in comparison with the treatment of cyst by formalin or povidone-iodine solutions (Table 3).

	A treatment method of fibrous capsule				Z statistic	P value
	HELB	Povidone - iodine	formalin			
Number of complications	12 (2.0%) ^{a, b}	44 (15.5%) ^{a, c}	94 (29.7%) ^{b, c}	1.5 4.1* 3.2	- 0.0417 -	
Stay in hospital (bed-day)	5.5±0.8 ^{a, b}	16.3±2.0 ^{a, c}	19.4±2.1 ^{b, c}	18.2* 22.6* 8.2*	0.0001 0.0001 0.0001	

* Statistical significant difference $p \leq 0.05$

Table 3. Comparative characteristic of the postoperative period

The worst results were after treatment of fibrous capsule with formalin solution ($p < 0.0417$). The frequency of complications after cyst treatment with HEL and povidone-iodine did not reach a statistically significant difference ($p \geq 0.05$). The treatment method for echinococcosis cyst with 10% povidone-iodine is the most simple, safe, and effective method. Presently in our center, HEL or a 3-time treatment with 10% povidone-iodine results in the cyst drying up; if a patient has an allergy to iodine, we treat the cyst with 70% alcohol.

Length of stay per hospital stay has been decreased ($p < 0.0001$) by video-thoracoscopic echinococcectomy with the HEL treatment of cyst, than after echinococcectomy by cyst treatment with povidone-iodine; finally, treatment with formalin presented the longest hospital stay

($p < 0.0001$).

Complications. We noted postoperative complications in 139 (23.2%) of 598 operated patients. Complications resulted in death in 4 (0.6%) patients. In 45 (16%) of 281 patients with uncomplicated PCE, postoperative complications occurred, including one death from cyst removal with formalin. Complications from PCE occurred in 94 (29.7%) patients of 317 (53%); 3 of these resulted in death. Comparative analysis of patients with uncomplicated and complicated PCE showed a high frequency of postoperative complications associated with complicated echinococcosis (OR = 2.2, $p < 0.0001$). Mortality frequency has a direct relationship with complicated echinococcosis, but this relationship was not statistically significant (Table 4).

	The course of pulmonary cystic echinococcosis				Z	P value
	Uncomplicated	Complicated	OR			
Complications	45 (16.0%)	94 (29.7%)	2.2	3.9*	0.0001	
Deaths	1 (0.2%)	3 (0.5%)	2.7	0.8	-	

* Statistical significant difference $p \leq 0.05$

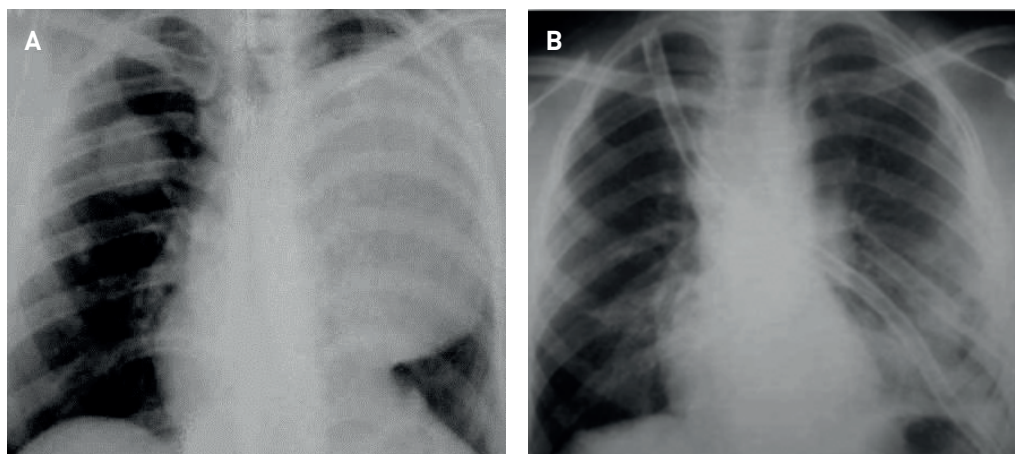
Table 4. Surgical complication frequency

Complications included reactive pleurisy in 47 (7.9%) patients, suppuration of the postoperative wound in 37 (6.2%) patients, bronchial fistula in 15 (2.5%) patients, and pneumonia in 14 (2.3%) patients. Less common

complications were pleural empyema in 8 (1.3%) patients, residual cavities in the lung in 8 (1.3%) patients, pulmonary heart disease in 6 (1.0%) patients, and hemorrhage in 1 (0.2%) patient. (Figure 2)

Figure 2.

Bilateral pulmonary echinococcosis X-ray.
A - before simultaneous two-sided echinococcectomy with transmediastinal access;
B- after simultaneous two-sided echinococcectomy with transmediastinal access



Postoperative complications occurred in 17.6% of patients when applying the method by Delbe and in 18.6% when applying the method by Bobrov-Spasocucotsky. Postoperative complications occurred in 40% of the patients when applying the method by A. Vishnevsky. For patients with uncomplicated PCE, filling a cyst of fibrous capsule with vertical half purse-string Kulakeev suture resulted in postoperative complications in 22.7% of 176 (29.4%) patients. In the method of liquidation of the fibrous capsule, with capitonage carried out through a combination of horizontal and vertical sutures, no postoperative complications occurred during the 1 to 9 months after surgery.

There were no complications in the postoperative period in 9 (1.5%) patients after echinococcectomy via transmediastinal access, despite the extent of the surgical intervention: right-sided lateral thoracotomy, removal of the upper lobe of the right lung echinococcosis cyst, and subsequent removal of the echinococcosis cyst from the liver.

Discussion

Surgical intervention is the only radical method of PCE treatment.^{9,10} Important elements of surgical intervention are the technique of antiparasitic cavity treatment of the fibrous capsule and the elimination of the PCE. The means used in antiparasitic treatment of the cavity must be effective while preserving the surrounding tissues. The elimination of an echinococcosis cyst cavity of the lung should be simple, non-traumatic, and effective, regardless of the cyst size and the disease complications.^{10,11} The prevention of intraoperative dissemination can be achieved by placing gauze

with hypertonic saline solution (20%) or a povidone-iodine solution.¹¹ That's why the search for new, effective and safe methods of the echinococcal cyst cavity treatment of the lung remains relevant.^{12,13} Surgery is compulsory for large cysts that are superficial, infected cysts, and cysts located in vital anatomical sites.^{1,14} The surgery by A.A. Vishnevsky's method is applied in medium, large, and giant cysts when two-thirds of the cyst are above the lung surface and only one third of the cyst volume is in lung parenchyma. Whereas, small bronchiolar fistulas are treated thorough suturing by necessity, but postoperative complications often develop.^{12,15}

Capitonage cystostomy is the preferred method of echinococcosis hydatid treatment. Cystostomy includes aspiration of cyst fluid and eliminating of growing membrane (Barrett's techniques).¹⁶ Capitonage is complete closing of the cyst by suturing the cyst's wall. The method provides extra strength of lung parenchyma and prevents subsequent dissemination through air and formation of empyema.^{17,18}

The primary criteria for lobectomy are cysts involving more than 50% lung lobe; festering cysts that are unresponsive to antibiotic therapy; multiple cysts that are located inside one lobe; and echinococcosis with the bronchiectasis, pulmonary fibrosis, or severe hemorrhage. The method of choice for small and medium cysts, which are located intraparenchymally, and are mostly uncomplicated and cylindrical and conical type, is a method of closed echinococcectomy, according to Delbe.¹⁴

In the case of multiple cysts, priority

should be given to cysts that are more likely to rupture, are of larger size, and may possibly disseminate. Large cysts require certain management of the residual space to avoid postoperative dissemination through air and formation of empyema.^{19,20}

With combined PCE with involvement of abdominal organs, surgery should start from PCE, considering the possibility of high risk for developing pulmonary complications.²¹ An echinococcosis cyst from the opposite lung should be eliminated with bilateral PCE, which allows a one-stage bilateral echinococcectomy of an upper lobe right liver cyst with subsequent elimination of echinococcosis cysts from the liver. The patients with combined bilateral pulmonary lesion and liver and spleen damage are good candidates for cystectomy laparotomy after bilateral phased thoracotomy and echinococcectomy of the lungs.²² In cases of one-stage bilateral echinococcectomy thoracotomy, surgery should be started on the side of the largest cyst or with the largest threat of complications. However, this method is traumatic, and can lead to respiratory failure and increased risks of postoperative wounds in the early postoperative period. Video-assisted thoracoscopic surgery is a useful method for elimination of surface and small or moderate-sized hydatid cysts, with less morbidity compared with the usual surgery method.^{23,24} To reduce surgery-related trauma, reducing the duration of the operation and the postoperative period using a bilateral one-stage sequential videoassisted thoracoscopic echinococcectomy from both lungs is effective.^{23,24} The method of one-stage surgical treatment and 2-stage PCE via transmediastinal access to the eliminated right PCE and liver, through one skin incision with the use of video-assisted thoracoscopic techniques allows the reduction of trauma and the length of treatment, and patients are relieved to avoid the next-stage operations and repeated anesthesia.

This study has revealed significant proportion of complications within patients with complicated course of PCE. One of the limitations of this prospective study is the distance, because patients, with echinococcosis are pretty much about

rural population, its make difficult to patients recruiting, early disease detection and monitoring of them. However, the findings highlighted the common tactic that may guide reduce of postoperative complications level and substantiate the need for further prospective studies.

Limitations. The limitation could be patients with severe comorbid pathology of the cardiovascular system, obesity, etc.

What's known? Pulmonary cystic echinococcosis, a parasitic disease, is a health care problem in developing countries. Pulmonary cystic echinococcosis has no clinical presentation and may cause impassable cough, colored sputum, hemoptysis, and fever. X-ray and Computed tomography can detect lung abscess, bronchoscopy can detect cystic lesion, and serological testing can detect antibody titer to *Echinococcus granulosus*.

What's new? In patients with combined PCE and abdominal organs, after thoracotomy and lung echinococcectomy, they received second-stage laparotomy and echinococcectomy from the lesser sac, from the abdomen, from the greater omentum and with a splenectomy. Also one-stage bilateral video-assisted thoracoscopic echinococcectomy was performed in patients with PCE. In the surgical treatment of echinococcosis of the lungs, preference should be given to endoscopic methods. Their use contributes to faster rehabilitation of patients without compromising the result.

Conclusion

Despite the surgical treatment success of PCE, issues of intraoperative dissemination, safety, and treatment success are still a problem. Through detailed multi-center studies the researchers will be able to best define the complications risk and relapse, choice of optimal strategies for effective surgical treatment.

Acknowledgment. Authors express gratitude to the staff of the Department of Thoracic and Pediatric Surgery of the National Scientific Center named after A.N. Syzganov.

Authors' Contributions. Sh.B., K.Sh., I.G.: Concept, design and control of the research, approval of the final version of the article. Sh.B., K.D., A.M.: Collection

and preparation of data, primary processing of the material and their verification. N.Y., R.N.: Statistical processing and analysis of the material, writing the text of the article (material and methods,

results). Sh.B., I.G., A.M., R.N.: Writing the text of the article (introduction, discussion). All authors approved the final version of the manuscript

Funding. Not funded.

References

1. Kuzucu A, Ulutas H, Reha Celik M, Yekeler E. Hydatid cysts of the lung: lesion size in relation to clinical presentation and therapeutic approach. *Surg Today*. Jan 2014;44(1):131-6. doi:10.1007/s00595-012-0484-2
2. Mao R, Qi H, Pei L, et al. CT Scanning in Identification of Sheep Cystic Echinococcosis. *Biomed Res Int*. 2017;2017:4639202. doi:10.1155/2017/4639202
3. Yaldiz D, Batihan G, Ceylan KC, Yaldiz S, Susam S. Pitfalls in the surgical treatment of undiagnosed lung lesions and cystic pulmonary hydatidosis. *J Cardiothorac Surg*. Oct 27 2022;17(1):275. doi:10.1186/s13019-022-02026-y
4. Sarkar M, Pathania R, Jhobta A, Thakur BR, Chopra R. Cystic pulmonary hydatidosis. *Lung India*. Mar-Apr 2016;33(2):179-91. doi:10.4103/0970-2113.177449
5. Turkoglu E, Demirturk N, Tunay H, Akici M, Oz G, Baskin Embleton D. Evaluation of Patients with Cystic Echinococcosis. *Turkiye Parazitoloj Derg*. Mar 2017;41(1):28-33. doi:10.5152/tpd.2017.4953
6. Gazi U, Beyhan YE, Tosun O, Karasartova D, Cobanoglu U, Taylan-Ozkan A. Evaluation of Th1/Th2/Th17 Balance in Pulmonary Cystic Echinococcosis Patients. *Acta Parasitol*. Aug 27 2024;doi:10.1007/s11686-024-00907-x
7. Gureser AS, Ozcan O, Ozunel L, Boyacioglu ZI, Taylan Ozkan A. [Evaluation of the radiological, biochemical and serological parameters of patients prediagnosed as cystic echinococcosis in Corum, Turkey]. *Mikrobiyol Bul*. Apr 2015;49(2):231-9. Corum'da kistik ekinokokkoz on tanisi ile basvuran hastalarin radyolojik, biyokimyasal ve serolojik analizlerinin degerlendirilmesi. doi:10.5578/mb.8656
8. Mor N, Diken Allahverdi T, Allahverdi E, Tekdogan UY. Retrospective Evaluation of Patients Diagnosed with Cystic Echinococcosis at Kafkas University Faculty of Medicine's Surgical Outpatients Unit. *Turkiye Parazitoloj Derg*. Sep 2018;42(3):196-201. doi:10.5152/tpd.2018.5137
9. Ahmad M, Khan SA, Shah SZ, et al. Effect of size on the surgical management of pulmonary hydatid cyst. *J Ayub Med Coll Abbottabad*. Jan-Mar 2014;26(1):42-5.
10. Tripathy S, Sasmal P, Rao PB, Mishra TS, Nayak S. Cetrimide-chlorhexidine-induced multiorgan failure in surgery of pulmonary hydatid cyst. *Ann Card Anaesth*. Jul-Sep 2016;19(3):557-60. doi:10.4103/0971-9784.185565
11. Eichhorn ME, Hoffmann H, Diemann H. [Pulmonary Echinococcosis: Surgical Aspects]. *Zentralbl Chir*. Oct 2015;140 Suppl 1:S29-35. Pulmonale Echinokokkose: chirurgische Aspekte. doi:10.1055/s-0035-1557808
12. Musaev GK, Sharipov RK, Fatyanova AS, Levkin VV, Ishchenko AI, Zuyev VM. [Echinococcosis and pregnancy: approaches to the treatment]. *Khirurgiia (Mosk)*. 2019;(5):38-41. Ekhinokokkoz i beremennost': podkhody k taktike lecheniia. doi:10.17116/hirurgia201905138
13. Parshin VD, Musaev GK, Mirzoyan OS, Berikkhanov ZG, Khetagurov M. [Giant posttraumatic diaphragmatic hernia in 17 years after rupture of the diaphragm]. *Khirurgiia (Mosk)*. 2019;(4):56-60. Lechenie gigantskoi posttravmaticheskoi diafragmal'noi gryzhi cherez 17 let posle razryva grudobriushnoi pregrady. doi:10.17116/hirurgia201904156
14. Dalal U, Dalal AK, Singal R. Concomitant Lung and Liver Hydatid Cyst Managed as One-Stage Surgery. *Maedica (Bucur)*. Jan 2017;12(1):19-22.
15. Khudaibergenov SN, Abrollov KK, Iba-

- dov RA, et al. [Thoracic echinococcosis complicated by arrosive bleeding from great vessels]. *Khirurgiia (Mosk)*. 2016;(11. Vyp. 2):46-51. Ekhnokokkoz grudnoi polosti, oslozhnennyi arrozionnym krovotecheniem iz krupnykh sosudov. doi:10.17116/hirurgia201611246-51
16. Aldahmashi M, Alassal M, Kasbi, Elra-khaway H. Conservative Surgical Management for Pulmonary Hydatid Cyst: Analysis and Outcome of 148 Cases. *Can Respir J*. 2016;2016:8473070. doi:10.1155/2016/8473070
17. Akcam AT, Saritas AG, Dalci K, Ulku A. The usefulness of drainage-internal capitonage with/without selective bile duct repair technique for liver hydatid cyst. *Ann Surg Treat Res*. May 2021;100(5):270-275. doi:10.4174/astr.2021.100.5.270
18. Punia RS, Kundu R, Dalal U, Handa U, Mohan H. Pulmonary hydatidosis in a tertiary care hospital. *Lung India*. May-Jun 2015;32(3):246-9. doi:10.4103/0970-2113.156241
19. Arega G, Kebede RA, Woldeselassie HG, Lingerh T, Yayeh T. Bilateral Large Pulmonary Hydatid Cyst: A Rare Presentation in a Young Child from Ethiopia. *Pediatric Health Med Ther*. 2022;13:279-282. doi:10.2147/PHMT.S374091
20. Anari S, Goli R, Faraji N, Rahimi K, Babamiri B, Zare F. Surgical excision for gigantic bilateral pulmonary hydatid cyst in a 14-year-old adolescent: A case report study. *Int J Surg Case Rep*. Aug 2023;109:108548. doi:10.1016/j.ijscr.2023.108548
21. Datta P, Sharma B, Peters NJ, Khurana S, Sehgal R. Bilateral Pulmonary Hydatid Cyst in a Young Child: A Rare Case Report from North India. *J Lab Physicians*. Sep 2022;14(3):348-350. doi:10.1055/s-0042-1742420
22. Lahroussi M, Khattabi WE, Souki N, Jabri H, Afif H. [Bilateral pulmonary hydatid cyst]. *Pan Afr Med J*. 2016;24:280. Kyste hydatique pulmonaire bilaterale. doi:10.11604/pamj.2016.24.280.7700
23. Ma J, Wang X, Mamatimin X, et al. Therapeutic evaluation of video-assisted thoracoscopic surgery versus open thoracotomy for pediatric pulmonary hydatid disease. *J Cardiothorac Surg*. Aug 5 2016;11(1):129. doi:10.1186/s13019-016-0525-9
24. Zhou P, Yu W, Zhang W, Ma J, Xia Q, He C. Chronic obstructive pulmonary disease-associated expiratory central airway collapse: current concepts and new perspectives. *Chest*. Nov 21 2024;doi:10.1016/j.chest.2024.11.015

CURRENT STATUS OF THE PROBLEM OF PREVENTION OF POST-NEOPLASTIC VENTRAL HERNIAS

Moshkal K.A., Jainakbayev N.T., Madyarov V.M.

Kazakh-Russian Medical University, Almaty

DOI:10.35805/BSK2024IV005

Moshkal K.

<https://orcid.org/0009-0004-5758-6919>

Jainakbayev N.T.

<https://orcid.org/0000-0002-0579-8109>

Madyarov V.M.

<https://orcid.org/0000-0002-5218-0694>

received: 22.11.2024

accepted: 13.12.2024

Author for correspondence:

Moshkal K.

PhD student at the Department

of Surgery with a course in

Anesthesiology and Reanimatology,

Kazakhstan-Russian Medical

University.

E-mail: dr.kazhybek_askarbekuly@inbox.ru

Conflict of interest:

The authors declare no potential conflict of interest requiring disclosure in this article.

Keywords:

Postoperative ventral hernia, prophylaxis, abdominal surgery, inguinal hernias, pathological process, matrix metalloproteinases.

Abstract

Background. At the current stage of surgical development, the problem of prevention of postoperative ventral hernias after abdominal surgeries remains unsolved. The research aims to identify the most effective approaches to the prevention of postoperative ventral hernias and to improve surgical treatment outcomes.

Methods. A systematic analysis of existing publications, scientific articles, and clinical guidelines focused on the prevention and treatment of postoperative ventral hernias after abdominal surgeries will be conducted. Special attention will be paid to studies describing various surgical plastic techniques and the application of biological materials.

Results. To systematize existing methods for the prevention and treatment of postoperative ventral hernias by analyzing their effectiveness and safety. To identify the most suitable surgical techniques and materials that reduce the risk of developing postoperative ventral hernias. To highlight the need for further research in the application of biological materials and new technologies in the prevention and treatment of postoperative ventral hernias.

Conclusion. New technologies and materials, such as biocompatible meshes and antimicrobial sutures, have the potential to enhance treatment outcomes. However, systematic and standardized prevention and diagnostic methods are essential for equipping surgeons to mitigate postoperative ventral hernias risk. Research on collagen status, its various types in connective tissue, and new diagnostic methods will be crucial for improving patient quality of life and reducing surgical risks.

Introduction

In herniology, postoperative ventral hernias (POVH) occupy a special place. In abdominal surgery, POVH accounts for 20–26% of all external abdominal hernias and ranks second in frequency after inguinal hernias. The merits of laparoscopic (LVHR) and open preperitoneal ventral hernia repair (OPPVHR) have been debated for more than 20 years. Our aim was to determine perioperative and long-term outcomes in large hernias. Despite modern advances in surgery, more than 5% of all laparotomies are complicated by the development of POVH.¹⁻³ The incidence of POVH following emergency surgeries reaches 18.1–68.4%, while after elective surgeries, it ranges from 4.0–31.5%.^{4,5}

The frequency of POVH depends on the type of surgical intervention. For instance, after appendectomy, POVH oc-

curs in 6% of cases, after gastric surgeries in 10%, after cholecystectomy in 14%, following extensive laparotomies in 20%, and after midline laparotomy in 7–24% of cases. The potential benefits of laparoscopic surgery for ventral hernias in patients with a BMI greater than 35 kg/m² should be evaluated. The suggested technique is both standardizable and straightforward to replicate. Regarding complications, both in the short term (such as perforations, renal and pulmonary failure, and cardiovascular events) and in the long term (including recurrences, wound infections, and seromas), our findings support the recommendation of a minimally invasive approach for nearly all patients with abdominal wall defects.⁶⁻⁸

The significance of this issue is underscored not only by its medical ramifications, which have been emphasized by numerous authors in recent litera-

ture, but also by its socio-economic dimensions. In this context, the economic impact of hernia treatment should not be overlooked, as it entails considerable annual financial commitments for both inpatient care and outpatient rehabilitation services. Addressing this issue effectively is crucial for improving health outcomes and managing healthcare costs more efficiently.^{5,9,10}

In Germany, around 200,000 hernia repairs are conducted annually, while the figure is approximately 770,000 in the United States. Kazakhstan performs about 80,000 hernia repairs each year. In the U.S., the majority of hernia repairs (80-90%) are carried out as outpatient procedures, with 90% of these surgeries being open herniorrhaphies utilizing mesh. Quality control measures encompass documenting complications, recurrence rates, and patients' quality of life.¹¹

Postoperative ventral hernias are essentially a consequence of surgical procedures, infectious complications (such as wound infections), and sometimes defects in surgical techniques (e.g., suture cutting through the aponeurosis, eventration). They may also result from connective tissue structural changes in certain patient groups.^{12,13}

The vast majority of researchers today agree that POVH should not merely be regarded as an isolated pathological process (i.e., the protrusion of abdominal contents through acquired defects in various parts of the abdominal wall following laparotomies for abdominal organ diseases). Instead, they are increasingly viewed as a distinct polyetiological condition.¹⁴ This condition includes dysfunctions of internal organs, significant impairment of respiratory and cardiovascular systems, alterations in the structure and function of the muscular-aponeurotic structures of the abdominal wall, abdominal organ dystopia, pronounced cosmetic defects, and a considerable reduction in the patient's quality of life.

The introduction of aseptic and anti-septic techniques into clinical practice, improvements in postoperative wound closure methods, and the use of new suture materials at the turn of the 19th and 20th centuries reduced the incidence of postoperative ventral hernias to 10%.¹⁵⁻¹⁷ However, the increase in the number of

abdominal surgeries, including simultaneous, extensive, combined, and repeated operations on abdominal organs, the expansion of intervention volumes, and the predominance of elderly and senile patients among the operated have led to a noticeable rise in POVH cases.¹⁸⁻²⁰ This makes the prevention and treatment of POVH one of the most complex and urgent problems in modern surgery.²¹⁻²³

The objective of this study is to analyze the current state of the problem of preventing postoperative ventral hernias after abdominal surgeries, as well as to evaluate various plastic surgery methods and the use of biological materials as surgical patches. The research aims to identify the most effective approaches to the prevention of POVH and to improve surgical treatment outcomes.

Materials and methods

A systematic analysis of existing publications, scientific articles, and clinical guidelines focused on the prevention and treatment of postoperative ventral hernias after abdominal surgeries will be conducted. Special attention will be paid to studies describing various surgical plastic techniques and

Source inclusion criteria:

- Studies focused on the surgical treatment of postoperative ventral hernias.

- Articles containing data on the frequency of recurrences, complications, and outcomes of various hernioplasty methods.

- Publications from the last 10 years monitoring the techniques of POVH surgery and their effects.

Source exclusion criteria:

- Studies that do not address issues of prevention and treatment methods for POVH.

- Articles unrelated to the fields of cardiology or surgery.

- Works published more than 10 years ago or not peer-reviewed in scientific journals.

These criteria will help systematize existing research and focus on the most relevant and significant works that contribute to the understanding and improvement of prevention and treatment of POVH.

Results

There are many classifications of

POVH. Currently, the most widely used system, adopted at the 21st International Congress of Herniologists in Madrid (1999), is the SWR-classification based on localization, hernia defect size, and recurrence frequency. By localization, hernias are categorized as M (midline), L (lateral), and ML (combined). By hernia defect diameter: W1 (up to 5 cm), W2 (5-10 cm), W3 (10-15 cm), and W4 (over 15 cm). By recurrence frequency, classifications include R1, R2, and R3.

At the modern stage, there is no consensus on solving the problematic issues of surgical treatment of postoperative ventral hernias,²⁴ and the issue of preventing their development remains unresolved. This is largely due to the frequency of their occurrence. Currently, there are over 200 types of hernioplasty for POVH, with recurrence rates ranging from 14% to 50%, reoperations from 20% to 64%, complications up to 25%, and mortality approaching 3%.^{24,25} Moreover, in patients with large and giant ventral hernias, postoperative mortality ranges from 3% to 7%. Ventral hernias affect approximately 25% of the population. Roughly one-third of all hernia repair surgeries performed in the United States are due to ventral hernias, while two-thirds are for primary hernias and one-third for postoperative hernias. Most small abdominal wall defects are asymptomatic, but even in these cases, surgical intervention is often considered appropriate to prevent acute life-threatening complications, such as acute obstruction or strangulation.²⁶

However, attempting to create a duplication from altered aponeurotic tissue is not justified. Suturing the aponeurosis "edge-to-edge" without additional reinforcement of the anterior abdominal wall with synthetic prostheses in cases of medium-sized, large, and giant hernias does not provide effective results, as the existing tissue deficit prevents closing the hernial defect without tension. This tension, in turn, is associated with tissue ischemia and increased intra-abdominal pressure.^{27,28}

The recurrence rate after autoplasy with local tissues ranges from 20% to 63%, while it is 8% to 30.3% for prosthetic methods.²⁹⁻³¹ Many researchers argue that unsatisfactory treatment outcomes

negatively affect the quality of life.^{26,32} The main causes of poor outcomes in autoplasy include significant dystrophic and scar changes in the area of the hernial defect and the surrounding musculo-aponeurotic framework, progressive rigidity of the abdominal wall, which significantly impacts the formation of connective tissue at the surgical site and reduces its strength. Additionally, unsatisfactory outcomes in surgical treatment of POVH are often linked to an inadequate choice of hernioplasty technique.³³⁻³⁵ Furthermore, hernia defect repair using local tissues reduces the abdominal cavity volume, leading to increased intra-abdominal pressure.³⁶

This not only increases the strain on the tissues in the surgical area but also negatively impacts hemodynamics and respiratory function. Consequently, prolonged preoperative preparation and intensive prevention of postoperative complications become necessary, significantly extending the patient's hospital stay. Surgical practice has shown that repairing large hernial defects using local tissue does not guarantee consistent long-term outcomes.

According to the European Hernia Society (EHS), the advent of endovideosurgical methods for treating postoperative ventral hernias has led to a division of surgical approaches into two fundamental directions: 1. Open techniques for anterior abdominal wall repair (open hernia repair), and 2. Repair of the anterior abdominal wall using video-laparoscopic technologies (laparoscopic ventral hernia repair).³⁷⁻³⁹

With the introduction of laparoscopic methods for treating POVH, early postoperative outcomes have improved, and patients' quality of life has increased.⁴⁰⁻⁴² The IPOM technique involves the primary closure of the hernial defect using synthetic material as a patch via video-laparoscopic technologies. In the IPOM+ method, intraperitoneal closure of the hernial defect is achieved using transfascial and transaponeurotic sutures. Additionally, the peritoneum is reinforced with an am shim plant.³⁷⁻³⁹

One of the main challenges in laparoscopic repair of the anterior abdominal wall is the method of mechanical fixation of the mesh implant to the anterior

abdominal wall from the abdominal cavity side. The use of video-laparoscopic technologies has both positive and negative aspects.

Advantages include a smooth postoperative period, rapid patient rehabilitation, the ability to perform simultaneous surgeries, and the repair of multiple abdominal wall hernias in one procedure.

Disadvantages include the high cost of composite, biologically derived, and combined mesh implants, as well as specific (local) complications such as intestinal injury, development of enteric fistulas, adhesive bowel obstruction, and complications associated with creating a pneumoperitoneum. Additionally, contraindications to laparoscopic abdominal wall repair prevent its adoption as the gold standard technique.⁴³⁻⁴⁵

The development and widespread use of tension-free hernioplasty with synthetic materials have significantly reduced the recurrence rate of postoperative ventral hernias to 5%.²⁵ However, the use of bioincompatible synthetic polymer mesh implants for hernioplasty in patients with large POVH has led to a sharp increase in the rate of infectious complications related to the surgical wound.^{46,47}

The incidence of purulent-inflammatory complications of surgical wounds reaches up to 19% when using polymer mesh implants.⁴⁸⁻⁵⁰

The primary task of the operating surgeon is to prevent the formation of postoperative ventral hernias. While the etiological factors are clearly defined, there is no universally established action algorithm despite existing preventive methods.⁵¹ According to several authors, current POVH prevention strategies are pursued in four main directions.

The first and most thoroughly studied approach is the prevention and treatment of complications in the early postoperative period. During abdominal surgeries, strict adherence to aseptic and antiseptic principles is essential to prevent infectious material from entering the surgical wound, along with meticulous hemostasis.^{2,52,53}

The necessity of using incision drapes to protect the surgical field is currently debated. Surgeons rely on such drapes

to protect the wound from contamination throughout the surgery. However, a randomized clinical study by *Webster J. et al.*⁵⁴ found that using standard drapes actually increased wound infection rates compared to surgeries conducted without them. Thus, the effectiveness of incision drapes as a preventive method for postoperative hernias remains controversial.

For abdominal surgeries, a rational choice of surgical access is crucial, along with layer-by-layer suturing of the wound using biocompatible suture material. It is essential to avoid severing nerve trunks, unnecessary drainage, or packing of the abdominal cavity through the wound. In the early postoperative period, factors that elevate intra-abdominal pressure, such as vomiting, coughing, urinary retention, and abdominal distension, should be mitigated, as they exert excessive stress on abdominal wall sutures, often leading to wound dehiscence.

Measured compression of the wound using an elastic, breathable bandage helps to reduce suture stress and promotes the formation of a robust postoperative scar.⁵⁵ While some surgeons deem wearing a bandage mandatory in the postoperative period,² others argue that bandages have no significant effect on reducing the occurrence of wound dehiscence or hernia formation.⁵⁶

The second approach to preventing postoperative ventral hernias involves stimulating reparative wound processes, which requires the prior correction of conditions such as hypoproteinemia, anemia, vitamin deficiencies, and candidiasis. In the early postoperative period, the use of glucocorticoids, sulfonamides, and antibiotics in rational doses is recommended. However, these medications may also suppress reparative processes. Some researchers suggest introducing fibrinogen, cryoprecipitate, or bone marrow cells into the subaponeurotic, interaponeurotic, or intermuscular layers of the wound during the reparative phase. This technique helps to induce early fibroplastic activity and supports the formation of a strong connective tissue scar adapted to specific conditions.⁵⁷

The third strategy for POVH prevention is optimizing laparotomy wound

closure techniques using local tissues. To date, there is no consensus on the most effective method for laparotomy wound closure. Moreover, the success of surgical interventions significantly depends on the properties of the suture materials used. Ideal suture materials should feature a smooth surface, biocompatibility, favorable handling characteristics (such as softness, flexibility, and minimal memory effect), a low wicking effect, high resistance to infections, ease of use and sterilization, and tensile strength that surpasses tissue strength throughout all healing stages. Monofilament, nonabsorbable synthetic sutures meet these requirements.

A promising innovation in surgical practice is the introduction of biologically active suture materials that incorporate substances capable of exerting biological effects when implanted into tissues. Antimicrobial sutures containing the antiseptic triclosan are among the most commonly used internationally. Studies conducted both *in vitro* and *in vivo* have demonstrated their significant and prolonged effectiveness against a broad spectrum of microorganisms.²

Domestic suture materials incorporating the antibiotic doxycycline and the fluoroquinolone drug ciprofloxacin have also demonstrated high antimicrobial activity. In recent years, Russia has begun using suture materials not only with antimicrobial properties but also capable of stimulating regenerative processes. Tissue repair stimulation is achieved by introducing organic compounds containing germanium (Ge) into the suture coating. These suture materials, combining antimicrobial and reparative activities, have been shown to reduce the incidence of abdominal wall wound infections by half compared to the control group where capron sutures were used.⁶

Another important factor in preventing POVH is the suturing technique.⁵⁰ For closing anterior abdominal wall wounds, continuous, interrupted, and combined suture methods are used. Studies indicate that continuous sutures have advantages over interrupted sutures, such as shorter closure time and simpler technique. Both domestic and international surgeons have proposed modifications to existing methods of closing

abdominal wall wounds using local tissues. These modifications include creating aponeurosis duplication, applying two-layer buried sutures, figure-eight sutures, and retention sutures.⁴⁹

However, any method of autoplasmic abdominal wall repair fails to reduce POVH rates significantly, as they do not address the underlying changes in the abdominal wall, such as flaccidity, muscle atrophy, and degenerative processes in aponeurotic structures. The preoperative weakness of the abdominal wall is often exacerbated after surgical intervention.⁴³

The fourth approach in preventing the development of post-operative ventral hernia is primary closure of the laparotomy wound with a mesh endoprosthesis. This direction is the least studied but is considered the most promising. In Russia, most surgeons are cautious about this approach, believing that the primary causes of POVH are defects in surgical technique when suturing the abdominal wall or postoperative wound infections. The first publications on preventive endoprosthetics appeared in foreign literature in the 1970s and 1980s, continuing until the mid-2000s. This technology for reinforcing the abdominal wall was episodically used in coloproctology to prevent parastomal hernia, in vascular surgery following a midline laparotomy for abdominal aortic aneurysm, and in abdominal surgery for elderly and obese patients.

The main subject of discussion is the indication criteria for preventive endoprosthetics of the abdominal wall. In the works of foreign authors, there is no systematic approach for determining the indications for preventive endoprosthetics of the abdominal wall. This gap was addressed in studies by Russian surgeons, who proposed a scale for quantitatively assessing the risk factors for POVH development.²

Despite the large number of proposed methods for plastic surgery of the anterior abdominal wall, the results of surgical treatment of ventral hernias remain unsatisfactory. To date, none of the surgical techniques has achieved a complete absence of recurrences. Consequently, the issue of surgical treatment of ventral hernias remains relevant today. It is noteworthy that most stud-

ies are focused on methods of surgical treatment of ventral hernias, and there are no significant alternatives to the use of prosthetic materials at the current stage of herniology development; the use of prosthetic materials by most domestic and foreign surgeons is accepted as an axiom. Unfortunately, the issues related to the prevention of ventral hernias are insufficiently studied. There is no complete and organized literature on this problem.^{43,57-59}

Recent scientific achievements have helped establish the etiopathogenetic mechanisms of the occurrence and progression of ventral hernias within the framework of two main theories: biochemical and biomechanical.^{5,9,10,60} The biochemical concept of hernia formation and recurrence is based on complex changes in collagen synthesis, which lead to a decrease in the mechanical strength of connective tissue.⁶¹ One of the factors contributing to the development of anterior abdominal wall hernias is hereditary connective tissue disorders (HCTD), which are primarily caused by mutations in the genes responsible for the synthesis or breakdown of extracellular matrix components. HCTDs represent a heterogeneous group of diseases caused by genetic defects in the synthesis and/or breakdown of extracellular matrix proteins or disruptions in the morphogenesis of connective tissue, being one of the factors that promote the development of anterior abdominal wall hernias. This primarily concerns collagen and matrix metalloproteinases (MMPs).⁶²

Practically all signs of hereditary connective tissue disorders can manifest as an isolated defect of connective tissue or as a manifestation of systemic hereditary pathology and the action of defective genes. Moreover, in older age groups, some phenotypes associated with HCTD may be related to aging processes, while the expression of others may decrease with age. This is precisely why additional instrumental, molecular-genetic, or other special studies are necessary to establish a diagnosis. Of particular interest in this regard are the results of studies on the levels of fibrillar collagens (types I and III) and matrix metalloproteinases (MMP) in patients

with ventral hernias.³⁰

By emphasizing the systemic nature of collagenopathy in patients with ventral hernias, researchers often overlook the role and influence of local changes at the site of the hernia defect on the pathology of connective tissue metabolism. It is known that changes in the structure of connective tissue occur, in part due to disrupted collagen metabolism, the ratio of collagen types in connective tissue, and the resulting decrease in the mechanical properties of the aponeurosis.⁶² There are some scientific reports from both foreign and domestic authors indicating that a reduction in the amount of type I collagen and changes in the ratio of different collagen types significantly affect the development of ventral hernias.^{30,63} Therefore, it is reasonable to seek methods of prevention and preoperative diagnosis of the likelihood of developing a ventral hernia through techniques for determining collagen in connective tissue.

At the current stage of surgical development, the issue of preventing ventral hernias after abdominal operations remains unresolved. The main question is the choice of surgical technique for ventral hernias at various locations and the use of biological materials as plastic materials, which creates a need for expanded research in this area. In this regard, it is reasonable to seek methods for the prevention and preoperative diagnosis of the likelihood of developing ventral hernias through techniques for determining collagen and studying the ratio of different collagen types using polarization microscopy.

Discussion

Many issues related to the surgical treatment of postoperative ventral hernias remain unresolved to this day. The high frequency of recurrences, reoperations, and complications indicates the need for a deeper study of prevention methods and the improvement of surgical techniques. Despite the existence of numerous hernioplasty techniques, the effectiveness of various approaches remains questionable, and the quality of life for patients is often below expectations. This highlights the clear need for optimizing the choice of surgical methods, emphasizing such an important aspect as the condition of the connective

tissue in patients, including hereditary disorders and collagen biochemistry.^{2,57}

Modern research confirms that the state of the tissues in the area of the hernial gates and the presence of dystrophic changes affect the success of surgeries. Special attention should be paid not only to the choice of plastic approach but also to the implementation of advanced technologies, such as laparoscopic methods. The high cost of plastic prostheses and the risk of subsequent infectious complications also remain significant concerns.^{9,32,55}

It is essential to recognize that the prevention of POVH involves a multi-level approach: from the appropriate selection of suture materials to adequate preoperative preparation and the mastery of new treatment methods. The strategy for preventing the development of POVH requires the application of both traditional and innovative research aimed at assessing the condition of collagen and the metabolism of connective tissue.^{6,28}

Limitations. The use of data from publications spanning a wide time range may have led to variations in approaches and treatment standards. The absence of systematic clinical studies to verify the proposed methods for POVH prevention in local conditions. A lack of data on the long-term outcomes of using biological materials and new technologies in surgical practice.

What's known? According to published data, recurrence rates after autoplasty range from 20% to 63%, while prosthetic methods reduce this rate to 8–30.3%. The use of laparoscopic treatment methods improves early postoperative outcomes but is associated with high costs and localized complications.

What's new? Our study systematized current approaches to the prevention and treatment of POVH, highlighting the promise of using biocompatible meshes and antimicrobial suture materials. The importance of assessing collagen status and connective tissue condition for predicting recurrence risk was also identified.

Conclusion

Despite the progress in surgery, the problem of preventing postoperative ventral hernias remains relevant. The variety of hernioplasty methods demonstrates both achievements and limitations, necessitating further research. Key areas of focus should be on developing effective prevention strategies aimed at understanding the biochemical and mechanical processes that lead to the development and recurrence of hernias.

The implementation of new technologies and materials, including biocompatible meshes and antimicrobial sutures, can significantly improve treatment outcomes. However, clear systematization and standardization of prevention and diagnostic methods are required to provide surgeons with tools to reduce the risk of POVH formation. Studies aimed at examining the condition of collagen, its ratio of different types in connective tissue, as well as the development of new diagnostic methods, may become key to improving the quality of life for patients and reducing risks in surgical practice.

The issue of using synthetic materials in reconstructive operations on the abdominal wall is also awaiting a complete resolution. The true path to success lies in the prevention of postoperative hernias, the identification of patients with hernias, active monitoring of them, and timely surgery”

Acknowledgements. The research team expresses its gratitude to the staff of the multidisciplinary surgery department, operating unit, and medical archive of City Clinical Hospital 1 for their assistance in data collection.

Authors' Contributions. K.M, J.N., M.V.: Conceptualization, research design, and manuscript approval. K.M: Data collection, primary material processing, and validation. J.N.: Statistical analysis and preparation of the material and methods section. M.V.: Drafting and revising sections of the manuscript, including the introduction and discussion. All authors reviewed and approved the final version of the manuscript.

Funding. The authors declare that there was no funding for the study.

References

1. Shao JM, Deerenberg EB, Elhage SA, et al. Are laparoscopic and open ventral hernia repairs truly comparable?: A propensity-matched study in large ventral hernias. *Surg Endosc.* Aug 2021;35(8):4653-4660. doi:10.1007/s00464-020-07894-w
2. Sukhovatykh BS, Valuyskaya NM, Pravednikova NV, Gerasimchuk EV, Mutova TV. [Prevention of postoperative ventral hernias: current state of the art]. *Khirurgiia (Mosk).* 2016;(3):76-80. doi:10.17116/hirurgiia2016376-80
3. Li J, Wu L, Shao X. Impact of body fat location and volume on incisional hernia development and its outcomes following repair. *ANZ J Surg.* May 2024;94(5):804-810. doi:10.1111/ans.18873
4. Wu XW, Yang DQ, Wang MW, Jiao Y. Occurrence and prevention of incisional hernia following laparoscopic colorectal surgery. *World J Gastrointest Surg.* Jul 27 2024;16(7):1973-1980. doi:10.4240/wjgs.v16.i7.1973
5. Fan BH, Zhong KL, Zhu LJ, Chen Z, Li F, Wu WF. Clinical observation of extraction-site incisional hernia after laparoscopic colorectal surgery. *World J Gastrointest Surg.* Mar 27 2024;16(3):710-716. doi:10.4240/wjgs.v16.i3.710
6. Lee L, Abou-Khalil M, Liberman S, Boutros M, Fried GM, Feldman LS. Incidence of incisional hernia in the specimen extraction site for laparoscopic colorectal surgery: systematic review and meta-analysis. *Surg Endosc.* Dec 2017;31(12):5083-5093. doi:10.1007/s00464-017-5573-2
7. Kim M, Wall MM, Li G. Risk Stratification for Major Postoperative Complications in Patients Undergoing Intra-abdominal General Surgery Using Latent Class Analysis. *Anesth Analg.* Mar 2018;126(3):848-857. doi:10.1213/ANE.0000000000002345
8. Amatucci C, Cesari M, Nardi P, et al. Laparoscopic treatment for ventral hernia in obese patients. *Ann Ital Chir.* 2022;93:689-697.
9. Ortega-Deballon P, Renard Y, de Launay J, Lafon T, Roset Q, Passot G. Incidence, risk factors, and burden of incisional hernia repair after abdominal surgery in France: a nationwide study. *Hernia.* Aug 2023;27(4):861-871. doi:10.1007/s10029-023-02825-9
10. Udayasiri DK, Skandarajah A, Hayes IP. Laparoscopic Compared With Open Resection for Colorectal Cancer and Long-term Incidence of Adhesional Intestinal Obstruction and Incisional Hernia: A Systematic Review and Meta-analysis. *Dis Colon Rectum.* Jan 2020;63(1):101-112. doi:10.1097/DCR.0000000000001540
11. Jensen KK, Krarup PM, Scheike T, Jorgensen LN, Mynster T. Incisional hernias after open versus laparoscopic surgery for colonic cancer: a nationwide cohort study. *Surg Endosc.* Oct 2016;30(10):4469-79. doi:10.1007/s00464-016-4779-z
12. Olmi S, Millo P, Piccoli M, et al. Laparoscopic Treatment of Incisional and Ventral Hernia. *JLS.* Apr-Jun 2021;25(2)doi:10.4293/JLS.2021.00007
13. Kondrashkin AS, Khodilina IV, Yartsev PA, Dmitriev IV, Novruzbekov MS, Pinchuk AV. [Treatment of postoperative ventral hernias in recipients of solitary organs]. *Khirurgiia (Mosk).* 2018;(12):65-72. Lechenie posleoperatsionnykh ventral'nykh gryzh u retsipientov solidnykh organov. doi:10.17116/hirurgia201812165
14. Feleshtynskiy YP, Marshtupa OS, Vatamaniuk VF. Differentiated Choice of Posterior Methods of Disconnection of Anatomical Components of the Abdominal Wall in Combination with Alloplasty in Postoperative Ventral Hernias of Giant Size. *Wiad Lek.* 2023;76(3):623-628. doi:10.36740/WLek202303126
15. Hernandez-Granados P, Henriksen NA, Berrevoet F, et al. European Hernia Society guidelines on management of rectus diastasis. *Br J Surg.* Oct 23 2021;108(10):1189-1191. doi:10.1093/bjs/znab128
16. Keshvedinova AA, Smirnov AV, Stankevich VR, Sharobaro VI, Ivanov YV. [Treatment of ventral hernias in

- patients with morbid obesity]. *Khirurgiia (Mosk)*. 2023;(9):95-102. Taktika lecheniya ventral'nykh gryzh u patsientov s morbidnym ozhireniem. doi:10.17116/hirurgia202309195
17. Holden TR, Kushner BS, Hamilton JL, Han B, Holden SE. Polypharmacy is predictive of postoperative complications in older adults undergoing ventral hernia repair. *Surg Endosc*. Nov 2022;36(11):8387-8396. doi:10.1007/s00464-022-09099-9
 18. Nevo N, Goldstein AL, Yakubovsky O, et al. How-we-do-it: the repair of postoperative ventral hernias after a Mercedes abdominal incision. *Langenbecks Arch Surg*. Sep 2021;406(6):2117-2123. doi:10.1007/s00423-021-02087-y
 19. Trujillo CN, Fowler A, Al-Temimi MH, Ali A, Johna S, Tessier D. Complex Ventral Hernias: A Review of Past to Present. *Perm J*. 2018;22:17-015. doi:10.7812/TPP/17-015
 20. Azimov RH, Akhmedov TZ, Kurbanov FS, et al. [Treatment of postoperative ventral hernias with the use of mesh implants made of titanium thread]. *Khirurgiia (Mosk)*. 2020;(5):64-69. Lechenie postleoperatsionnykh ventral'nykh gryzh s ispol'zovaniem setchatykh implantov iz titanovoi niti. doi:10.17116/hirurgia202005164
 21. Wehrle CJ, Shukla P, Miller BT, et al. Incisional hernia rates following midline laparotomy in the obese patient: a retrospective review. *Hernia*. Jun 2023;27(3):557-563. doi:10.1007/s10029-022-02688-6
 22. Feng MP, Baucom RB, Broman KK, et al. Early repair of ventral incisional hernia may improve quality of life after surgery for abdominal malignancy: a prospective observational cohort study. *Hernia*. Feb 2019;23(1):81-90. doi:10.1007/s10029-018-1863-4
 23. van Silfhout L, Leenders LAM, Heisterkamp J, Ibelings MS, Ventral Hernia Group T. Recurrent incisional hernia repair: surgical outcomes in correlation with body-mass index. *Hernia*. Feb 2021;25(1):77-83. doi:10.1007/s10029-020-02320-5
 24. Popescu RC, Botea F, Dan C, Iordache IE, Ghioldis A, Leopa N. Ventral(R) ST Patch for Laparoscopic Repair of Ventral Hernias. *JLS*. Oct-Dec 2021;25(4)doi:10.4293/JLS.2021.00071
 25. Christoffersen MW, Jorgensen LN, Jensen KK. Less postoperative pain and shorter length of stay after robot-assisted retrorectus hernia repair (rRetrorectus) compared with laparoscopic intraperitoneal onlay mesh repair (IPOM) for small or medium-sized ventral hernias. *Surg Endosc*. Feb 2023;37(2):1053-1059. doi:10.1007/s00464-022-09608-w
 26. Halligan S, Parker SG, Plumb AAO, et al. Use of imaging for pre- and post-operative characterisation of ventral hernia: systematic review. *Br J Radiol*. Sep 2018;91(1089):20170954. doi:10.1259/bjr.20170954
 27. Niebuhr H, Malaibari ZO, Kockering F, et al. [Intraoperative fascial traction (IFT) for treatment of large ventral hernias : A retrospective analysis of 50 cases]. *Chirurg*. Mar 2022;93(3):292-298. Intraoperative Faszientraktion (IFT) zur Behandlung grosser ventraler Hernien : Eine retrospektive Analyse von 50 Fallen. doi:10.1007/s00104-021-01552-0
 28. Nielsen MF, de Beaux A, Tulloh B. Peritoneal Flap Hernioplasty for Reconstruction of Large Ventral Hernias: Long-Term Outcome in 251 Patients. *World J Surg*. Sep 2019;43(9):2157-2163. doi:10.1007/s00268-019-05011-0
 29. Vettoretto N, Caprioli M, Botteri E. Emergency laparoscopic treatment of complicated parastomal hernias. *Minerva Chir*. Oct 2020;75(5):313-319. doi:10.23736/S0026-4733.20.08462-X
 30. Lazarenko VA, Ivanov SV, Ivanov IS, et al. [Collagen types ratio in prediction of postoperative ventral hernias]. *Khirurgiia (Mosk)*. 2017;(6):33-36. Sootnoshenie tipov kollagena v prognozirovanii postleoperatsionnykh ventral'nykh gryzh. doi:10.17116/hirurgia2017633-36
 31. Samartsev VA, Parshakov AA, Gavrilov VA, Kuznetsova MV. [Perioperative prevention of complications in surgery of ventral hernias]. *Khirurgiia (Mosk)*. 2023;(8):40-45. Perioperatsionnaya profilaktika oslozhenii v khirurgii ventral'nykh gryzh. doi:10.17116/hirurgia202308140

32. Ngo P, Cossa JP, Gueroult S, Pelissier E. Minimally invasive bilayer suturing technique for the repair of concomitant ventral hernias and diastasis recti. *Surg Endosc.* Jul 2023;37(7):5326-5334. doi:10.1007/s00464-023-10034-9
33. Kockerling F, Reinpold W, Schug-Pass C. [Ventral hernias part 1 : Operative treatment techniques]. *Chirurg.* Jul 2021;92(7):669-680. *Bauchwandhernien Teil 1 : Operative Versorgungstechniken.* doi:10.1007/s00104-021-01382-0
34. Chen PX, Yan LN, Wang WT. Outcome of patients undergoing right lobe living donor liver transplantation with small-for-size grafts. *World J Gastroenterol.* Jan 7 2014;20(1):282-9. doi:10.3748/wjg.v20.i1.282
35. Tarasova NK, Dynkov SM, Pozdeev VN, Teterin AY, Osmanova GS. [Analysis of the causes of recurrent postoperative ventral hernias]. *Khirurgiia (Mosk).* 2019;(10):36-42. *Analiz prichin retsidiva posleoperatsionnykh ventral'nykh gryzh.* doi:10.17116/hirurgia201910136
36. Wolf LL, Ejiogor JI, Wang Y, et al. Management of Reducible Ventral Hernias: Clinical Outcomes and Cost-effectiveness of Repair at Diagnosis Versus Watchful Waiting. *Ann Surg.* Feb 2019;269(2):358-366. doi:10.1097/SLA.0000000000002507
37. Bittner R, Bingener-Casey J, Dietz U, et al. Guidelines for laparoscopic treatment of ventral and incisional abdominal wall hernias (International Endohernia Society [IEHS])—Part III. *Surg Endosc.* Feb 2014;28(2):380-404. doi:10.1007/s00464-013-3172-4
38. Bittner R, Bingener-Casey J, Dietz U, et al. Guidelines for laparoscopic treatment of ventral and incisional abdominal wall hernias (International Endohernia Society [IEHS])—part 1. *Surg Endosc.* Jan 2014;28(1):2-29. doi:10.1007/s00464-013-3170-6
39. Bittner R, Bingener-Casey J, Dietz U, et al. Guidelines for laparoscopic treatment of ventral and incisional abdominal wall hernias (International Endohernia Society [IEHS])—Part 2. *Surg Endosc.* Feb 2014;28(2):353-79. doi:10.1007/s00464-013-3171-5
40. Dasgupta P, Kathiravan B, Pai A, Niranjana R. Laparoscopic modified e-tep repair of concomitant inguinal and ventral hernias. *Hernia.* Aug 2024;28(4):1391-1395. doi:10.1007/s10029-024-03066-0
41. Parker SG, Reid TH, Boulton R, Wood C, Sanders D, Windsor A. Proposal for a national triage system for the management of ventral hernias. *Ann R Coll Surg Engl.* Feb 2018;100(2):106-110. doi:10.1308/rcsann.2017.0158
42. Halligan S, Parker SG, Plumb AA, Windsor ACJ. Imaging complex ventral hernias, their surgical repair, and their complications. *Eur Radiol.* Aug 2018;28(8):3560-3569. doi:10.1007/s00330-018-5328-z
43. Ermolov AS, Blagovestnov DA, Alekseev AK, et al. [Optimized approach to the surgical treatment of patients with large and giant postoperative ventral hernia]. *Khirurgiia (Mosk).* 2019;(9):38-43. *Khirurgicheskoe lechenie patsientov s bol'shimi i gigantskimi posleoperatsionnymi ventral'nymi gryzhami.* doi:10.17116/hirurgia201909138
44. Motz BM, Schlosser KA, Heniford BT. Chemical Components Separation: Concepts, Evidence, and Outcomes. *Plast Reconstr Surg.* Sep 2018;142(3 Suppl):58S-63S. doi:10.1097/PRS.0000000000004856
45. Christoffersen MW, Brandt E, Helgstrand F, et al. Recurrence rate after absorbable tack fixation of mesh in laparoscopic incisional hernia repair. *Br J Surg.* Apr 2015;102(5):541-7. doi:10.1002/bjs.9750
46. Kouakou KB, Anzoua KI, Traore M, et al. A Case of Rare Complication of Inguinal Parietoplasty according to Lichtenstein: Entero Cutaneous Fistula. *Case Rep Surg.* 2018;2018:3592738. doi:10.1155/2018/3592738
47. Liot E, Breguet R, Pigué V, Ris F, Volonte F, Morel P. Evaluation of port site hernias, chronic pain and recurrence rates after laparoscopic ventral hernia repair: a monocentric long-term study. *Hernia.* Dec 2017;21(6):917-923. doi:10.1007/s10029-017-1663-2
48. Maskal SM, Chang JH, Ellis RC, et al. Distressed community index as a predictor of presentation and postoperative outcomes in ven-

- tral hernia repair. *Am J Surg.* Nov 2023;226(5):580-585. doi:10.1016/j.amjsurg.2023.06.015
49. Jensen KK, Helgstrand F, Henriksen NA. Short-term Outcomes After Laparoscopic IPOM Versus Robot-assisted Retromuscular Repair of Small to Medium Ventral Hernias: A Nationwide Database Study. *Ann Surg.* Jan 1 2024;279(1):154-159. doi:10.1097/SLA.0000000000005915
50. Jensen KK. Recovery after abdominal wall reconstruction. *Dan Med J.* Mar 2017;64(3)
51. Heger P, Feisst M, Krisam J, et al. Hernia reduction following laparotomy using small stitch abdominal wall closure with and without mesh augmentation (the HULC trial): study protocol for a randomized controlled trial. *Trials.* Dec 16 2019;20(1):738. doi:10.1186/s13063-019-3921-3
52. Slonetskiy BI, Verbitskiy IV, Kotsiubenko VO. Specific Features of Diagnostic and Treatment Tactics in Patients with Crushed Abdominal Hernias Without Resection of a Hollow Organ. *Pril (Makedon Akad Nauk Umet Odd Med Nauki).* Jun 1 2024;45(2):59-66. doi:10.2478/prilozi-2024-0016
53. Wieland L, Alfarawan F, Bockhorn M, El-Sourani N. Comparison of eTEP and IPOM for ventral hernia surgery in the early postoperative period: a retrospective cohort study of a tertiary university centre. *Hernia.* Dec 2024;28(6):2195-2206. doi:10.1007/s10029-024-03125-6
54. Webster J, Alghamdi A. Use of plastic adhesive drapes during surgery for preventing surgical site infection. *Cochrane Database Syst Rev.* Apr 22 2015;2015(4):CD006353. doi:10.1002/14651858.CD006353.pub4
55. Popov AY, Petrovsky AN, Gubish AV, et al. [Results of anterior abdominal wall repair with mesh implants in patients with postoperative ventral hernia]. *Khirurgiia (Mosk).* 2020;(3):35-42. Rezul'taty vosstanovleniia perednei briushnoi stenki pri posleoperatsionnykh ventral'nykh gryzhakh s ispol'zovaniem setchatykh implantatov. doi:10.17116/hirurgia202003135
56. Bouvier A, Rat P, Drissi-Chbihi F, et al. Abdominal binders after laparotomy: review of the literature and French survey of policies. *Hernia.* Aug 2014;18(4):501-6. doi:10.1007/s10029-014-1264-2
57. Rangwani SM, Kraft CT, Schneeberger SJ, Khansa I, Janis JE. Strategies for Mesh Fixation in Abdominal Wall Reconstruction: Concepts and Techniques. *Plast Reconstr Surg.* Feb 1 2021;147(2):484-491. doi:10.1097/PRS.0000000000007584
58. Kushner BS, Han B, Otegbeye E, et al. Chronological age does not predict postoperative outcomes following transversus abdominis release (TAR). *Surg Endosc.* Jun 2022;36(6):4570-4579. doi:10.1007/s00464-021-08734-1
59. Praveenraj P, Gomes RM, Kumar S, et al. Concomitant Bariatric Surgery with Laparoscopic Intra-peritoneal Onlay Mesh Repair for Recurrent Ventral Hernias in Morbidly Obese Patients: an Evolving Standard of Care. *Obes Surg.* Jun 2016;26(6):1191-4. doi:10.1007/s11695-015-1875-4
60. Fedoseev AV, Rybachkov VV, Inyutin AS, Muravyev SY, Lebedev SN. [A new method of aponeurosis suturing after laparotomy in urgent abdominal surgery]. *Khirurgiia (Mosk).* 2020;(1):40-45. Sposob ushivaniia aponevroza posle laparotomii v urgentnoi khirurgii. doi:10.17116/hirurgia202001140
61. Stahlman S, Fan M. Incidence of inguinal hernia and repair procedures and rate of subsequent pain diagnoses, active component service members, U.S. Armed Forces, 2010-2019. *MSMR.* Sep 2020;27(9):11-16.
62. Ferrer Martinez A, Castillo Fe MJ, Alonso Garcia MT, et al. Medial incisional ventral hernia repair with Adhesix((R)) autoadhesive mesh: descriptive study. *Hernia.* Aug 2023;27(4):911-917. doi:10.1007/s10029-023-02766-3
63. Madyarov V, Kuzikeev M, Malgazhdarov M, Abzalbek Y, Zhapbarkulova G. Causes of adverse outcomes in acute intestinal obstruction. *J Complement Integr Med.* Dec 1 2023;20(4):788-796. doi:10.1515/jcim-2023-0189

STEREOTACTIC RADIOSURGERY USING GAMMA KNIFE FOR ITSENKO-CUSHING'S DISEASE

**Bakirzhan M.A.¹, Kozhemzharova M.K.¹, Kuanyshbaeva G.S.¹,
Kamitbekova Z.U.², Bazarova A.V.¹**

¹ Astana Medical University Astana, Kazakhstan

² Multidisciplinary City Hospital No. 1, Astana, Kazakhstan

DOI:10.35805/BSK2024IV006

Bakirzhan M.A.

<https://orcid.org/0009-0007-1898-9282>

Kozhemzharova M.K.

<https://orcid.org/0000-0002-7667-6889>

Kuanyshbaeva G.S.

<https://orcid.org/0000-0002-4738-0296>

Kamitbekova Z.U.

<https://orcid.org/0009-0006-3918-9703>

Bazarova A.V.

<https://orcid.org/0000-0002-6518-7174>

Annotation

Stereotactic Gamma Knife radiosurgery is becoming the treatment of choice for patients with Cushing's disease that cannot be cured by surgery. The chances of 5-year remission are 65-75%, and control of tumor growth reaches more than 90%. However, the development of hypopituitarism (15% to 36%) is a common side effect, and severe neurological complications are rare. Relapse of the disease occurs in 16-18% of patients, but the reasons for this are unclear. Stereotactic Gamma Knife radiosurgery is effective as second line therapy in surgically untreated patients. The purpose of the study is to evaluate the effectiveness of stereotactic gamma knife radiosurgery as an adjuvant treatment for Cushing's disease, and also to consider possible complications and undesirable effects associated with the use of Stereotactic Gamma Knife radiosurgery in the treatment of Cushing's disease. The authors analyzed the published results of international, multicenter and retrospective cohort studies on the use of Stereotactic Gamma Knife radiosurgery in patients with. According to published data, the average time to achieve remission after Stereotactic Gamma Knife radiosurgery in patients with Cushing's disease was 16-17 months, while remission was maintained for 10 years in 60-80% of patients. Tumor growth control was achieved in 95% of cases. Our article suggests that radiosurgery is a safe and well-tolerated procedure and can provide long-term control of hypercortisolism in the majority of patients with Cushing's disease. However, given the likelihood of relapse after initial normalization of cortisol levels and the manifestation of hypopituitarism, long-term endocrine monitoring after radiosurgery is necessary. Ultimately, radiosurgery may be considered a reasonable primary treatment option for carefully selected patients who cannot have another treatment.

received: 01.12.2024

accepted: 16.12.2024

Author for correspondence:

Bakirzhan M.A.

5th-year student in the specialty "General Medicine", JSC "Astana Medical University" 010020, Astana, Syganak str., 43. 87052192099, e-mail: madina.b29@mail.ru

Conflict of interest:

The authors declare no potential conflict of interest requiring disclosure in this article.

Keywords:

Stereotactic radiosurgery with Gamma Knife, Cushing's disease, relapses, complications.

Introduction

Itsenko-Cushing's disease (ICD) is the most common cause (80-85%) of organic hyperproduction of cortisol-endogenous hypercorticism. In 10-20% of cases, endogenous hypercorticism develops as a result of primary pathology of the adrenal glands, and in 5-10% of cases, adrenocorticotropic hormone (ACTH) is produced by a carcinoid tumor of any extrapituitary localization (e.g., medullary thyroid cancer, islet cell cancer of Langerhans, chromaffinoma, ovarian cancer, testicular cancer, prostate cancer; carcinoid of the lungs, bronchi, thymus, appendix, tumors of the gastrointestinal tract, bladder, parotid and salivary glands, etc.).¹ About 80-90%

of these adenomas are microadenomas (<1 cm), which in approximately 40% of cases are not visible on magnetic resonance imaging (MRI) of the sella turcica. Symptoms of the disease include weakness, high blood pressure, diabetes, menstrual irregularities, and mental changes. Physical signs of elevated cortisol include a moon face, buffalo hump, bruising, abdominal stretch marks, obesity, facial flushing, and hirsutism.²

With the natural course of ICD (without treatment), the five-year survival rate is 50%, but it improves significantly even with palliative treatment—bilateral adrenalectomy increases survival up to 86%. With timely diagnosis and treatment in a highly specialized center, re-

mission can be achieved in 80% of cases, and the mortality rate in patients in remission does not differ from that of the general population.¹ The first line of treatment for ICD is transsphenoidal surgery (TSS) with selective resection of the adenoma (adenomectomy), the goal of which is to completely remove the adenoma while preserving normal pituitary function. In some cases, complete removal of the adenoma is not possible. This occurs when the adenoma invades the cavernous sinus and dura mater, has significant extrasellar extension, or cannot be detected during surgery despite a thorough pituitary examination.³ TSS is still the gold standard of treatment, demonstrating remission rates of 59% to 97%. However, even with initial remission, 50% of patients experience relapses 30 years after surgery. This poses a major challenge for the long-term management of ICD.⁴

Studies from 1999 and 2017 compared microscopic and endoscopic TSS methods. The complication rates for both approaches were approximately the same. Thus, 79% of TSS complications were temporary disturbances in blood sodium levels. Less common complications included diabetes insipidus, carotid artery injury, nosebleeds, sinusitis, cerebrospinal fluid leakage, and deep vein thrombosis.⁵

The aim of this study was to evaluate the efficacy of HF radiosurgery as an adjunctive treatment for Cushing's disease and to review potential complications and adverse effects associated with the use of radiosurgery in the treatment of Cushing's disease.

There are various approaches to delivering radiation therapy (RT) to patients with Cushing's disease. Conventional fractionated beam RT has been used for many decades and can result in the remission of hypercortisolism after an indefinite period, sometimes exceeding ten years. Several types of equipment are available for stereotactic RT, such as the Gamma Knife (which uses photons from a radioactive cobalt source),⁶ the CyberKnife or other devices (which use photons generated by a linear accelerator), and proton beam therapy (which produces protons in a cyclotron or synchrotron). One of the advan-

tages of stereotactic RT over traditional RT is the ability to complete treatment in a single session ("stereotactic radiosurgery," SRS), which is considered safe when the tumor is at least 3–4 mm from the optic nerve.⁷ Single-session treatment is usually perceived by patients as more convenient since traditional RT requires multiple sessions over 5–6 weeks. An additional advantage of proton beam therapy is the ability to precisely distribute the radiation dose to a complex three-dimensional target with minimal damage to healthy tissue due to the physical properties of proton beams (Bragg effect).⁷

Regardless of the chosen RT method, the duration of hypercortisolism varies from several months to several years, requiring temporary drug therapy to control cortisol levels. Risks associated with RT include the development of anterior hypopituitarism (in 35–60% of patients 5 years after RT), optic neuropathy (1–2%), and other cranial neuropathies (2–4%). Modern radiosurgery units can use frameless techniques that allow for repeated treatment sessions. Early models of GN SRS used single-session procedures only, but recent models, such as the ICON Gamma Knife with an attached CT scanner, allow frameless techniques and multiple treatment sessions (hypofractionated therapy).⁸ The usual prescribed radiation dose for the treatment of ACTH-producing pituitary adenomas is 23 Gy and can range from 15 to 25 Gy. The close proximity of the pituitary to critical neural and vascular structures must be carefully considered. To avoid optic neuropathy, it is recommended to limit the radiation dose to ≤ 8 Gy to 12 Gy, preferably maintaining a distance of 3 mm between the superior edge of the adenoma and the optic nerve/optic chiasm. The cranial nerves of the cavernous sinus can withstand significantly higher doses of radiation, and damage to the cavernous segment of the internal carotid artery is extremely rare.⁹

Materials and methods

An online search of journal articles related to the topic was performed using PubMed databases from 2014 to 2024 by entering the key terms "gamma knife stereotactic radiosurgery", "gam-

ma knife therapy”, “pituitary adenoma”, “Cushing’s disease”. Articles were limited to English language. Cited references in articles were also searched for subject matter relevant to the topic. A systematic literature review was performed according to the Preferred Items for Systematic Reviews and Meta-Analyses (PRISMA) criteria. The initial result identified 114 articles, which were subsequently confirmed. Inclusion criteria were observational: retrospective or prospective case

series of at least 15 patients, studies of radiosurgery using the Gamma Knife technique alone. On the other hand, the following exclusion criteria were applied: incident reports, letters to the editor, comments and expert opinions were excluded; studies involving patients with different pituitary tumors, with limited information, and with a follow-up period of less than 6 months.

The method for selecting sources for the literature analysis is shown in Figure1.

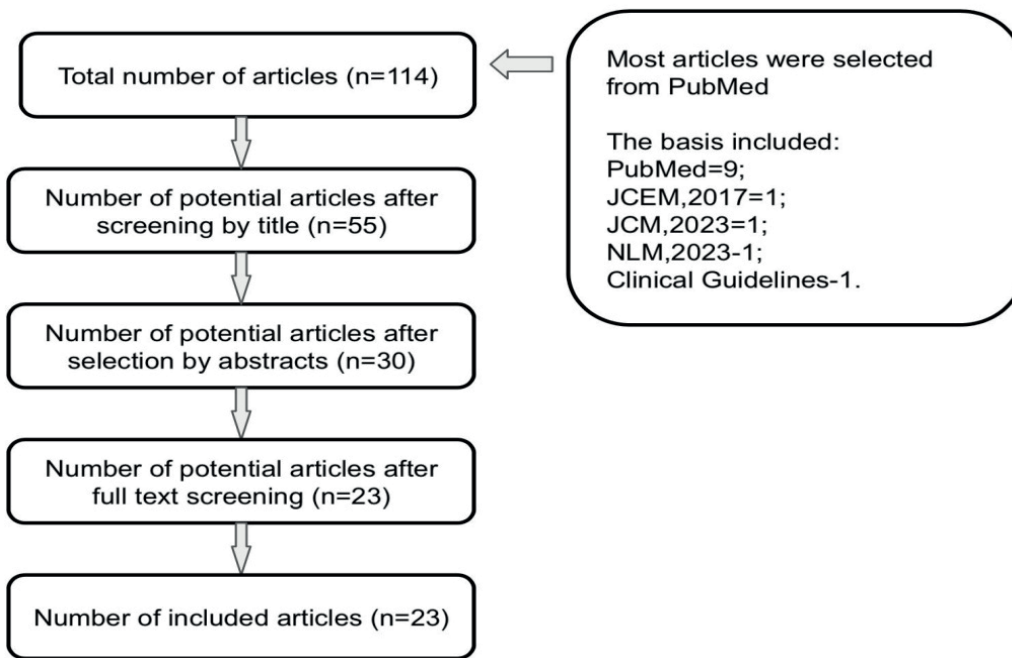


Figure 1. The method for selecting sources for the literature analysis

Results

Table 1 below lists the various inter-

national multicenter studies and retrospective cohort analyses of the articles.

Table 1.
Comparative analysis of multicenter studies on Gamma Knife Therapy for Cushing's disease

Authors of the articles	Therapy method	Patient sample	Prescribed radiation dose	Average time to achieve remission	Tumor control (%)	Biochemical remission (%)
Gao Y., et al. ¹⁰	SRS on GN	A total of 31 patients were included. The average age was 38.6 years old and 77.4% were female.	28Gy	20 months	100%	72.21%
Balossier A., et al. ¹¹	SRS on GN	A total of 26 patients were included	28.5Gy The average maximum dose received by the visual apparatus is 5.3Gy, the pituitary stalk is 13.5Gy.	36 months (median 24, range 6-98)	In 42% of patients, tumors remained stable, i.e. their size did not change.	77.6%
Mehta G.U., et al. ¹²	SRS on GN	A total of 278 patients were included, the average age was 41.4 years old and 80% of patients were female.	23.7Gy	14.5 months	In 53% of patients, tumors decreased in size. In 5% of patients, tumors increased in size.	69%
Abdali A., et al. ¹³	Stereotactic radiosurgery using CyberKnife	This is a retrospective study that included 41 patients (36 females and 5 males) who underwent BIC surgery from 2009 to 2019.	25Gy	14 months	95.12%	60.97%
Yanar E.A., et al. ¹⁴	Treatment included surgical removal of the pituitary adenoma in 69% of cases (63 of 91) and radiation therapy in 31% of cases (28 of 91).		The radiation dose during proton therapy was 40–85Gy, and during gamma knife radiosurgery it was 20–35Gy.	6 months or more	82%	After surgical treatment, remission was achieved in 71% of patients. After radiation therapy, remission was achieved in 82% of patients.

<p>Shrivastava A. et al.¹⁵</p>	<p>18 patients underwent SRS for GN after failed TLC, and in 6 patients the initial treatment was SRS for GN. The mean interval between TLC and SRS for GN was 10 months</p>	<p>24 patients with ICD were included in the study, 10 of them were male and 14 were female, the mean age was 18.32 years (range 10-21)</p>	<p>The marginal dose and maximum dose were 25 Gy (range 12.90-27.1 Gy) and 50 Gy (range 33-80 Gy), respectively.</p>	<p>At a median follow-up of 52 months after GKRS, 17 of 24 patients (70.8%) achieved endocrine remission at a median time of 12 months (range 2-42 months).</p>	<p>At a median follow-up of 46 months after GKRS, tumor control was achieved in 87.5% of patients (21/24). Fourteen patients had an initial volume reduction of >30% with a median time of 20 months.</p>	<p>At a median follow-up of 52 months after SRS for GN, 17 of 24 patients (70.8%) achieved endocrine remission. Two patients (8.3%) experienced normalization during medical treatment. Four of these 17 patients (23.5%) relapsed at a median interval of 9.5 months (range 6-16 months) after normalization. Four patients failed to achieve remission and underwent additional TLC. One of them died despite all treatments; he did not achieve remission and died 94 months after the initial SRS for GN</p>
---	--	---	--	---	--	--

Sheehan J. P. et al. ¹⁶	SRS for GN. Most patients (93.6%) had undergone at least one previous tumor resection. Interestingly, 41.5% had a history of more than 1 previous resection.	The clinical series included 512 patients [226 [44%] female and 286 [56%] male]. The mean age of patients at the time of SRS for GN was 53 years (range 16-88 years).	the mean dose was 16 Gy	After Gamma Knife treatment, the median follow-up was 36 months, mean 47.1 months.	Tumor control was achieved in 93.4% of patients.	Progression was observed in 6.6% of patients. Actuarial progression-free survival was 98% at 3 years, 95% at 5 years, and 85% at 10 years after radiosurgery. Predictors of progression: In univariate analysis, tumor volume and radiation dose were found to be significant risk factors for tumor progression. Patients with tumors larger than 5 cm ³ had an increased risk of progression, as did patients with suprasellar tumor extension. Higher radiation dose (≥ 16 Gy) was associated with a lower risk of progression
Esene I. N. et al. ¹⁷	SRS for GN	16 cases with ICD were included in the study. The mean age \pm was 34.81 \pm 10.10 years. The male to female sex ratio was 1:3.	9 Gy	The median time to hormone normalization was 23 months.	Tumor volume control was achieved in all cases, while tumor shrinkage was achieved in (10 cases) 62.5%. The median time to shrinkage was 13 months.	Normalization of hypersecretion after 2 years was achieved in 13 cases (81.3%).

<p>Gupta A. et al.¹⁸</p>	<p>SRS for GN</p>	<p>46 patients were involved, 21 with ICD and 25 with acromegaly.</p>	<p>Patients received a mean tumor dose of 25 Gy (range 12–40.0 Gy) at a mean isodose of 50%.</p>	<p>The median endocrine follow-up was 69.5 months (range 9–246 months).</p>	<p>Tumor volume noted during follow-up was stable in 18 (39%) and decreased in 28 (61%) patients. There was no significant difference ($p = 0.5$) in tumor control rates after prior use of SRS on GN in patients with ICD or acromegaly.</p>	<p>Endocrine remission was achieved in 51% of the entire cohort, with 28% remission in acromegaly and 81% remission in patients with NIC at a 5-year interval. Patients with NIC achieved remission earlier than patients with acromegaly ($p = 0.0005$). In patients after SRS for GN, pituitary adenoma remained stable (39%) or decreased (61%) in size.</p>
---	-------------------	---	--	---	--	--

In the vast majority of cases, radiotherapy was used as a second-line treatment in patients with persistent or recurrent disease after pituitary surgery. All studies examined patient outcomes, including tumor control, remission of hypercortisolism, and complications. It should be noted that the criteria used to define biochemical remission varied across studies, making comparisons difficult.

In Gao's study, 31 patients with CD received Gamma Knife SRS. Fewer patients (32%) underwent GKT after failed pituitary surgery. In the majority (67.7%), GKT was the initial treatment. Biochemical remission of CD was defined based on normal 24-hour urinary cortisol or serum cortisol ≤ 50 nmol/L after a 1 mg dexamethasone suppression test (1 mg DST). An increase in tumor volume $\geq 20\%$ was defined as tumor progression, while a decrease in tumor volume $\geq 20\%$ was defined as tumor regression. Tumor control was based on radiographic stability or regression by volumetric analysis after follow-up magnetic resonance imaging (MRI). Patients were followed for 22 months. Fourteen patients (45.1%) experienced control of hypercortisolism in the absence of pharmacologic treatment, and the 1, 2, and 3 years after GN SRS were 18.9%, 55.3%, and 72.21%, respectively. The overall complication rate was 25.8%, and the mean duration from GN SRS to hypopituitarism was 17.5 months. The new hypopituitarism rates at 1, 2, and 3 years were 7.1%, 30.3%, and 48.4%, respectively.¹⁰

In the study by Balossier E., there was a retrospective review of 26 patients from the University Hospital of Lille, France. The mean follow-up was 66 months. Eighteen (69.2%) patients had endocrine remission in the absence of any pharmacological therapy at a mean of 36 months (median 24, range 6-98). The actuarial probability of endocrine remission was 59% at 3 years and 77.6% at 7 years, which remained stable until 10 years. Tumor control was achieved in all cases. In seven patients (27%), new pituitary failure developed after SRS with GN.¹¹

In the article by Mehta U., patient selection was performed among 10 institutions, and 327 patients with NIC were

treated with a single session of SRS to GN. Forty-nine patients were excluded from the study due to insufficient data and insufficient follow-up time (less than 6 months), leaving 278 patients available for analysis. Most patients (80%) were women and had undergone previous resection (92%), while only 8% received SRS to GN as the primary treatment for NIC. SRS to GN was performed for residual tumor in 221 patients (79%) and tumor recurrence in 34 patients (12%). Sixteen patients (6%) had received fractionated radiotherapy before SRS. The mean endocrine follow-up after SRS was 5.6 years (median, 4.3 years; range, 0.5 to 20.5 years). Eighty-seven patients (31%) were taking medications to control hypercortisolism immediately before SRS. Of these patients, 85 were taking ketoconazole, 1 patient was taking mitotane, and 1 patient was taking metyrapone. In 59 patients, this medication was continued during SRS, but in 28 patients, it was stopped 2-3 weeks before SRS.^{8,12}

Control of Hypercortisolism:

- In 54 patients (19%), hypercortisolism was not controlled after SRS.
- In 31 patients (11%), hypercortisolism was controlled with medications.
- In 193 patients (69%), hypercortisolism was controlled without medications.

Efficacy Analysis: According to Kaplan-Meier analysis (a method of estimating survival or disease control over time), hypercortisolism was controlled in 59% of patients at 2 years after SRS, 77% at 5 years, and 80% at 10 years. The median time to normalization of urinary cortisol levels was 14.5 months, but this varied among patients.^{6,12}

Recurrence: After initial normalization of cortisol levels, 18% (35 of 193 patients) experienced recurrence of hypercortisolism. Recurrence-free survival after cortisol normalization was 89% at 2 years, 81% at 5 years, 70% at 10 years, and 66% at 15 years. The median time to recurrence after cortisol normalization was approximately 38-44 months.^{12,13}

Risk Factors for Recurrence: Both lower and higher doses of radiation were significant risk factors for recurrence. However, they did not show statistical significance in more complex analysis models.

Long-Term Control of Hypercortisolism: Fifteen years after treatment, 57% of patients maintained long-term control of hypercortisolism. The percentage of patients with long-term control of hypercortisolism was 48% at 2 years, 62% at 5 years, and 64% at 10 and 15 years.¹³

Efficacy of SRS in Different Groups:

- Among patients who received SRS as the primary treatment, 68% had stable control of hypercortisolism

- Among patients with normal urinary cortisol levels at the time of SRS, 74% had stable control of hypercortisolism.

- Among patients who were undergoing drug therapy at the time of SRS, 47% had long-term control of hypercortisolism.

Additional Procedures: Patients who failed to achieve biochemical control underwent additional procedures such as pituitary surgery, bilateral adrenalectomy, or repeat SRS.

Imaging Results: Imaging showed that tumors remained stable in 42% of patients, decreased in size in 53%, and increased in 5%.

In the study by Abdali A., unlike other studies in the table, a different radiation method was used, called CyberKnife. CyberKnife and Gamma Knife are two different devices used in stereotactic radiosurgery, and they differ in their operating principles, radiation types, and areas of application. Gamma Knife, unlike CyberKnife, uses gamma rays generated by radioactive cobalt-60. CyberKnife, in turn, uses x-rays generated by a linear accelerator and does not require rigid fixation, as the system automatically adjusts the direction of the beams in real-time, tracking the patient's position. CyberKnife is more versatile and is used to treat tumors in different parts of the body, including the spine, lungs, and liver.¹¹⁻¹³

The study by Abdali A. involved 41 patients (36 women and 5 men) who underwent NIC surgery from 2009 to 2019. Of the 41 cases, 34 had microadenomas and 7 had macroadenomas. These patients had recurrence or persistence of hypercortisolism after surgery. The treatment results are as follows: The remission rate in the study was 60.97% with a me-

dian follow-up of 79.03 months. The median time to biochemical remission was 14 months. Tumor growth control was achieved in 95.12%. Hypopituitarism of various axes was observed in 34.14% of patients. Secondary hypothyroidism was the most common pituitary insufficiency (34%), followed by secondary hypogonadism in 17%.¹³

In the study by E.A. Yanar, conducted from 1992 to 2020, 91 children with Itsenko-Cushing's disease (ICD) were observed. In 59% of them, pituitary adenoma (tumor) was detected, and in 41%—pituitary heterogeneity (abnormal changes without obvious tumors). Treatment included surgical removal of the pituitary adenoma in 69% of cases (63 of 91) and radiation therapy in 31% of cases (28 of 91). Remission was achieved in 71% of patients (45 of 63) after surgery and in 82% of patients (23 of 28) after radiation therapy. There was no significant difference in remission achievement depending on tumor characteristics on MRI ($P = 0.21$ after surgery and $P = 0.83$ after radiation therapy).¹⁹

Relapse of the disease was recorded in 11 patients, but the relationship between MRI characteristics and the time of its occurrence was not significant ($p = 0.055$). At the same time, the timing of relapse varied depending on the method of treatment: after surgical treatment, relapses occurred on average after 3.3 years, while after radiation therapy - after 6 years ($p = 0.022$). It was also found that patients with hypocorticism (low cortisol levels) in the early postoperative period had earlier relapses ($p = 0.04$). The study included children less than 18 years of age with confirmed central genesis of endogenous hypercorticism. The treatment was divided into two main groups: 1) transnasal adenomectomy (tumor removal), 2) radiation therapy (proton therapy or radiosurgery on a gamma knife). Until 2006, the main treatment method was proton therapy, after 2006, the main method was surgical treatment using stereotactic radiosurgery on a gamma knife if the surgery was ineffective.¹²

Proton therapy was administered to 30 patients (27 at the first stage of treatment and 3 at the second stage), and treatment on the gamma knife was

administered to 6 patients (5 at the second stage). The radiation dose for proton therapy was 40–85 Gy, and for gamma knife radiosurgery, 20–35 Gy.

Disease remission was achieved in 85% of patients (23 out of 27) who received radiation therapy. In 11 out of 18 patients who did not achieve remission after the first stage of surgical treatment, repeated removal of the pituitary adenoma led to remission in 73% of cases (8 out of 11). Six patients after ineffective first stage surgery received radiotherapy, which resulted in remission in all (100%).^{9,19}

Of the 27 patients who received radiotherapy in the first stage, it was ineffective in 4 patients. Three of them underwent repeated radiotherapy, and all achieved remission. One patient after ineffective radiotherapy underwent surgery, which also resulted in remission.^{17,18}

Patients were divided into three subgroups depending on the size of the adenoma: 1) non-visualizable adenoma, 2) microadenoma (<10 mm), 3) macroadenoma (>10 mm). Recurrence occurred in 5% of patients with non-visualizable adenoma, in 12% of patients with microadenoma, and in 23% of patients with macroadenoma. The differences in the recurrence rate among these subgroups were not statistically significant ($p=0.055$).²⁰

Analysis of the recurrence timing showed that patients who underwent only surgical treatment had recurrences in 14% of cases (8 of 55), while patients who received radiation therapy at one of the stages of treatment had recurrences in 6% of cases (2 of 35). The recurrence timing was significantly different, with a longer interval before recurrence after radiation therapy ($p=0.007$).^{10,21}

An analysis of the recurrence timing was also conducted depending on the development of hypocorticism after surgical treatment. Patients with hypocorticism in the early postoperative period had earlier recurrences ($p=0.04$).¹⁸

The findings of the study show that MRI characteristics of corticotropinoma cannot be used as a reliable predictor of therapy effectiveness in children with ICD. The choice of treatment method affects only the timing of recurrence,

but not its probability. The incidence of hypopituitarism was higher after radiation therapy than after surgery. Based on the data from all the above studies, it can be concluded that the average time to achieve remission was 16–17 months, after which remission continued for 10 years in 60–80% of patients, and tumor growth control was 95%. These data indicate that radiosurgery can provide long-term control of hypercortisolism in most patients with BIC, representing a safe and well-tolerated procedure in general.^{7,21}

Discussion

Surgical treatment is preferable in situations where rapid improvement of the patient's condition is required (e.g., in severe progressive disease or in the presence of significant complications such as osteoporosis with spontaneous fractures or malignant hypertension) and when the pituitary tumor is clearly visible on MRI. In cases of protracted disease, when the patient's condition allows a long wait until remission occurs, or when MRI shows only indirect signs of the adenoma or its size is too small for surgical intervention, radiosurgery can be chosen as the main method of treatment.^{8,16}

Most researchers note that stable remission in NIC after surgical removal of the adenoma is achieved in approximately 80–90% of cases, which significantly increases the effectiveness of treatment, especially in severe cases of the disease.^{15,18}

However, European experts studying NIC have shown that the recurrence rate after microsurgical removal of adenoma can reach 20%, and the risk of postoperative complications is 15%. Common complications of radiation therapy include post-radiation encephalopathy (5–20%) and hypopituitarism.¹⁹ Complications such as visual impairment or other cranial nerve problems after SRS for GN are rare and occur in only 3% of patients. After proton irradiation of the pituitary gland, thyroid-stimulating hormone deficiency (TSH) is often detected (35–42%), less often - ACTH (30–39%) or gonadotropin deficiency (15–29%).²² The process of decreasing the level of tropic hormones includes primary deficiency of somatotrophic hormone and gonadotropic

function, and then gradual impairment of ACTH and TSH secretion. Predicting the risk of developing hormonal deficiency after radiation is difficult, since different patients with the same radiation doses may have different results.^{3,10}

Limitations. Some of the studies included in this review are updates of previously published papers that included the same cohort of patients. To avoid duplication of data, each of these articles was carefully reviewed for new information on treatment outcomes or possible complications. Only those publications that contained the most up-to-date data with expanded information and the largest number of included patients were included in the final analysis.

Conclusions.

GN-SRS is an effective and safe treatment for PIH, reducing pituitary adenoma size and normalizing cortisol levels in most patients. GN-SRS should be considered in patients with persistent

hypercortisolism after pituitary surgery and as a first-line treatment for those who are not candidates for surgery. Further studies are important to more fully evaluate long-term outcomes and compare GN-SRS with other treatments.

Acknowledgment. The authors of the article express their gratitude to the Department of Internal Medicine with courses in Gastroenterology, Pulmonology and Endocrinology for their ongoing support and creation of an environment conducive not only to academic growth but also to the development of discipline and hard work.

Authors' Contributions. B.M., K.M., K.G., K.Zh. B.A.: contribution to the concept; B.M., K.M.: scientific design; B.M., K.M., K.G., K.Zh. B.A.: execution of the declared scientific research; K.Zh. B.A.: interpretation of the declared scientific research; K.G., K.Zh. B.A.: creation of the scientific article.

Funding. Not funded.

References

1. Losa M, Albano L, Bailo M, Barzaghi LR, Mortini P. Role of radiosurgery in the treatment of Cushing's disease. *J Neuroendocrinol.* Aug 2022;34(8):e13134. doi:10.1111/jne.13134
2. Kairys N, Anastasopoulou C, Schwell A, Haddad LM. Cushing Disease (Nursing). *StatPearls.* 2024.
3. Rubinstein G, Osswald A, Zopp S, et al. Therapeutic options after surgical failure in Cushing's disease: A critical review. *Best Pract Res Clin Endocrinol Metab.* Apr 2019;33(2):101270. doi:10.1016/j.beem.2019.04.004
4. Ironside N, Chen CJ, Lee CC, Trifiletti DM, Vance ML, Sheehan JP. Outcomes of Pituitary Radiation for Cushing's Disease. *Endocrinol Metab Clin North Am.* Jun 2018;47(2):349-365. doi:10.1016/j.ecl.2018.01.002
5. Smith TR, Hulou MM, Huang KT, et al. Complications after transsphenoidal surgery for patients with Cushing's disease and silent corticotroph adenomas. *Neurosurg Focus.* Feb 2015;38(2):E12. doi:10.3171/2014.10.FOCUS14705
6. Albano L, Losa M, Barzaghi LR, et al. Gamma Knife Radiosurgery for Pituitary Tumors: A Systematic Review and Meta-Analysis. *Cancers (Basel).* Oct 5 2021;13(19)doi:10.3390/cancers13194998
7. Gheorghiu ML, Fleseriu M. Stereotactic Radiation Therapy in Pituitary Adenomas, Is It Better Than Conventional Radiation Therapy? *Acta Endocrinol (Buchar).* Oct-Dec 2017;13(4):476-490. doi:10.4183/aeb.2017.476
8. Desai R, Rich KM. Therapeutic Role of Gamma Knife Stereotactic Radiosurgery in Neuro-Oncology. *Mo Med.* Jan-Feb 2020;117(1):33-38.
9. Minniti G, Osti MF, Niyazi M. Target delineation and optimal radiosurgical dose for pituitary tumors. *Radiat Oncol.* Oct 11 2016;11(1):135. doi:10.1186/s13014-016-0710-y
10. Gao Y, Wang M, Wu Y, et al. Gamma Knife Radiosurgery for Cushing's Disease: Evaluation of Biological Effective Dose from a Single-Center Experience. *J Clin Med.* Feb 6 2023;12(4)doi:10.3390/jcm12041288
11. Balossier A, Tuleasca C, Cor-tet-Rudelli C, et al. Gamma Knife

- surgery for recurrent or persistent Cushing disease: long-term results and evaluation of biological effective dose in a series of 26 patients. *Swiss Med Wkly.* Jun 21 2021;151:w20520. doi:10.4414/smw.2021.20520
12. Mehta GU, Ding D, Patibandla MR, et al. Stereotactic Radiosurgery for Cushing Disease: Results of an International, Multicenter Study. *J Clin Endocrinol Metab.* Nov 1 2017;102(11):4284-4291. doi:10.1210/jc.2017-01385
 13. Abdali A, Kalinin PL, Trunin YY, et al. CyberKnife for the management of Cushing's disease: our institutional experience and review of literature. *Br J Neurosurg.* Oct 2021;35(5):578-583. doi:10.1080/02688697.2021.1921107
 14. Yanar A, Zbinden R, de Melo M, Trick AJ, Kovacs R, Thiel MA. [Risk of bacterial contamination after povidone-iodine disinfection for cataract surgery]. *Klin Monbl Augenheilkd.* May 2006;223(5):357-60. Bakteriellles Kontaminationsrisiko nach Povidon-Iod-Desinfektion in der Kataraktchirurgie. doi:10.1055/s-2006-926558
 15. Shrivastava A, Mohammed N, Xu Z, et al. Outcomes After Gamma Knife Stereotactic Radiosurgery in Pediatric Patients with Cushing Disease or Acromegaly: A Multi-Institutional Study. *World Neurosurg.* May 2019;125:e1104-e1113. doi:10.1016/j.wneu.2019.01.252
 16. Sheehan JP, Starke RM, Mathieu D, et al. Gamma Knife radiosurgery for the management of nonfunctioning pituitary adenomas: a multicenter study. *J Neurosurg.* Aug 2013;119(2):446-56. doi:10.3171/2013.3.JNS12766
 17. Esene I, Tantengco OAG, Robertson FC, et al. A guide to interpreting systematic reviews and meta-analyses in neurosurgery and surgery. *Acta Neurochir (Wien).* Jun 4 2024;166(1):250. doi:10.1007/s00701-024-06133-8
 18. Gupta A, Xu Z, Kano H, et al. Up-front Gamma Knife radiosurgery for Cushing's disease and acromegaly: a multicenter, international study. *J Neurosurg.* Aug 1 2019;131(2):532-538. doi:10.3171/2018.3.JNS18110
 19. Mathieu D, Kotecha R, Sahgal A, et al. Stereotactic radiosurgery for secretory pituitary adenomas: systematic review and International Stereotactic Radiosurgery Society practice recommendations. *J Neurosurg.* Mar 1 2022;136(3):801-812. doi:10.3171/2021.2.JNS204440
 20. Deng Y, Li Y, Li X, et al. Long-term results of Gamma Knife Radiosurgery for Postsurgical residual or recurrent nonfunctioning Pituitary Adenomas. *Int J Med Sci.* 2020;17(11):1532-1540. doi:10.7150/ijms.47168
 21. Castinetti F, Brue T, Ragnarsson O. Radiotherapy as a tool for the treatment of Cushing's disease. *Eur J Endocrinol.* May 1 2019;180(5):D9-D18. doi:10.1530/EJE-19-0092
 22. Pivonello R, Fleseriu M, Newell-Price J, et al. Improvement in clinical features of hypercortisolism during osilodrostat treatment: findings from the Phase III LINC 3 trial in Cushing's disease. *J Endocrinol Invest.* Oct 2024;47(10):2437-2448. doi:10.1007/s40618-024-02359-6

CT AND MRI REFERRAL PRACTICES UNDER MANDATORY SOCIAL HEALTH INSURANCE: A SURVEY OF RADIOLOGISTS AND GPs

Baiguissova D.^{1,2}, Sadykova A.², Baimuratova M.A.¹, Ryskulova A.R.¹, Kalshabay Ye.², Mukhamejanova A.N.², Battalova G.², Kabidenov A.²

¹ Kazakhstan Medical University "KSPH", Almaty, Kazakhstan

² Syzganov National Scientific Center of Surgery, Almaty, Kazakhstan

DOI:10.35805/BSK2024IV007

Baiguissova D.

<https://orcid.org/0000-0003-4261-3537>

Sadykova A.

<https://orcid.org/0009-0003-6347-1512>

Baimuratova M.

<https://orcid.org/0000-0003-0219-7874>

Ryskulova A.

<https://orcid.org/0000-0003-4768-4799>

Kalshabay Y.

<https://orcid.org/0000-0003-0493-6685>

Mukhamejanova A.

<https://orcid.org/0000-0002-4487-1604>

Battalova G.

<https://orcid.org/0000-0003-4261-3537>

Kabidenov A.

<https://orcid.org/0000-0001-5038-2033>

Abstract

Background. Modern imaging techniques, such as computed tomography (CT) and magnetic resonance imaging (MRI), are vital for diagnosing and monitoring diseases. Despite their value, challenges include high costs, radiation risks, and limited accessibility. Effective use requires collaboration between general practitioners (GPs) and radiologists. Misguided referrals burden healthcare systems, while underuse delays diagnoses.

Objective. This study assesses GPs' awareness of CT/MRI indications, examines challenges in referrals under the mandatory social health insurance framework, and analyzes radiologists' views on unjustified referrals.

Methods. Two surveys were conducted: one among 108 radiologists in Almaty and Astana and another among 163 GPs in Almaty and the Almaty region. Questionnaires included closed and open-ended questions, and responses were analyzed to identify barriers and optimize diagnostic processes.

Results. Among radiologists, 56.5% reported more than five unjustified referrals per month, with CT being the most overused modality (80.6%). Reasons included GPs' lack of knowledge about indications (66.7%) and patient pressure (67.6%). GPs cited limited mandatory social health insurance framework quotas (29.3%) and long waiting times (19.9%) as significant barriers. Both groups emphasized the need for clear clinical guidelines, enhanced education, and better interprofessional communication.

Conclusion: Systemic improvements in radiology services are necessary. Key recommendations include developing national clinical guidelines, educating GPs on CT/MRI indications, and streamlining administrative processes. These measures will reduce unjustified imaging, improve resource use, and enhance patient care.

received: 09.12.2024

accepted: 16.12.2024

Author for correspondence:

Baiguissova D.

Head of radiology department

A.N.Syzganov National Scientific

Center of Surgery, PhD student

at Kazakhstan Medical University

"KSPH",

e-mail: dina.gallyamova.xray@gmail.com,

Conflict of interest:

The authors declare no potential conflict of interest requiring disclosure in this article.

Keywords:

radiology, CT, MRI, general practitioners, mandatory social health insurance

Introduction

Modern imaging techniques such as computed tomography (CT) and magnetic resonance imaging (MRI) play a key role in the diagnosis and monitoring of various diseases. These technologies provide highly accurate information about the condition of organs and tissues, which helps to improve the effectiveness of treatment. However, there are a number of challenges to their use, including high cost, the need for radiation risk assessment (in the case of CT), and limited availability in some regions.^{1,2}

An important aspect of the rational use of imaging modalities is the interdisciplinary collaboration between general practitioners (GPs) and radiologists. GPs are often the first decision-makers in deciding whether to prescribe CT or MRI, while radiologists provide expert judgment and interpretation of the appropriateness of these modalities. Unwarranted prescriptions may result in unnecessary burden on patients and health care systems, and underutilization may delay diagnosis.³

The aim of this work is to analyze

the awareness of GPs about the indications for CT and MRI and the problems they face in prescribing high-tech tests, as well as to assess the reasons for unjustified prescription of tests through the eyes of a radiologist, based on the results of their questionnaires. Analysis of interaction and perception of these specialists will allow identifying key barriers and suggestions for optimization of diagnostic processes.

Materials and Methods

A questionnaire survey was conducted among 108 radiologists of large medical organizations, cities of republican significance (Almaty, Astana) using Google form (online questionnaire). The questionnaire consisted of 12 questions, 11 with answer options and 1 open-ended question, 3 of them with multiple-choice answers.

By type of medical organization: 61 radiologists from city hospitals (56.5%), 18 employees of Research Institutes (16.7%), 21 physicians from private clinics (19.4%) and 8 radiologists from other types of medical enterprises (7.4%)

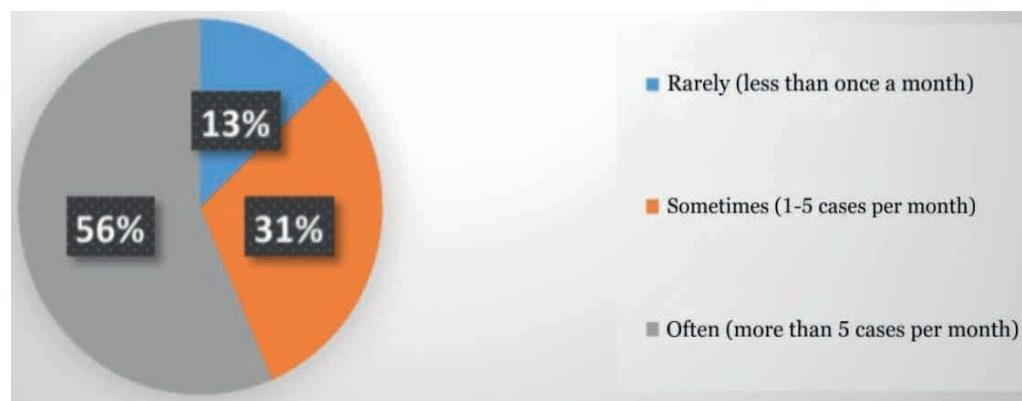
The data of the survey of 163 GPs on the topic "Assignment of CT and MRI examinations within the framework of mandatory social health insurance" were also analyzed by means of questionnaire survey in Almaty city and Almaty region. The data of questionnaire survey of 163 GPs were analyzed, 86 of which responded in paper form, 77 were surveyed online. The questionnaire consisted of 15 questions, with 11 single and 4 multiple-choice answers.

Results

Out of 108 radiologists, 35 of them had up to 5 years of experience in radiology, which is 32.4%; 36 doctors with 5 to 10 years of experience - 33.3%; 29 doctors with 11 to 20 years of experience - 26.9% and 8 doctors with more than 20 years of experience - 7.4%.

The frequency of unjustified investigations per month according to radiologists is: more than 5 cases per month - 61 (56.5%), from 1 to 5 cases - 30.6% (33) and less than 1 case - 13% (14), presented in Diagram 1.

Figure 1.
Frequency of unjustified studies per month



The most frequently unreasonably prescribed investigations are the following: CT - 87 (80.6%), MRI - 29 (26.9%), contrast-enhanced studies - 40 (37%), other (ultrasound, X-ray, mammography, etc.) - 11 (10%). More detailed data are shown in Diagram No. 2.

The categories of patients with the most frequent unjustified appointments for investigations are presented below: Patients with complaints that can be evaluated by other methods (e.g. ultrasound or radiography) - 77 (71.3%); Patients with no clear indications for investigation - 65 (60.2%); Patients insisting on investigation - 69 (63.9%), others - 2 (1.8%).

Radiologists consider the main rea-

sons for unjustified appointments to be: Lack of knowledge of doctors about CT/MRI indications - 72 (66.7%), Pressure from patients - 73 (67.6%), Pressure from administration about plan fulfillment - 37 (34.3%), Unnecessary reinsurance of doctor - 63 (58.3%), Lack of clear recommendations or protocols in mandatory social health insurance - 52 (48.1%).

Regarding the assessment of compliance of the mandatory social health insurance tarifficator list with the real costs of radiologic examinations, the following results were obtained: 5 (4.6%) believe that they fully comply, 27 (25%) partially comply, 76 (70.3%) do not comply, the real cost is higher than believed.

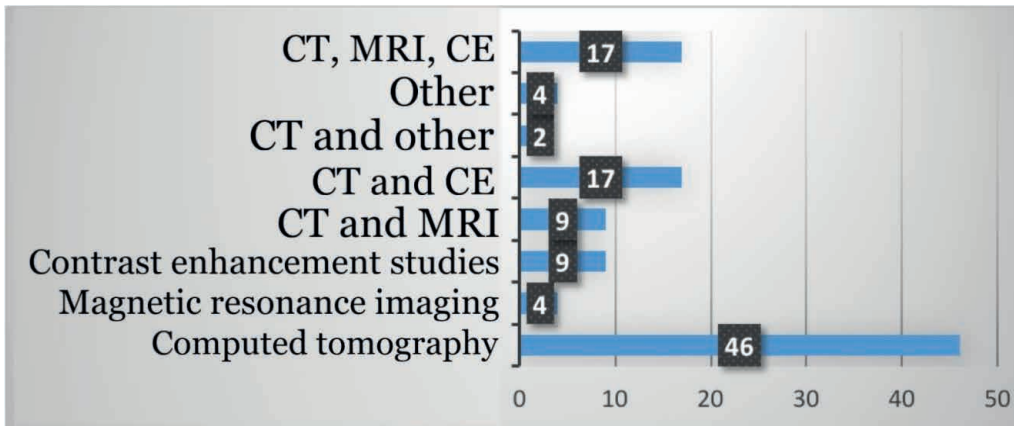


Figure 2.
Distribution of unjustified appointments by type of trials

Do doctors receive additional payments for trials within the framework of MHI, the following comments were given: yes, regularly - 12 (11.1%); yes, but rarely - 16 (14.8%); no, I do not receive - 64 (59.3%); found it difficult to answer - 16 (14.8%).

As for the suggestions to reduce unjustified appointments for investigations, the following options were received: Raising awareness of GP physicians about protocols and indications - 82 (75.9%); Introduction of mandatory coordination with radiologists before appointing investigations - 59 (54.6%); Development of clear clinical guidelines for GP physicians - 75 (69.4%); Restriction of CT/MRI appointments within the framework of MHI for some cases - 36 (33.3%).

According to the results of the questionnaire survey of GPs, the number of doctors working in the city polyclinic was 114 (69.9%), working in private organizations was 11 (6.75%), combining/other

was 38 (23.31%) out of 163.

The mean age of the physicians was 30-40 years and mean work experience was 5-10 years.

The frequency of appointments for investigations by GPs within the framework of MHI was: 70 (42.9%) physicians answered "1-5 times a month", 67(41.1%) - less than once a month and 26 (16.0%) - more than 5 times a month.

Physicians consider the following as the main difficulties in prescribing CT and MRI scans: Limited MHI quotas - 72 (29.3%); Long waiting time before the study - 49 (19.9%); The list of studies conducted under MHI is limited - 36 (14.6%); No clear indications for the study - 32 (13.0%); Long waiting time for the conclusion - 24 (9.8%);

To the question "How often do you face unjustified referrals for CT or MRI?": 68 (41.7%) physicians answered "Rarely", 44 (27.0%) - "Sometimes", 30 (18.4%) - "Often", 18 (11.0%) - "Never", and 3 (1.8%) - "Always".

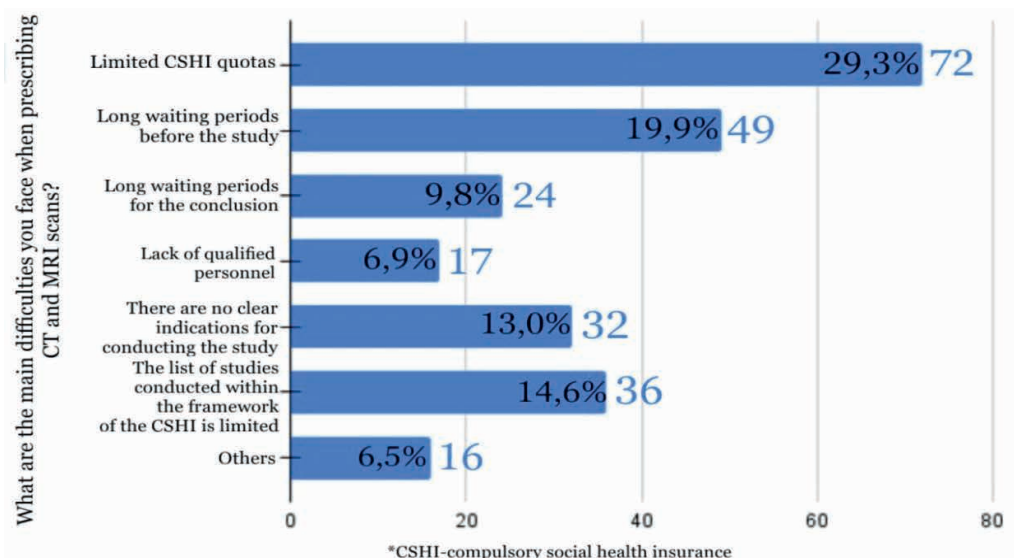


Figure 3.
Main difficulties in prescribing CT and MRI scans

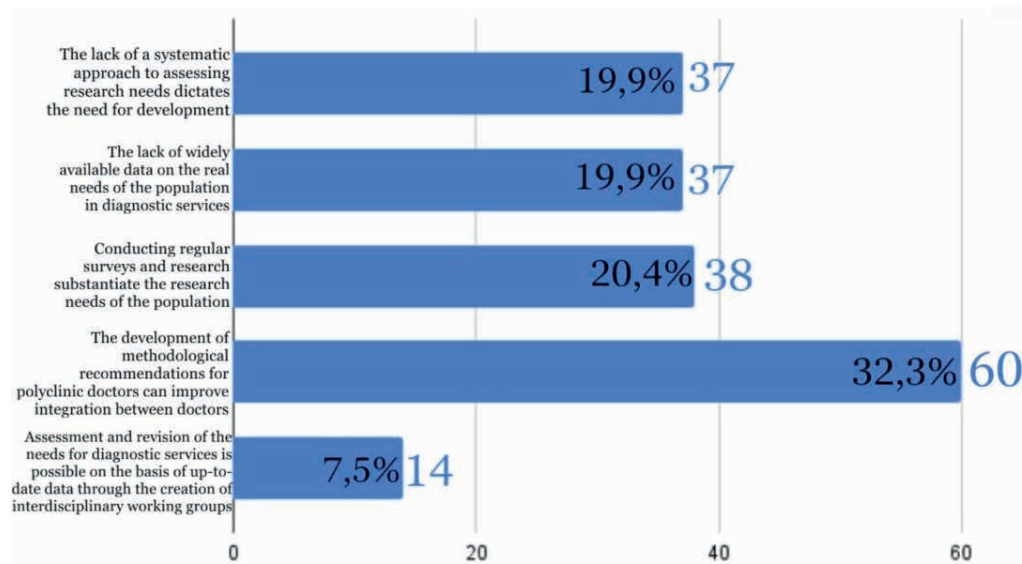
Gaps and shortcomings in radiology diagnostics according to primary care physicians are as follows: 60 (34.9%) doctors noted - Lack of standards and protocols for prescribing and performing examinations, which can lead to redundant or unnecessary examinations; Insufficient integration between different levels of medical care, which leads to inconsistencies in referrals for examinations - 30 (17.4%); Lack of qualified specialists, which makes it difficult to perform high-tech examinations - 24 (14%); There are no problems, because radiology diagnostics is not within our competence - 23 (13.4%); Don't know - noted by 35 (20.4%).

To the question "What risk factors in your opinion cause the increase in the number of CT and MRI examinations?": 61 (30%) physicians noted - It is necessary to introduce mandatory informing patients about radiation exposure and possible alternatives; 43 (21.1%) - Lack of informational activities for patients about explaining the risks and benefits of CT and MRI, 41 (20.1%) - Low level of patients' awareness about the risks and necessity of the studies; 32 (15.7%)

- Training of physicians to better explain the necessity of the studies; 27 (13.2%) - Lack of explanatory work on the part of physicians (lack of time at appointments), which may lead to excessive prescriptions.

In the question about the development of approaches to determine the need for high-tech methods of radiation diagnostics, doctors consider the following necessary: Development of methodological recommendations for doctors of polyclinics to determine the indications for referrals to CT and MRI can improve integration between doctors of different specialties - 60 (32.3%); Conducting regular surveys and studies substantiate the needs of the population in high-tech research - 38 (20.4%); Lack of data in wide access about the real needs of the population in diagnostic services - 37 (19.9%); Lack of a systematic approach to assessing the need for high-tech research in medical organizations necessitates development - 37 (19.9%); Assessment and revision of needs for diagnostic services is possible on the basis of up-to-date data through the creation of interdisciplinary working groups - 14 (7.5%).

Figure 4.
The need to develop approaches to determining the need for high-tech methods of radiology diagnostics



Discussion

The results of the study demonstrate important aspects of the current situation in the utilization of high-tech radiotherapy diagnostic techniques, including CT and MRI, and indicate key gaps and challenges faced by physicians.

The distribution of radiologists by years of experience shows that the most

significant part of the sample consists of specialists with up to 10 years of experience (65.7%). This may indicate that the majority of practicing radiologists are in the active phase of their professional activity. The small percentage of specialists with more than 20 years of experience (7.4%) indicates the need to attract experienced personnel to the

field to improve mentoring and knowledge transfer.

The data on the frequency of unjustified prescriptions is alarming, with more than half of radiologists (56.5%) reporting more than 5 such cases per month. This indicates a systemic problem that may be related to lack of physician knowledge, lack of strict protocols, or the influence of external factors such as patient and administrative pressure.

The most frequently unnecessarily prescribed diagnostic method is CT (80.6%), which emphasizes the need for attention to the rational use of this resource-intensive method associated with radiation exposure. MRI (26.9%) and contrast-enhanced studies (37%) also account for a significant share. This indicates the need for additional training of general practitioners (GPs) and the introduction of restrictions on such prescriptions in cases where they are inappropriate.

Analysis of the categories of patients with unjustified appointments highlights the main problems: a significant proportion of tests are performed in the absence of clear indications (60.2%) or in cases where the diagnosis can be established using less costly methods (71.3%). Also, patient insistence (63.9%) is an important factor emphasizing the need to work with patient expectations and inform them about diagnostic options.

Radiologists cited lack of knowledge of GP physicians (66.7%) and patient pressure (67.6%) as the main reasons for unjustified prescriptions. These data point to the need for systematic educational activities and the introduction of protocols that would allow GP physicians to act confidently, excluding redundant investigations. Pressure from the administration (34.3%) is also a significant factor emphasizing the need to revise management approaches.

The overwhelming majority of radiologists (70.3%) believe that the current tarifficator for mandatory medical social insurance does not correspond to the real costs of conducting trials. This indicates the need to revise the financial model of mandatory medical social insurance to ensure adequate compensation of costs for high-tech trials.

The majority of radiologists (59.3%) do not receive additional payments for trials under the MHI, which may reduce their motivation to participate in the development of the system. Fair remuneration for performing complex trials could be an incentive to improve the quality of services.

The results of the survey of primary care physicians show that the main group of respondents are doctors working in urban polyclinics (69.9%), which logically reflects the structure of primary health care in urban settings. About a quarter of respondents combine work in other organizations, this may indicate a high workload of primary care physicians. The average age of physicians (30-40 years) and length of service (5-10 years) indicate an active professional period, which makes their opinions particularly valuable for analyzing current problems.

The frequency of prescribing trials within the MHI varies, with 42.9% of physicians prescribing trials 1-5 times per month and 41.1% prescribing trials less than once. Only 16% of physicians prescribe trials more than 5 times a month, which may be due to quota restrictions, lack of physician awareness, or lack of clear protocols. This figure emphasizes the need to analyze the factors influencing the use of high-tech diagnostic methods.

The frequency of unjustified referrals is of concern. Although 41.7% of physicians noted that they encounter such cases rarely, 18.4% reported that it happens frequently. The main reason for unjustified referrals may be the lack of standards and protocols (34.9%), which is confirmed by the high proportion of physicians' responses to this item. Insufficient integration between levels of medical care (17.4%) also affects the compliance of referrals with clinical requirements.

Physicians noted the lack of standards and protocols (34.9%) as the main problem that leads to unnecessary tests. Insufficient integration between levels of medical care (17.4%) and lack of qualified specialists (14%) also create barriers to effective use of diagnostic methods. It is noteworthy that 20.4% of respondents found it difficult to answer

this question, which may indicate that physicians are not sufficiently informed about the organizational aspects of radial diagnostics.

Among GP physicians the key difficulties are limited MHI quotas (29.3%) and long waiting times for trials (19.9%). For radiologists, the lack of clear protocols (48.1%) and pressure from the administration (34.3%) remain the main problems. Both aspects indicate the need to optimize organizational processes and funding.

Both radiologists and GP physicians emphasize the low awareness of patients about the risks and necessity of investigations. There is also a lack of information activities for patients (21.1%) and lack of explanatory work on the part of doctors (13.2%). The introduction of mandatory informing of patients about radiation exposure and possible alternatives (30%) could significantly reduce unjustified prescriptions.

A common proposal for both groups is the development of methodological recommendations for GP physicians (75.9% among radiologists and 32.3% among GPs). The introduction of mandatory coordination with radiologists (54.6%) is also seen as an important step to improve the quality of the diagnostic process. Eliminating gaps in protocols and systematizing approaches to assessing the need for diagnostic services (19.9%) would improve interdisciplinary collaboration.

Limitations. The study relies on self-reported data from surveys, may introduce bias due subjective respons-

es. The geographic focus on Almaty and Astana the generalizability of findings to other regions or countries.

What's known? Unjustified referrals for CT and MRI are a global concern, contributing to resource overuse and unnecessary patient exposure to risks. General practitioners often lack adequate knowledge about imaging indications, which affects the appropriateness of referrals.

What's new? This study highlights the specific barriers faced by GPs and radiologists within the mandatory social health insurance framework in Kazakhstan, such as limited quotas and long waiting times. It quantifies the extent of unjustified referrals with 56,5 % of radiologists reporting frequent cases and CT being the most overused modality.

Conclusion

The results of questionnaires of radiologists and GPs demonstrate the need for systemic changes in the organization of radial diagnostics. The main directions of work include: Development of educational programs for general physicians about indications for CT and MRI; Informing patients about risks and alternative methods of diagnostics; Optimization of the quota system and organizational processes of providing high-tech methods of radiation diagnostics; Development of clinical recommendations at the republican level for doctors of all specialties; These measures will not only reduce the number of unjustified prescriptions, but also improve the availability and quality of high-tech diagnostic methods for patients.

References

1. Brenner, D. J., & Hall, E. J. (2007). Computed tomography—an increasing source of radiation exposure. *New England Journal of Medicine*, 357(22), 2277-2284.
2. Kressel, H. Y., & Van Tongerloo, A. (2019). Optimizing imaging utilization: Challenges and solutions. *Radiology*, 291(3), 499-508.
3. World Health Organization (2016). WHO guidelines on radiation protection in diagnostic and interventional radiology.
4. European Society of Radiology (ESR) (2017). ESR concept paper on value-based radiology. *Insights into Imaging*, 8(6), 447-454.
5. Mills, P., & Palmer, B. (2020). The role of interdisciplinary collaboration in reducing unnecessary diagnostic imaging. *Journal of Clinical Radiology and Imaging*, 4(2), 75-82.
6. Griffey, R. T., & Pines, J. M. (2011). Reducing the overuse of diagnostic imaging in the emergency department: An evidence-based approach.

- Academic Emergency Medicine, 18(11), 1315-1322.
7. Bohannon, L. S., & Malley, D. (2018). Educational strategies for improving referral appropriateness for advanced imaging. *Journal of Continuing Education in the Health Professions*, 38(4), 223-230.
 8. Mendiratta-Lala, M., et al. (2020). Value of evidence-based guidelines for imaging appropriateness: The ACR Appropriateness Criteria. *Journal of the American College of Radiology*, 17(7), 904-912.
 9. Fletcher, R. H., & Fletcher, S. W. (2020). *Clinical epidemiology: The essentials*. Lippincott Williams & Wilkins.
 11. Schnyder, P., et al. (2015). Communication between referring physicians and radiologists: Systematic review of barriers and solutions. *Insights into Imaging*, 6(5), 573-583.
 12. Rosenkrantz, A. B., et al. (2015). Strategies to improve appropriateness in advanced diagnostic imaging. *American Journal of Roentgenology*, 204(6), 1196-1202.
 13. Pandharipande, P. V., et al. (2016). Impact of medical imaging on patient care. *Radiology*, 279(3), 678-689.
 14. Meulepas JM, Hauptmann M, Lubin JH, Shuryak I, Brenner DJ. (2018). Is there Unmeasured Indication Bias in Radiation-Related Cancer Risk Estimates from Studies of Computed Tomography? *Radiat Res*. Feb;189(2): 128-135. doi:10.1667/RR14807.1
 15. Meyer, J. R., & Luetmer, P. H. (2017). Role of clinical decision support tools in optimizing imaging utilization. *Neuroimaging Clinics of North America*, 27(4), 515-526.
 16. Berland, L. L., et al. (2018). Appropriateness criteria in radiology: Development and application. *Radiology*, 288(3), 658-664.
 17. Harolds, J. A., et al. (2016). Clinical decision-making in radiology: Barriers and facilitators. *Radiology Leadership Institute Reports*, 8(1), 12-19.
 18. Halm BM, Franke AA, Lai JF, et al. (2015). Pilot study for the establishment of biomarkers for radiation damage after computed tomography in children. *Hawaii J Med Public Health*. Mar 2015;74 (3):112-9.
 19. Brady, A. P., et al. (2017). Radiology education for non-radiologists: Building bridges. *Insights into Imaging*, 8(2), 137-144.
 20. Jha, S., & Topol, E. J. (2016). Enhancing patient care through digital radiology. *Journal of Digital Imaging*, 29(5), 564-571.
 21. Boone, J. M., et al. (2014). Radiation dose management in CT: International trends and future directions. *Journal of Radiology Protection*, 34(3), R25-R37.

К 90-летию академика РАЕН, профессора Г. Н. Андреева



Г. Н. Андреев родился 07.01.1934 года, в селе Никольском Оренбургской области, в семье служащих. Отец – Николай Емельянович Андреев, доктор химических наук, известный партийный работник, парторг ЦК Березниковского химического комбината Мордовской АССР (теперь Пермская область). Репрессирован в 1937 году. Мать – Фаина Даниловна Концевая-Андреева, преподаватель истории и географии средней школы, парторг школы. Репрессирована в 1938 году, сослана в Казахстан, в Актюбинскую область.

Г. Н. Андреев закончил среднюю школу в 1951 году с серебряной медалью в поселке Шубар-Кудук, Актюбинской области. В связи с тем, что был сыном репрессированных родителей Андреев Г.Н. не был допущен к конкурсу для поступления в Военно-медицинскую Морскую Академию. В том же году поступил на лечебный факультет Казахского Государственного медицинского института города Алма-Аты, который закончил с отличием в 1957 году. Был рекомендован в аспирантуру, но по комсомольской путевке уехал работать в Хобдинскую районную больницу Актюбинской области, где проработал 5 лет.

В 1962 году Г. Н. Андреев поступил в клиническую ординатуру на кафедру госпитальной хирургии Алма-Атинского Государственного медицинского института, возглавляемую заслуженным деятелем науки, доктором медицинских наук, профессором М. И. Брякиным. По окончании клинической ординатуры был оставлен на кафедре аспирантом. В 1968 году защитил кандидатскую диссертацию, которая была посвящена экспериментально-клиническому изучению результатов операции Нобля, как метода лечения спаечной кишечной непроходимости. Модификация энтеропликации, предложенная Г.Н. Андреевым, заняла свое место в лечении спаечной кишечной непроходимости.

В 1968 г. прошел по конкурсу ассистентом кафедры госпитальной хирургии, отвечал за лечебную и научную работу

С 1971 года бессменно руководил научным студенческим кружком кафедры, был членом совета НИРС лечебного факультета и института.

В 1981 году на базе БСМП был организован Республиканский центр хирургии портальной гипертензии Казахстана как филиал Всесоюзного центра портальной гипертензии, где продолжались многосторонние клинические исследования различных осложнений портальной гипертензии. Руководимый Г. Н. Андреевым центр был признан лучшим в СССР академиком Б. В. Петровским.

В 1990 году во втором Московском медицинском институте имени И.М. Сеченова Г. Н. Андреевым была защищена докторская диссертация на тему «Диагностика и лечение осложнений портальной гипертензии»

С 1997 года профессор Г. Н. Андреев работал по контракту в институте медицинского образования, НовГУ, на кафедре госпитальной хирургии в городе Великий Новгород.

Профессор Г. Н. Андреев автор 524 публикаций, посвященных вопросам urgentной хирургии и портальной гипертензии, в т.ч. 24 монографии. Под его редакцией вышло 2 учебных пособия для студентов старших курсов медицинских институтов, 28 научных и учебно-методических рекомендаций, капитальное руководство по гепатологии с курсом клинической биохимии.

Под руководством профессора Г.Н. Андреева было защищено 5 докторских и 24 кандидатских диссертаций, из них 2 докторские, 12 кандидатских посвящены проблеме портальной гипертензии.

В 1998 году профессор Г. Н. Андреев избран академиком Российской Академии естественных наук, с 1996 года действительный член Ассоциации хирургов стран СНГ имени Н. И. Пирогова, Международной Ассоциации хирургов-гепатологов, международного клуба гастроэнтерологов-гепатологов. Профессор Г. Н. Андреев дважды награжден почетным знаком «Отличник здравоохранения СССР» (1961 и 1990 годы), медалью «Ветеран труда СССР» (1990 год). В 2007 году Г.Н. Андреев был объявлен: «Человеком года».

В 2009 г. профессору Г.Н. Андрееву присвоено звание «Заслуженный деятель науки РФ»

Работая в Новгородском универ-

ситете, профессор Г. Н. Андреев готовил научные кадры не только, для северо-запада России, но и для Республики Казахстан. Под его руководством защищены 5 кандидатских диссертаций преподавателями Казахского Национального медицинского университета им. С. Д. Асфендиярова. Профессор Г.Н. Андреев создал школу гепатологов РК и северо-запада России. Всю свою жизнь профессор Геннадий Николаевич посвятил делу спасения человеческих жизней, ибо ему было свойственно глубокое сострадание к пациентам, их боли, человечность и бескорыстие. Он воспитал не одно поколение своих последователей и многочисленных учеников, хирургов, как в России, так и в ближнем зарубежье, которые продолжают дело своего любимого учителя, не нарушая преемственности его дела.

Скоропостижная смерть прервала, научно-практическую деятельность академика РАЕН, «Заслуженного деятеля РФ», доктора медицинских наук, профессора Геннадия Николаевича Андреева, в 2009г. По книгам Г. Н. Андреева учатся врачи, студенты медицинских вузов РФ, республики Казахстана, создают модели портальной гипертензии в эксперименте.

Ученики проф. Г. Н. Андреева успешно выполняют трансплантации печени на уровне мировых стандартов.

**Профессор
Врач**

**А.С. Ибадильдин
Б. Аталыков**